

Study on retinol binding protein (RBP) receptor in hydatidiform mole trophoblastic cells

Andrijono¹, E Taufik², M Hartati², R Kodaria²

Abstrak

Molahidatidosa merupakan kehamilan yang abnormal yang pada pemeriksaan histopatologi ditandai dengan proliferasi sel sitotrofoblas, sinsitiotrofoblas, dan intermediate trofoblas. Vitamin A mengontrol proliferasi sel, dan penurunan kadar vitamin A menyebabkan proliferasi tidak terkontrol. Sampai saat ini, belum diketahui apakah terdapat hubungan antara defisiensi vitamin A dengan molahidatidosa. Penelitian ini bertujuan untuk membuktikan keberadaan reseptor retinol binding protein (RBP) pada sel trofoblas molahidatidosa, sehingga dapat menjelaskan hubungan vitamin A dengan molahidatidosa. Penelitian ini adalah penelitian deskriptif. Spesimen penelitian adalah blok parafin molahidatidosa tahun 2005. Pemeriksaan dilakukan dengan teknik imunohistokimia tidak langsung. Dilakukan pemeriksaan sebaran sel yang berekspresi, kekuatan ekspresi dan letak ekspresi reseptor RBP. Terdapat 21 spesimen dengan sebaran ekspresi reseptor RBP pada sel trofoblas molahidatidosa antara sedang sampai padat. Ekspresi reseptor RBP pada sel sinsitiotrofoblas lebih kuat jika dibandingkan dengan sel sitotrofoblas. Ekspresi reseptor RBP dijumpai pada membran sel dan sitoplasma. (*Med J Indones 2007; 16:146-50*)

Abstract

Hydatidiform mole is an abnormal pregnancy characterized by the proliferation of cytotrophoblastic, syncytiotrophoblastic, and intermediate trophoblastic cells in histological specimens. Vitamin A plays a role in controlling cell proliferation, and decrease in vitamin A level will cause an uncontrollable proliferation. To date, it is not known whether there is a relationship between vitamin A deficiency and hydatidiform mole. This study aimed to demonstrate the presence of retinol binding protein (RBP) receptors in the hydatidiform mole trophoblastic cells, that would provide explanation on the relationship of vitamin A and hydatidiform mole. The study was a descriptive study. The specimens of the study were paraffin blocks of hydatidiform mole made in 2005, and the examinations were performed by indirect immunohistochemistry. We examined the distribution of the cells showing expression of RBP receptor, the strength of expression, and location of the expression. As many as 21 specimens were collected, and the distributions of RBP receptor expression in hydatidiform mole trophoblastic cells ranged from moderate to dense. The expression in syncytiotrophoblastic cells was stronger than that in cytotrophoblastic cells. Furthermore, the expressions were found in the cell membranes and cytoplasm. (*Med J Indones 2007; 16:146-50*)

Keywords: cytotrophoblastic, syncytiotrophoblastic, intermediate trophoblastic cells

Hydatidiform mole is an abnormal pregnancy which, at histological examination, shows the proliferation of trophoblastic cells (cytotrophoblast, syncytiotrophoblast, intermediate trophoblast), hydrophic degeneration of chorionic villi and avascular degeneration of chorionic

villi. To date, the causal factors of hydatidiform mole remain unknown.

In hydatidiform mole, one of the interesting factors to be studied is the proliferation of trophoblastic cells. This proliferation increases because the control mechanism of the cell cycle does not function properly, and the genes inducing the cell cycle work more actively than those inhibiting the cell cycle.

In the cell, vitamin A or retinol is metabolized into retinoic acid, and the retinoic acid works to control the proliferation. The lack of retinol would result in the reduced activity in the control of proliferation, such that the proliferation occurs uncontrollably.¹⁻³

¹ Department of Obstetrics and Gynecology, Faculty of Medicine University of Indonesia/ Dr. Cipto Mangunkusumo General Hospital, Jakarta, Indonesia

² Department of Anatomic Pathology, Faculty of Medicine University of Indonesia/ Dr. Cipto Mangunkusumo General Hospital, Jakarta, Indonesia

The question that arised was whether or not there was a relationship between the proliferation of trophoblastic cells in hydatidiform mole and vitamin A deficiency.

In order to explain the possible roles of retinol in hydatidiform mole trophoblastic cells it is necessary to conduct a study to demonstrate the presence of retinol binding protein (RBP) receptors in the hydatidiform mole trophoblastic cells, that has not been reported by previous investigators.

Therefore, this study aimed to demonstrate the expression of RBP receptor in hydatidiform mole trophoblastic cells by immunohistochemistry technique.

METHODS

Samples of the study were taken from paraffin blocks of hydatidiform mole. The paraffin blookes were made in 2005. We performed histological examinations on hematoxilin eosin staining to evaluate the quality of the tissues. The evaluation were performed by an anatomic pathologist. The immunohistochemistry staining was done by indirect method, using polyclonal rabbit anti-human RBP (Dako Cytomation) as primary antibody. The secondary antibody used was biotinylated rabbit anti mouse (BRAM) linked to strept avidin-biotin and labelled with horseradish peroxydase (Dako), while the substrate used was brown-colored diaminobenzidine (DAB). The immunohistochemistry staining process was based on the guidelines for immunohistochemistry examination by the Department of Anatomic Pathology, Faculty of Medicine University of Indonesia.

The staining was performed together with external negative controls and both internal and external positive controls. The location of RBP receptor was evaluated on the basis of color identification in the parts of trophoblastic cells with a focus on cell membrane, cytoplasm, and cell nucleus.

The strength of RBP receptor expression was divided into three categories: (1) weak expression, if the color displayed was light, (2) moderate expression, if the color displayed was darker, (3) strong expression, if the color displayed was very dark.

The distribution of the expressing cells was divided into three categories: (1) sparse distribution, if the expressing cells were found sporadically, (2) moderate distribution, if the expressing cells found were not dense, (3) dense distribution, if the expressing cells were dense.

RESULTS

The number of specimens

As many as 21 specimens embedded on paraffin blocks were found in good condition, but only 5 gave good result in immunohistochemistry staining. All of the 5 slides showed the expression of RBP receptors in the trophoblastic cells, and the distribution of the RBP receptor expressing cells was moderate to dense.

The strength of RBP receptor expression in trophoblastic cells

The expression of RBP receptor was found in the syncytiotrophoblastic, cytotrophoblastic, and intermediate trophoblastic cells (see Figure 1). The color of the cytotrophoblastic cells were lighter than the syncytiotrophoblastic cells which were stained dark brown (see Figures 2 and 3). The intermediate cells were difficult to identify in the slides of this study.

The location of RBP receptor in trophoblastic cells

The location of the expression of RBP receptor was in the cell membrane and cytoplasm of hydatidiform mole trophoblastic cells (Figure 4).

Distribution of RBP receptor expressing cells

The number of RBP receptor expressing syncytiotrophoblastic cells was greater (the distribution was denser) than that of cytotrophoblastic cells in 4 slides. However, one specimen had a greater number of RBP receptor expressing cytotrophoblastic cells, and in the 5 slides, only a very small number of RBP receptor expressing intermediate trophoblastic cells was found.

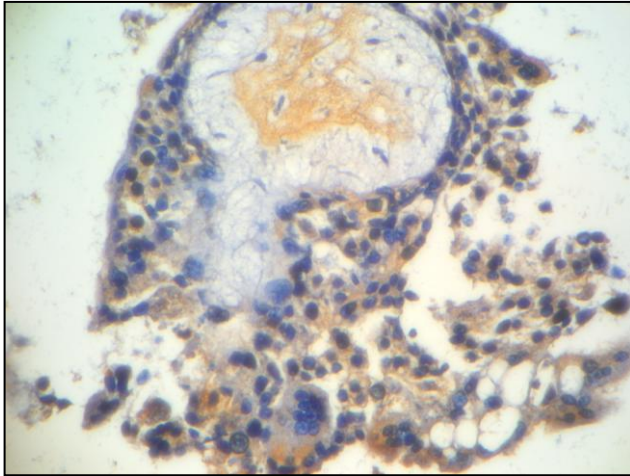


Figure 1. Expression of RBP receptor in the trophoblastic cells and connective tissues (magnification: 100 times). The expression of RBP receptor was identified as brown color. Nearly all trophoblastic cells expressed RBP receptor.

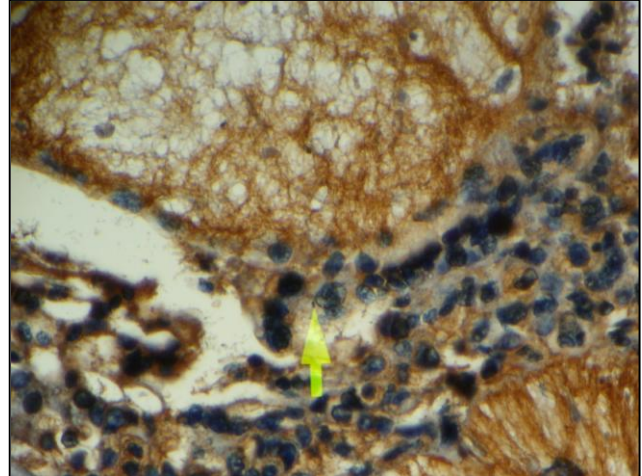


Figure 2. The expression of RBP receptor in the cytotrophoblast (magnification: 200 times)
Note: Cytoplasm of the cytotrophoblastic cells appeared light brown.

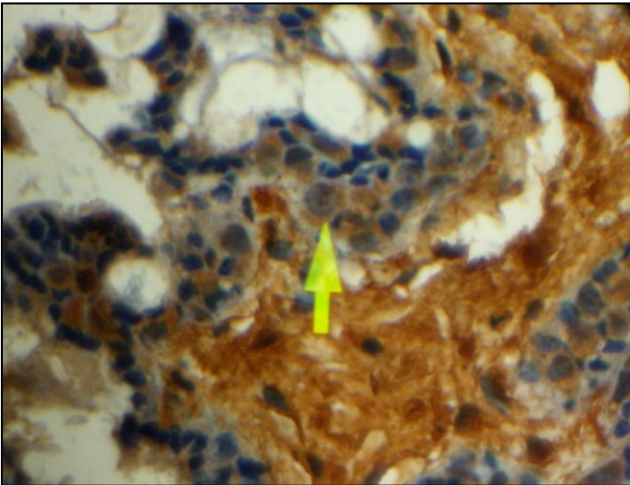


Figure 3. The expression of RBP receptor in the syncytiotrophoblastic cells (magnification: 200 times)
Note: The cytoplasm of syncytiotrophoblastic cells was dark brown.

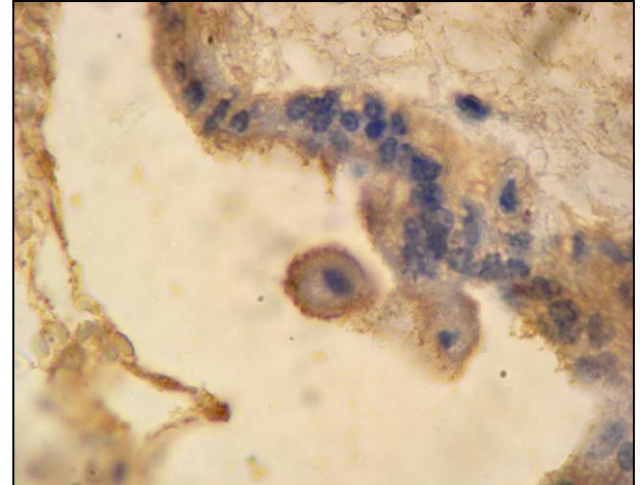


Figure 4. The RBP receptor expression in the trophoblastic cells (magnification: 400 times)
Note: RBP receptor was expressed on the cell membrane and cytoplasm of syncytiotrophoblastic cells.

DISCUSSION

The number of RBP receptor expressing trophoblastic cells and their characteristics

In this study, most slides showed greater number of RBP receptor expressing syncytiotrophoblastic compared to cytotrophoblastic cells.

This condition explained the plausible characteristics of hydatidiform mole trophoblastic cells in the samples of our study. The proliferation of cytotrophoblastic cells was continued with the differentiation of cytotrophoblastic cells into syncytiotrophoblastic cells. The change of cytotrophoblastic cells into syncytiotrophoblastic cells might occur rapidly, such that the number of cytotrophoblastic cells was fewer than that of syncytiotrophoblastic cells. This characteristic was found in a study relating it to the incidence of malignant trophoblastic disease.

Relationship of RBP receptor expression with the activity of hydatidiform mole trophoblastic cells

Hydatidiform mole trophoblastic cells have the capacity for proliferation, producing hormones and invasion, while normal trophoblastic cells only have the capacity for proliferation and producing hormones, i.e. HCG. The hormonal activity of cytotrophoblastic cells was lower than that of syncytiotrophoblastic cells. On the contrary, the proliferating activity of cytotrophoblastic cells was higher than that of syncytiotrophoblastic cells. Some of the cytotrophoblastic cells would differentiate into syncytiotrophoblastic cells, and some other would differentiate into intermediate trophoblastic cells. Therefore, the main activity of syncytiotrophoblastic cells is to produce hormones, i.e. HCG, and they have low activity of proliferation.⁴ On the other hand, the main activity of cytotrophoblastic cells is proliferation, and the main activity of intermediate trophoblastic cells is invasion, but they also have the capacity to produce hormones, i.e. HPL (human placental lactogen).^{5,6}

In this study, we found the expression of RBP receptor on the cell membrane and cytoplasm. Theoretically, the presence of receptor facilitates the entry of retinol into trophoblastic cells, as RBP bound retinol in the plasma attaches to RBP receptor at the cell membrane, and later enters the cell and binds the RBP receptor in the cytoplasm. In the cytoplasm,

retinol is metabolized into retinal, and further into retinoic acid. There are two forms of retinoic acids, i.e. all-trans retinoic acid (all trans-RA) and 9-cis retinoic acid (9-cis RA). The retinoic acids enter the nucleus, where two forms of retinoic acid receptor are present i.e. retinoic acid receptor (RAR) and retinoic X receptor (RXR). The all-trans retinoic acid binds RAR, while 9-cis retinoic acid binds either RXR or RAR (Figure 5). Retinoic acid receptor complex generates various signals, including signal of proliferation control (by inducing G₁ phase, and S phase arrest) and signal of apoptosis induction.⁷ Therefore, retinoic acid controls proliferation and apoptosis.

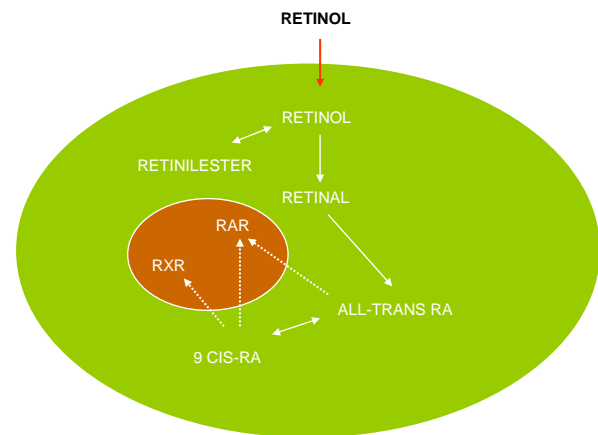


Figure 5. Metabolism of retinol in the cell
All trans RA= all trans retinoic acid, 9 cis RA= 9 cis retinoic acid, RAR= retinoic acid receptor, RXR= retinoic X receptor

We suppose that the activity of cytotrophoblastic cells or syncytiotrophoblastic cells is associated with the strength or weakness of RBP receptor expression on both trophoblastic cells. In this study, the expression of RBP receptor on the cytotrophoblastic cells was weaker than that on the syncytiotrophoblastic cells. Therefore, the number of retinol entering the cytotrophoblastic cells was supposed to be smaller than that entering the syncytiotrophoblastic cells.

Consequently, the metabolism of retinol into retinoic acid in the cytotrophoblastic cells was lower than that in the syncytiotrophoblastic cells, that was consistent with the higher proliferating activity of cytotrophoblastic cells, compared to the syncytiotrophoblastic cells.

Blood retinol level as the risk factor of hydatidiform mole

Epidemiological studies showed that the level of vitamin A or retinol in the blood of patients with hydatidiform mole was lower than that in women with normal pregnancy. We suppose that the level of vitamin A or retinol in blood is associated with the expression of retinol receptor in the hydatidiform mole trophoblastic cells.

The low level of vitamin A may cause the metabolism of retinol into retinoic acid in the cell to decrease, such that the level of retinoic acid in the cell nucleus is decrease accordingly. The reduced level of retinoic acid in the cell nucleus may decrease the control of cell proliferation, such that the trophoblastic cells undergo uncontrolled proliferation. Therefore, vitamin A deficiency might be one of the risk factors for the occurrence of hydatidiform mole, and it is likely that the administration of vitamin A may prevent the occurrence of hydatidiform mole.

In conclusion, hydatidiform mole trophoblastic cells had RBP receptors and the receptors were found on the cell membrane and cytoplasm. The expression of RBP receptor on the cytotrophoblastic cells was the

strongest followed by the expression on syncytiotrophoblastic cells, and intermediate trophoblastic cells.

REFERENCES

1. Sundaram M, Sivaprasadarao A, DeSousa MM, Findlay JBC. The transfer of retinol from serum retinol-binding protein to cellular retinol-binding protein is mediated by a membrane receptor. *J Biol Chem.* 1998;273:3336-42.
2. Smeland S, Bjerknes T, Malaba L, Eskild W, Norum KR, Blomhoff. Tissue distribution of the receptor for plasma retinol-binding protein. *Biochem J.* 1995;305:419-24.
3. Bavik CO, Bucsh C, Eriksson U. Characterization of a plasma retinol-binding protein membrane receptor expressed in the retinal pigment epithelium. *J Biol Chem.* 1992; 267(32);23035-42.
4. Shih Ie-M, Kurman RJ. Molecular basis of gestational trophoblastic diseases. *Curr Mol Med.* 2002;2:1-12.
5. Jiang B, Mendelson CR. USF1 and USF2 mediate inhibition of human trophoblast differentiation and *CYP19* gene expression by Mash-2 and hypoxia. *Mol Cellular Biol.* 2003;23(17):6117-28.
6. Aronow BJ, Richardson, Handwerker S. Microarray analysis of trophoblast differentiation: gene expression reprogramming in key gene function categories. *Physiol Genomics* 2001;6:105-16.
7. Sun S-Y, Lotan R. Retinoids and their receptors in cancer development and chemoprevention. *Critical Reviews in Oncol Hematol.* 2002;41:41-55.