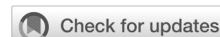

Preseptal cellulitis and cerebral venous sinus thrombosis complication in a patient with diabetes mellitus

Sylves Patrick,¹ Huwaina Abdul Satar,² Wan Hazabbah Wan Hitam²



pISSN: 0853-1773 • eISSN: 2252-8083
<https://doi.org/10.13181/mji.cr.225568>
Med J Indones. 2022;31:75–9

Received: June 5, 2021

Accepted: February 22, 2022

Authors' affiliations:

¹Department of Ophthalmology, Faculty of Medicine and Health Sciences, Universiti Malaysia Sabah, Sabah, Malaysia, ²Department of Ophthalmology, School of Medical Sciences, Universiti Sains Malaysia Health Campus, Kelantan, Malaysia

Corresponding author:

Sylves Patrick
 Department of Ophthalmology, Faculty of Medicine and Health Sciences, Universiti Malaysia Sabah, 88400, Kota Kinabalu, Sabah, Malaysia
 Tel/Fax: +60-10-5093168/+60-88-321373
 E-mail: sylves@ums.edu.my

ABSTRACT

This was a rare case of preseptal cellulitis with an unexpected complication by cerebral venous sinus thrombosis. A 73-year-old woman with poorly controlled diabetes mellitus presented with a week history of swelling and redness on the left upper eyelid and right forehead, associated with poor oral intake, lethargy, and fever. She was generally lethargic with poor verbal response. She had cellulitis of the left upper eyelid and right forehead with the left upper eyelid necrosis. Computed tomography venography of the brain revealed thrombosis of the right transverse sinus, right sigmoid sinus, and right internal jugular vein. She later developed left upper eyelid and right forehead abscesses. Incision, drainage, and wound debridement were performed. She was treated with intravenous antibiotics and anticoagulant. After 1 week of treatment, the preseptal and forehead cellulitis had resolved. However, she passed away due to aspiration pneumonia with respiratory failure on day-13 of hospitalization.

KEYWORDS cellulitis, diabetes mellitus, intracranial thrombosis, venous thrombosis

Preseptal cellulitis is an ocular infection anterior to the orbital septum. Preseptal cellulitis rarely causes intracranial complications or multiple complications. Brain abscess, meningitis, and cerebral venous sinus thrombosis (CVST) are the life-threatening intracranial complications associated with preseptal cellulitis that have been reported in four pediatric cases.^{1–4} Preseptal cellulitis co-occurring with CVST is rare. To the best of our knowledge, only one case reported preseptal cellulitis co-occurring with CVST in a 14-year-old boy due to sinusitis.⁴ Here, we report a rare case of preseptal cellulitis with an unexpected complication with CVST in an older patient with multiple comorbidities and the risks of thrombosis, as well as the outcome of delayed treatment.

CASE REPORT

A 73-year-old woman with good vision in both eyes before presentation had underlying poorly controlled diabetes mellitus (DM) and hypertension. She had a history of stroke in the previous year with residual left-sided body weakness. She initially presented with a 1-week history of the left upper eyelid and right forehead swellings, associated with redness and pain. She also had a fever, poor oral intake, and lethargy for 1 week. However, there was no history of trauma, insect bites, headache, nausea, vomiting, seizure, and nasal symptoms. She also had no recent steroids and immunosuppressive therapies before the presentation. The history taking was acquired from

the family members. Informed consent was obtained from the patient's next of kin to publish this case report.

On the examination, she had no verbal response and was lethargic, febrile, and unable to fully obey commands. Her Glasgow coma scale (GCS) was 11/15. The left upper eyelid was swollen and red with the presence of a wound with necrotic tissues near the medial canthal region with minimal pus discharge (Figure 1a). The right forehead was also swollen and red, extended to the nasal bridge (Figure 1b). The visual acuity and extraocular movement were unable to be fully assessed. However, she could see an object two feet away and had normal extraocular movement in both eyes. No relative afferent pupillary defect was detected. Intraocular pressure was normal in both eyes. Anterior segment examinations of both eyes were unremarkable, with only mild immature cataracts in both eyes. Posterior segment examinations showed

mild non-proliferative diabetic retinopathy in both eyes without optic disc swelling.

Her ear, nasal, and dental examinations were unremarkable. The tone and reflexes were normal in all four limbs. The muscle power was reduced in all upper and lower limbs, particularly in the left upper and lower limbs. The other neurological examinations were unable to be assessed. The lungs and cardiovascular systems were unremarkable.

The complete blood count showed a high white cell count (18.5×10^9 cells/l). C-reactive protein was high (250 mg/l). Her renal and liver functions were normal. The left upper eyelid wound swab, blood, pus, tissue, and urine cultures were negative for bacteria. Pus and blood cultures for fungus also showed no fungal growth. Pus for gram staining also showed no evidence of bacteria or fungal hyphae. Prothrombin time and activated partial thromboplastin time were normal. Blood sugar was high (15 mmol/l or 270 mg/dl).

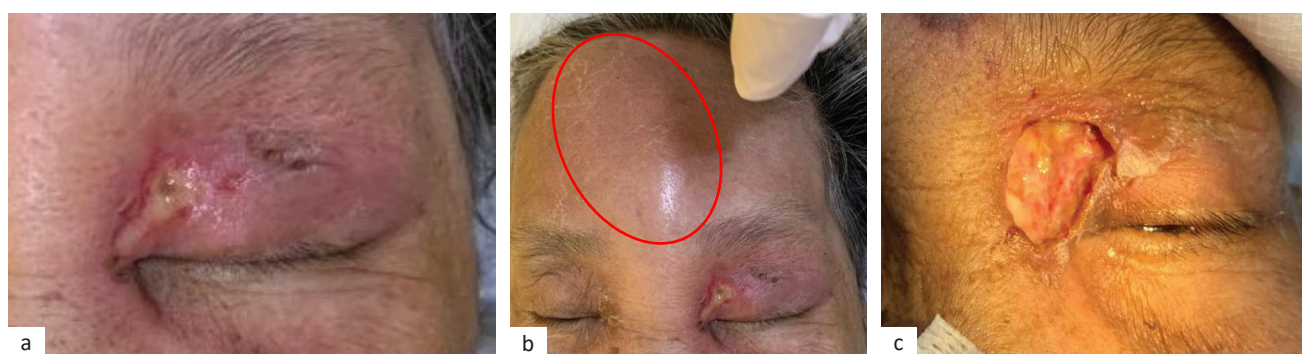


Figure 1. Eyelid and forehead infections. (a) The left upper eyelid was swollen and red with the presence of a wound with necrotic tissues near the medial canthal region with minimal pus discharge; (b) the right forehead was also swollen and red, extending to the nasal bridge (as shown in the red oval circle); (c) postoperative incision and drainage, as well as wound debridement of necrotic tissue, at the left upper eyelid near the medial canthus

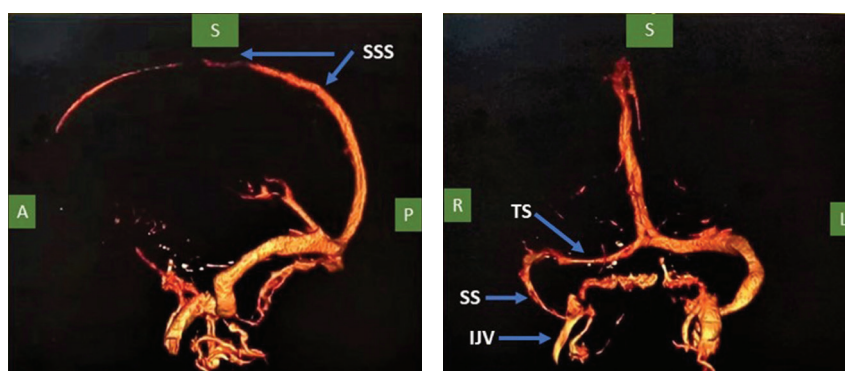


Figure 2. 3D reconstruction images of the computed tomography (CT) venography of the brain showing the filling defects at the right transverse sinus (TS), extending to the right sigmoid sinus (SS) and right internal jugular vein (IJV), suggestive of thrombosis. A=anterior; L=left; P=posterior; R=right; S=superior; SSS=superior sagittal sinus

Her contrast-enhanced computed tomography (CT) of the brain, orbit, and paranasal sinuses showed evidences of left preseptal cellulitis, right forehead cellulitis, early subcutaneous abscess formation at the forehead, and old brain infarct. An elongated filling defect was seen at the right transverse sinus extending to the right sigmoid sinus and right internal jugular vein, which was suggestive of CVST. Meanwhile, there was no evidence of cavernous sinus thrombosis, orbital cellulitis, or abscess and sinusitis. CT venography confirmed the presence of CVST at the right transverse sinus, right sigmoid sinus, and right internal jugular vein (Figure 2).

On day-3 of admission, incision, drainage, and wound debridements were performed due to abscesses formation at the right forehead and left upper eyelid (Figure 1c). Debrided tissue culture for fungus showed no fungal growth. Debrided tissue for gram staining also showed no evidence of bacteria or fungal hyphae.

She was treated for the left preseptal cellulitis with necrosis and abscess, right forehead cellulitis with abscess, sepsis, and CVST with underlying poorly controlled DM. She was co-managed by the neuromedical, ophthalmology, plastic surgery, and anesthesiology teams. She was treated with intravenous drugs, including sultamicillin 1.5 g b.i.d, metronidazole 500 mg t.i.d, and levetiracetam 500 mg b.i.d. She was given an anticoagulant, subcutaneous enoxaparin sodium 40 mg b.i.d. Ocular treatment with moxifloxacin eyedrops q.i.d was given to the left eye, and ointment chloramphenicol t.i.d was applied to the upper eyelid wound. She was given subcutaneous rapid-acting insulin for DM. She was also given antihypertensive drugs and a daily wound dressing.

Her GCS improved to 15/15, and she started on oral feeding. The forehead and upper eyelid swellings resolved with good wound healing. However, on day-8 of admission, her GCS dropped to 8/15, and she was intubated. Her non-contrast-enhanced CT of the brain revealed no evidence of intracranial bleeding and acute infarct. Her chest X-ray revealed bilateral lower zone haziness. Endotracheal secretion culture grew *Klebsiella pneumoniae*. She was treated for aspiration pneumonia and respiratory failure. Her general condition deteriorated further, and she passed away due to aspiration pneumonia with respiratory failure on day-13 of admission.

DISCUSSION

Preseptal cellulitis can be predisposed by dacryocystitis, skin lesions, sinusitis, upper respiratory infection, trauma, insect bites, and diabetes.⁵ The most common predisposing factors in children are skin lesions such as pustules, rashes, and hordeolum, whereas dacryocystitis is most common in adults.⁵ In this case report, poorly controlled DM was the known predisposing factor. It will increase the susceptibility to infection due to a significant reduction in intracellular bactericidal activity of leucocytes toward microorganisms.⁶ However, due to the presence of the necrotic wound at the left upper eyelid and the history coming solely from the family members, insect bites or trauma could not be ruled out completely.

Local and distant complications are seldom present in preseptal cellulitis compared with orbital cellulitis. Preseptal cellulitis can be complicated by eyelid abscess, eyelid necrosis, cicatricial ectropion, meningitis, brain abscess, CVST, and febrile seizure.^{1-4,7,8} The occurrence of preseptal cellulitis with intracranial complication is common in children but rare in adults. In this case report, the preseptal cellulitis was exacerbated by multiple local complications, which were eyelid necrosis and eyelid abscess due to delayed treatment. Preseptal cellulitis complicated with CVST is rare. Jones et al⁴ reported a case of preseptal cellulitis co-occurring with CVST in a 14-year-old boy. However, the preseptal cellulitis and CVST were due to sinusitis, which was not present in our case. The patient recovered well after being treated with systemic antibiotics and anticoagulant.

The common predisposing factors for CVST are thrombophilia, oral contraceptives, infection, hematological diseases, pregnancy, puerperium, and malignancy.⁹ Furthermore, diabetic hyperglycemia is reported as an additional predisposing factor.^{10,11} However, the mechanism is still not well understood. It has been postulated that the condition occurs due to dehydration and the additional hypercoagulable state that occurs in diabetic hyperglycemia.¹² The risk is higher in patients with poorly controlled DM. Dehydration is a risk factor for thrombosis due to increased blood viscosity and hypercoagulability.¹³ Systemic inflammation due to infection will lead to localized or disseminated thrombotic events by tissue factor-mediated thrombin generation, down-regulation of anticoagulant mechanisms, and

fibrinolysis inhibition.¹⁴ Poor mobility is also a risk factor for thrombosis due to stasis of the blood circulation leading to hypercoagulability.^{15,16}

Preseptal cellulitis, the upper eyelid necrosis and abscess, forehead cellulitis, poorly controlled DM, poor oral intake leading to dehydration, poor mobility, and delayed initial treatment had contributed to the formation of CVST in this case. However, thrombophilia could not be ruled out completely due to the incomplete thrombophilia screening.

The possible mechanism for septic CVST in a preseptal cellulitis patient is due to the consistent communication between the facial vein and cavernous sinus via the angular vein and superior ophthalmic vein or via the deep facial vein, pterygoid plexus, and then the inferior ophthalmic vein or emissary veins in the foramen ovale.¹⁷ The cavernous sinus also has consistent communication with the cerebral venous sinuses via the superior and inferior petrosal sinuses. This consistent communication is important in spreading infection from the periorbital or facial region to the cerebral venous sinuses leading to thrombosis.

The clinical presentation of CVST depends on the cerebral venous sinus involved, parenchymal brain injury, and effect on the intracranial pressure.¹⁸ Reduced consciousness and lethargy can be due to brain edema, intracranial hypertension, and brain infarction.¹⁹

Early intravenous antibiotics should be given for the septic CVST treatment.²⁰ Empirical antibiotics should be started before identifying the organisms based on the most common organism involved in the suspected site of origin of septic CVST. Then, it should be continued with a specific antibiotic once the organism is identified for at least 3–8 weeks.²⁰ The initial choice of antibiotics may include ceftriaxone, vancomycin, and metronidazole.²¹ It is also recommended to give heparin (low-molecular-weight heparin preferred to unfractionated heparin) in the acute phase, followed by oral anticoagulant for 3–12 months with vitamin K antagonist.²² The prevention and treatment of seizures should be started.²³ Besides, the treatment of intracranial hypertension should also be started if this complication happens.²³ However, intracranial hypertension did not develop in this case, and intravenous levetiracetam was chosen for seizure prophylaxis because of its safety profile and lack of interaction with anticoagulants.²³

Early treatment would increase the survival rate of the patient. Delayed imaging and diagnosis had led to delays in treatment with systemic antibiotics and anticoagulant. Besides, aspiration pneumonia could have been prevented if swallowing assessment had been done before starting oral feeding. Swallowing assessment is very important in patients with stroke and low GCS.²⁴

Although rare, preseptal cellulitis can be associated with CVST in poorly controlled DM. In the case of preseptal cellulitis, especially in elderly patients with late presentation, poor general condition, extensive eyelid infection, and multiple risks of thrombosis, intracranial complications should always be suspected. A high index of suspicion and early referral to the tertiary center are both warranted because early diagnosis and treatment will improve the survival rate.

Conflict of Interest

The authors affirm no conflict of interest in this study.

Acknowledgment

None.

Funding Sources

None.

REFERENCES

1. Spires JR, Smith RJ. Bacterial infections of the orbital and periorbital soft-tissues in children. *Laryngoscope*. 1986;96(7):763–7.
2. Smith TF, O'Day D, Wright PF. Clinical implications of preseptal (periorbital) cellulitis in childhood. *Pediatrics*. 1978;62(6):1006–9.
3. Zellers TM, Donowitz LG. Brain abscess and ethmoid sinusitis presenting as periorbital cellulitis in a two-month-old infant. *Pediatr Infect Dis J*. 1987;6(2):213–5.
4. Jones H, Trindade A, Jaber MC, Lyons M. Periorbital cellulitis, subgaleal abscess and superior sagittal sinus thrombosis: a rare combination of complications arising from unilateral frontal sinusitis. *J Laryngol Otol*. 2012;126(12):1281–3.
5. Liu IT, Kao SC, Wang AG, Tsai CC, Liang CK, Hsu WM. Preseptal and orbital cellulitis: a 10-year review of hospitalized patients. *J Chin Med Assoc*. 2006;69(9):415–22.
6. Rayfield EJ, Ault MJ, Keusch GT, Brothers MJ, Nechemias C, Smith H. Infection and diabetes: the case for glucose control. *Am J Med*. 1982;72(3):439–50.
7. Rao VA, Hans R, Mehra AK. Pre-septal cellulitis—varied clinical presentations. *Indian J Ophthalmol*. 1996;44(4):225–7.
8. Aldemir-Kocabaş B, Karbuz A, Özdemir H, Çiftçi E, İnce E. Periorbital and orbital cellulitis: from presentation to outcome. *J Pediatr Inf*. 2014;8(4):148–52.
9. Ferro JM, Canhão P, Stam J, Boussier MG, Barinagarrementeria F; ISCVT Investigators. Prognosis of cerebral vein and dural sinus thrombosis: results of the international study on cerebral vein and dural sinus thrombosis (ISCVT). *Stroke*. 2004;35(3):664–70.
10. Sasiadek MJ, Sosnowska-Pacuszko D, Zielinska M, Turek T. Cerebral venous thrombosis as a first presentation of diabetes. *Pediatr Neurol*. 2006;35(2):135–8.
11. Bialo SR, Agrawal S, Boney CM, Quintos JB. Rare complications of

- pediatric diabetic ketoacidosis. *World J Diabetes*. 2015;6(1):167–74.
12. Saadatnia M, Fatehi F, Basiri K, Mousavi SA, Mehr GK. Cerebral venous sinus thrombosis risk factors. *Int J Stroke*. 2009;4(2):111–23.
 13. Ott EO, Lechner H, Aranibar A. High blood viscosity syndrome in cerebral infarction. *Stroke*. 1974;5(3):330–3.
 14. Levi M, van der Poll T, Schultz M. New insights into pathways that determine the link between infection and thrombosis. *Neth J Med*. 2012;70(3):114–20.
 15. Weill-Engerer S, Meaume S, Lahlou A, Piette F, Saint-Jean O, Sachet A, et al. Risk factors for deep vein thrombosis in inpatients aged 65 and older: a case-control multicenter study. *J Am Geriatr Soc*. 2004;52(8):1299–304.
 16. Galili O, Mannheim D, Rapaport S, Karmeli R. A novel intermittent mechanical compression device for stasis prevention in the lower limbs during limited mobility situations. *Thromb Res*. 2007;121(1):37–41.
 17. Zhang J, Stringer MD. Ophthalmic and facial veins are not valveless. *Clin Exp Ophthalmol*. 2010;38(5):502–10.
 18. Ulivi L, Squitieri M, Cohen H, Cowley P, Werring DJ. Cerebral venous thrombosis: a practical guide. *Pract Neurol*. 2020;20(5):356–67.
 19. Capecchi M, Abbattista M, Martinelli I. Cerebral venous sinus thrombosis. *J Thromb Haemost*. 2018;16(10):1918–31.
 20. Khatri IA, Wasay M. Septic cerebral venous sinus thrombosis. *J Neurol Sci*. 2016;362:221–7.
 21. Kojan S, Al-Jumah M. Infection related cerebral venous thrombosis. *J Pak Med Assoc*. 2006;56(11):494–7.
 22. Ferro JM, Bousser MG, Canhão P, Coutinho JM, Crassard I, Dentali F, et al. European Stroke Organization guideline for the diagnosis and treatment of cerebral venous thrombosis - endorsed by the European Academy of Neurology. *Eur J Neurol*. 2017;24(10):1203–13.
 23. Ferro JM, Canhão P, de Sousa DA. Cerebral venous thrombosis. *Presse Med*. 2016;45(12 PT 2):e429–50.
 24. González-Fernández M, Ottenstein L, Atanelov L, Christian AB. Dysphagia after stroke: an overview. *Curr Phys Med Rehabil Rep*. 2013;1(3):187–96.