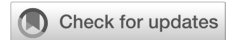

Commonly misdiagnosed round pneumonia in a child: a case report

Khai Quang Tran¹, Nghia Quang Bui¹, Tho Kieu Anh Pham², Tri Duc Nguyen³, Quan Minh Pham¹, Nhu Thi Huynh Tran¹, Ly Cong Tran¹, Nam Hoang Do¹, Phuong Minh Nguyen¹



pISSN: 0853-1773 • eISSN: 2252-8083
<https://doi.org/10.13181/mji.cr.237117>
Med J Indones. 2023;32:246–8

Received: August 03, 2023

Accepted: November 10, 2023

Published online: December 27, 2023

Authors' affiliations:

¹Department of Pediatrics, Faculty of Medicine, Can Tho University of Medicine and Pharmacy, Can Tho City, Vietnam,

²Department of Physiology, Faculty of Medicine, Can Tho University of Medicine and Pharmacy, Can Tho City, Vietnam,

³Can Tho Children's Hospital, Can Tho City, Vietnam

Corresponding author:

Phuong Minh Nguyen

Department of Pediatrics, Faculty of Medicine, Can Tho University of Medicine and Pharmacy, Nguyen Van Cu Street No. 179, An Khanh Ward, Ninh Kieu District, Can Tho City 90000, Vietnam

Tel/Fax: +84-914946198

E-mail: nmphuong@ctump.edu.vn

ABSTRACT

Round pneumonia, a specific radiological finding in children, is often caused by *Streptococcus pneumoniae*; but it is easily misdiagnosed with some other diseases, causing many difficulties for clinicians. We described a case report of round pneumonia in a 9-year-old boy, with chest pain, following fever, productive cough, left-sided pulmonary consolidation syndrome, tachypnea, no chest indrawing, and a round homogenous lesion about 4 cm in diameter with a clear border in the left upper lobe position on chest X-ray. He was initially misdiagnosed as a lung tumor. He was correctly diagnosed with round pneumonia prior to pneumonectomy and was successfully treated with antibiotics. Therefore, it is important to carefully analyze round pneumonia cases that are often misdiagnosed, resulting in poor therapy.

KEYWORDS pneumonia, *Streptococcus*, vancomycin

Round pneumonia is a radiographic finding of a pulmonary consolidation that is common in children and rare in adults.¹ Round pneumonia in children is caused by the defective development of connective tissue (Kohn's pore and Lambert's canal), which limits the spread of infection, resulting in round pneumonia.¹ *Streptococcus pneumoniae* is the most common causative bacterial agent of round pneumonia, requiring antibiotic treatment.² Although primary lung carcinomas in children, such as bronchogenic cysts, neuroblastomas, and pleural fibromas, are extremely rare, older children with round pneumonia may be misdiagnosed with lung carcinoma.³ This report presented a 9-year-old patient with round pneumonia that was initially misdiagnosed as a lung tumor. He was correctly diagnosed with round pneumonia before

pneumonectomy and was successfully treated with antibiotics.

CASE REPORT

A previously healthy 9-year-old boy was transferred to the hospital with chest pain and a 3-day history of fever and productive cough. He experienced a dull pain in his left chest that spread to his back. He had left-sided pulmonary consolidation syndrome, tachypnea (31 breaths per minute), no chest indrawing, a temperature of 38.5°C, and a regular heartbeat (102 beats per minute). His weight and height were 23 kg and 120 cm, respectively. He had lost 2 kg in the previous 2 months. His grandfather had tuberculosis (TB) 5 years prior to his presentation and was

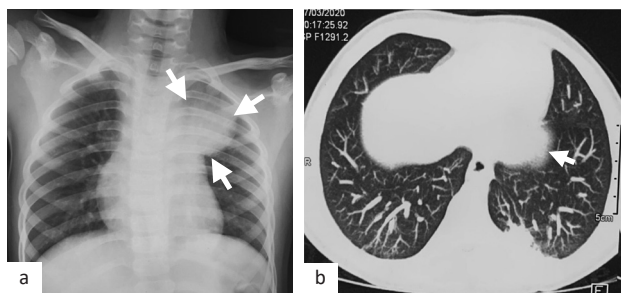


Figure 1. Lesion on CXR and chest non-contrast CT. (a) Lesion on CXR showing a well-demarcated round opacity in the left upper lung field (arrows); (b) chest non-contrast CT showing a mass of 39 × 35 mm in the left lung apex and pleural-based opacity with smooth margins in the left lung apex with normal pulmonary vasculature coursing through the mass (arrow). CT=computed tomography; CXR=chest X-ray

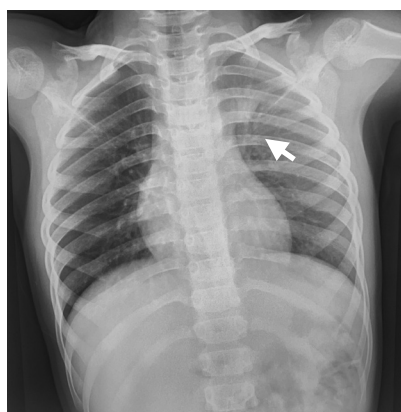


Figure 2. Opacity on the chest X-ray (CXR) disappeared on the 5th day after vancomycin treatment

successfully cured, though his cough relapsed. Upon admission, he was diagnosed with severe pneumonia and treated with intravenous ceftriaxone (150 mg/kg/day, divided into three doses) and tobramycin (5 mg/kg/day, once daily).

Chest X-ray (CXR) revealed a round homogenous lesion approximately 4 cm in diameter with a clear border in the left upper lobe (Figure 1a). Chest non-contrast computed tomography (CT) revealed a round mass measuring 39 × 35 mm in the right lung apex containing 4 mm air bubbles and a scattered consolidation area in the left upper lobe (Figure 1b).

The patient had a white blood cell count of 16.9 g/l, neutrophil count of 1.1 g/l, hemoglobin level of 11.2 g/dl, and C-reactive protein level of 94.7 mg/l. The electrolyte and glucose levels, as well as renal and liver function markers, were within normal limits. The sputum acid-fast Bacillus test was negative. Nasotracheal aspiration samples were collected

and transported to the Laboratory of Nam Khoa Biotek Company, International Research of Gene and Immunology Institute, Ho Chi Minh City, Vietnam, a laboratory that meets the International Organization for Standardization 9001:2015 and 13485:2017 and World Health Organization-Good Manufacturing Practice with Technical Report Series 908 (Annex 4) standards for real-time polymerase chain reaction (PCR), culture, and antimicrobial susceptibility testing (AST).

The patient was diagnosed with malignancy based on the CXR and CT findings, his age, and his history of weight loss. He was referred to a large pediatric hospital in Ho Chi Minh City, a central city in South Vietnam, for lung resection. However, the real-time PCR result confirmed the presence of *S. pneumoniae*, exceeding 10⁷ copies/ml. Therefore, he was transitioned from ceftriaxone/tobramycin therapy to vancomycin (60 mg/kg/day, divided into three doses daily) for 14 days. Vancomycin was utilized as an alternative to ceftriaxone even in the absence of culture and AST results due to the high prevalence of resistance to pneumococcal ceftriaxone; 3 days later, the culture results isolated *S. pneumoniae* that was resistant to ceftriaxone and sensitive to vancomycin. His clinical condition improved; he reported no chest pain, and the lungs were well-ventilated with no rales. The opacity on the initial CXR disappeared after 3 days of treatment with vancomycin (Figure 2). He did not take any additional antibiotics when discharged from the hospital.

DISCUSSION

Round pneumonia, also known as spherical pneumonia, is a radiological finding that primarily affects children. Young infants are more likely to develop round pneumonia due to their underdeveloped pores of Kohn and Lambert's channels, which may result in the centrifugal spread of fluid or bacteria.^{1,4,5} Round pneumonia typically affects children under 5 years of age and rarely occurs in children older than 8 years of age, as the lateral airways are usually well-developed by that age.^{6,7} The upper lobe of the right lung is most commonly affected; round pneumonia occurs in the upper lobe of the right lung 8 times more often than in the left upper lobe and twice as often as in the right middle or lower lobes.^{4,8} The angle of the left bronchus may cause this distribution on the median plane, as it is sharper than the angle of the

right bronchus. The sharper angle may act as a barrier to aspiration.⁹ However, the current patient was older than the typical age of patients with round pneumonia, and the lesion was in the left upper lobe. Therefore, round pneumonia should be considered even when the presentation is atypical. Obtaining a lateral CXR may have avoided a misdiagnosis in this patient.

Several features can help confirm round pneumonia as the first clinical stage of the disease includes symptoms of acute respiratory infection such as fever, cough, dyspnea, chest pain, and pulmonary consolidation syndrome. The most prominent findings are an opacity on CXR, leukocytosis, and a positive clinical radiographic response to a course of antibiotics. This is one of the most important features distinguishing round pneumonia from pulmonary neoplasms.^{5,10} Round pneumonia may appear as a halo sign on chest non-contrast CT.⁵ However, the halo sign may also be seen in fungal infections, lung abscesses, pulmonary TB, and lung malformations.⁷ Therefore, a non-contrast chest CT scan cannot definitively conclude whether a lesion is a tumor or another pathology. A CT scan has a high sensitivity but poor specificity; false-negative results occur in 15–30% of cases.¹¹ Several previous studies have suggested using contrast-enhanced CT instead of non-contrast CT to help differentiate tumors from infection.^{12,13} The use of contrast-enhanced CT may have avoided a misdiagnosis in this patient.

This report highlighted the importance of real-time PCR testing for identifying pathogens and supporting diagnoses. With its high sensitivity and quick response time, real-time PCR is useful for developing targeted treatments and preventing potentially fatal mistakes. Strict procedures were used to collect sputum samples from the tracheal aspirate in this patient, limiting cross-contamination during manipulation. The presence of <10 squamous epithelial cells and >25 polymorphonuclear cells per low-power field (100× magnification) indicated a high-quality specimen. *S. pneumoniae* is the most common etiological agent of pediatric pneumonia.² A recent study reported that *Mycoplasma pneumoniae* accounted for 69.7% of lobar pneumonia in children.¹⁴ Real-time PCR, culture, and AST can be used to identify causative agents and their susceptibilities.

In conclusion, this report presented an unusual case of a child with pneumonia caused by infection

with *S. pneumoniae*. Round pneumonia is sometimes difficult to distinguish from lung neoplasms. The combination of radiographic lesions, including contrast-enhanced CT and real-time PCR, significantly increases the accuracy of an early diagnosis.

Conflict of Interest

The authors affirm no conflict of interest in this study.

Acknowledgment

The authors would like to thank Can Tho University of Medicine and Pharmacy, Can Tho's Children Hospital, Can Tho City; Hanoi Medical University, Hanoi; and International Research of Gene and Immunology Institute, Ho Chi Minh City. We are grateful to the patient's family for consenting to our collection of their child's information.

Funding Sources

None.

REFERENCES

- Restrepo R, Palani R, Matapathi UM, Wu YY. Imaging of round pneumonia and mimics in children. *Pediatr Radiol*. 2010;40(12):1931–40.
- Ceyhan M, Ozsurekci Y, Aykac K, Hacibedel B, Ozbilgili E. Economic burden of pneumococcal infections in children under 5 years of age. *Hum Vaccin Immunother*. 2018;14(1):106–10. Erratum in: *Hum Vaccin Immunother*. 2021;17(7):2350.
- Gupta S, Goyal P, Rosinski A. A disappearing lung mass: round pneumonia. *Am J Med*. 2019;132(8):e656–7.
- Kim YW, Donnelly LF. Round pneumonia: imaging findings in a large series of children. *Pediatr Radiol*. 2007;37(12):1235–40.
- Ma J, Zhang C, Dang K, Liao Y, Feng X, Zhou P. Spherical pneumonia caused by *Ralstonia mannitolilytica*: a case report and literature review. *BMC Pulm Med*. 2023;23(1):20.
- AlOmran HI. Unilateral double round pneumonia in a child: a case report and literature review. *Radiol Case Rep*. 2021;16(11):3266–9.
- Liu YL, Wu PS, Tsai LP, Tsai WH. Pediatric round pneumonia. *Pediatr Neonatol*. 2014;55(6):491–4.
- Antón E. A frequent error in etiology of round pneumonia. *Chest*. 2004;125(4):1592–3.
- Cunha BA, Gran A, Simon J. Round pneumonia in a 50-year-old man. *Respir Care*. 2013;58(7):e80–2.
- Camargo JJ, Camargo SM, Machuca TN, Perin FA. Round pneumonia: a rare condition mimicking bronchogenic carcinoma. Case report and review of the literature. *Sao Paulo Med J*. 2008;126(4):236–8.
- MacMahon H, Austin JH, Gamsu G, Herold CJ, Jett JR, Naidich DP, et al. Guidelines for management of small pulmonary nodules detected on CT scans: a statement from the Fleischner Society. *Radiology*. 2005;237(2):395–400.
- Claessens YE, Berthier F, Baqué-Juston M, Perrin C, Faraggi M, Keita-Perse O, et al. Early chest CT-scan in emergency patients affected by community-acquired pneumonia is associated with improved diagnosis consistency. *Eur J Emerg Med*. 2022;29(6):417–20.
- Upchurch CP, Grijalva CG, Wunderink RG, Williams DJ, Waterer GW, Anderson EJ, et al. Community-acquired pneumonia visualized on ct scans but not chest radiographs: pathogens, severity, and clinical outcomes. *Chest*. 2018;153(3):601–10.
- Tran KQ, Pham VH, Nguyen PM, Tran HD, Li HQ, La VG, et al. Lobar pneumonia and bacterial pathogens in Vietnamese children. *Curr Pediatr Res*. 2020;24(7):247–53.