

## Diagnosis of Malaria by the Rapid Manual Test

Lisawati Susanto, Wita Pribadi, Hendri Astuty

### Abstrak

Diagnosis penyakit malaria ditegakkan dengan menemukan parasit dalam darah penderita. Hingga saat ini diagnosis malaria dilakukan dengan cara konvensional dengan membuat sediaan darah tebal atau tipis yang dipulas dengan pewarnaan Giemsa dan diperiksa dengan mikroskop cahaya. Dalam penelitian ini dikemukakan suatu cara baru untuk mendiagnosis malaria falsiparum, yaitu dengan "Rapid Manual Test" ("RM test"). Cara ini lebih mudah dilakukan karena tidak memerlukan pulasan warna dan pemeriksaan mikroskop. Tes ini dapat mendeteksi antigen *P.falciparum* terlarut yang berasal dari stadium trofozoit, yaitu histidine-rich protein-II (HRP-II). RM tes ini merupakan suatu "dipstick test" yang mengandung antibodi monoklonal terhadap HRP- II. Pada penelitian ini dilakukan uji coba "RM tes" ini yang dilakukan pada pengunjung Rumah Sakit International Timber Corporation Indonesia (ITCI), Kenangan, Balikpapan, Kalimantan Timur yang merupakan daerah endemik malaria. Tujuan penelitian ini ialah untuk mengetahui sensitivitas dan spesifisitas tes tersebut terhadap infeksi *P.falciparum* dan membandingkannya dengan metode diagnostik yang konvensional. Berdasarkan 117 sediaan darah yang diperiksa, 33,3% sediaan menunjukkan positif malaria falsiparum dan 53,0% sediaan negatif, baik dengan "RM test" maupun dengan cara konvensional, sedangkan sisanya 13,7% sediaan menunjukkan hasil yang berbeda, yaitu 93,8% sediaan positif pada "RM test", tetapi negatif dengan cara konvensional dan 6,2% sediaan negatif pada "RM test" tetapi positif dengan cara konvensional. Ternyata sensitivitas pada "RM test" adalah 97,5% dan spesifisitasnya 80,5% dibandingkan dengan cara konvensional. Gejala klinis pada 60 penderita yang diperiksa yang terbanyak adalah sakit kepala (42,9%) disusul dengan menggigil (42,6%), demam di atas 37,5°C (37,5%), mual atau muntah (48,8%) dan "RM test" positif 44,2% pada salah satu gejala klinis atau lebih. Penderita dengan splenomegali sebanyak 50,0% dan dengan konjungtiva pucat 45,5%. Sebagai kesimpulan dapat dikatakan bahwa "RM test" cukup sensitif sehingga dapat digunakan untuk menggantikan cara konvensional dalam menegakkan diagnosis penyakit malaria falsiparum secara cepat dan tidak memerlukan mikroskop. Cara ini dapat digunakan di rumah sakit perifer yang tidak mempunyai fasilitas tersebut dan tidak memerlukan tenaga mikroskopis khusus untuk malaria yang memang sangat kurang.

### Abstract

The diagnosis of malaria is based on the finding of malaria parasites in blood. Until now the diagnosis is carried out by means of the conventional method using Giemsa stained of a blood smear (thin or thick) and then examined by ordinary light microscope. In this study a Rapid Manual Test (RM test) for diagnosing malaria was introduced. The test was simpler than the conventional method and did not need staining as well as microscope. The test could detect soluble *Plasmodium falciparum* antigen of the trophozoite stage which consisted mainly of histidine-rich-protein-II (HRP-II). This test is a "dipstick test" which contains monoclonal antibody against HRP-II. In this study blood samples were collected from patients who were treated at the International Timber Corporation Indonesia (ITCI) Hospital at Kenangan, Balikpapan, East Kalimantan, an endemic area for malaria. The aim of this study was to know the sensitivity and specificity of the RM test in detecting *P.falciparum* infection and comparing to the conventional diagnostic method. Based on 117 blood smears examined, 33.3% were positive for malaria *falciparum* whereas 53.0% were negative by both methods. However, 13.7% blood smears showed different results: 93.8% were positive with the RM test but were negative with the conventional method, whereas 6.2% were negative with the RM test but positive with the conventional method. By statistical analysis it was shown that the sensitivity and specificity of the RM test were 97.5% and 80.5% respectively. The major clinical symptoms of the 60 patients examined were headache (42.9%) followed by chills (42.6%), fever above 37.5°C (37.5%), nausea or vomiting (48.8%) and the RM test positive rate was 44.2%. Fifty percent of the patients showed splenomegaly whereas 45.5% showed anemic conjunctivae. It was concluded that the RM test could replace the conventional method. It did not need a microscope and was quite sensitive for diagnosing malaria *falciparum*. Furthermore it could be applied in small peripheral hospitals where microscopes and malaria microscopist are not available.

**Keywords :** Conventional method, *plasmodium falciparum*, histidine-rich protein-II (HRP-II), dipstick test, monoclonal antibody

## INTRODUCTION

Until now malaria is still a public health problem in some countries including Indonesia. The mortality and morbidity caused by malaria is still high, particularly in infants and children underfives i.e 6 % and 11 %, respectively.<sup>1</sup> Hence early diagnosis is required to reduce the mortality and morbidity rates. Usually the diagnosis of malaria is carried out by means of the conventional method, using Giemsa stained of a blood smear and then examined under the ordinary light microscope as introduced by Ross<sup>2</sup> in 1903. However, this method needs an experienced microscopist and the examination itself is time-consuming (about one hour). To solve this problem Wardlaw and Levine<sup>3</sup> in 1983 introduced the Quantitative Buffy Coat technique (QBC technique) for diagnosing malaria. This method is based on staining of DNA and RNA of the parasite with acridine-orange; the nucleus will show green fluorescence and the cytoplasm will appear orange under the ultra-violet light. This method is more simple and rapid than the conventional method and anyone can master the technique in (do it accurately) less than one day.<sup>4</sup> The sensitivity of the QBC technique has been proved by some investigators.<sup>4,5</sup> Nevertheless, the QBC technique is not practical to be used under field conditions because it needs electrical power for a centrifuge and an ultraviolet (UV) fluorescence microscope. In 1993, Taylor and Voller<sup>6</sup> introduced an **Enzyme-linked immunosorbent assay (ELISA)** for detecting *Plasmodium falciparum* antigen. This assay was quite sensitive but it was time-consuming also and it needed many laboratory facilities. A new method, the **Rapid Manual test (RM test)** was introduced by Shiff et al.<sup>10</sup> in 1993. This test was more rapid and easy to perform and it did not need specific laboratory equipments such as the centrifuge and microscope so that this test was more practical to be used in the field.<sup>12,13</sup> The Rapid Manual test which was introduced by Becton Dickinson Company was aimed to detect *P.falciparum* antigen of the trophozoite stage which consisted mainly of histidine-rich-protein-II (HRP-II) or PfHRP-II. This test is a dipstick test which used a monoclonal antibody against HRP-II. The aim of this study was to compare the sensitivity and specificity of the Rapid Manual test against the conventional method for diagnosing *P.falciparum* infection.

## MATERIALS AND METHODS

### Methodology

In this study, the single blind method was used ; one investigator carried out the RM test while the other one performed the conventional method separately. Blood

samples were collected from patients with fever, chills, headache and anemic conjunctivae who visited the ITCI Hospital at Kenangan, Balikpapan, East Kalimantan. The samples were examined with the RM test and stained with Giemsa for conventional blood smear examination.

### Materials

The test sticks ( 7 cm long and 3/4 cm wide ) were made of nitrocellulose fibre consisting of 2 parts : part A which contained monoclonal antibody against histidine-rich-protein-II (HRP-II) and part B which contained a desiccant (Figure 1).

The test stick holder was made of cardboard with circled wells on it (Figure 2).

### Methods

#### a. The Rapid Manual test method

Exactly 50 ul blood was drawn with a micro-hematocrit tube directly from a finger puncture, was poured into a dispensing tube which contained 3 drops of lysing reagent and then mixed until it became homogenous by tapping the tube with the index finger. Subsequently, one drop of lysed blood was dropped onto one circle of the test stick holder, then part A of the test stick was placed on the circle until all blood was absorbed. One drop of detector reagent was added to the same circle and after it was completely absorbed, 2 drops of washing reagent were added. The results could be read at part A of the test stick. Positive results were shown by a pink line, that appeared on the test stick, i.e the blood sample tested contained *P.falciparum* antigen which reacted with the monoclonal antibody. A pink dot could also be seen as an indicator that the test was conducted properly, hence a negative test result showed only a pink dot. The test could not be interpreted if the pink dot did not appear and subsequently the test should be repeated.<sup>8</sup> (Figure 3)

#### b. The conventional method

For this method, thick and thin blood smear were prepared. Each blood sample was then stained with 8% Giemsa solution (pH 7.2). For a thick blood smear, the blood sample was stained for 20 minutes, whereas for a thin blood smear, the blood sample was initially fixed with methylalcohol for a few seconds, and was then stained for 30 minutes. Subsequently, clean water was poured onto the surface of the stained films for 10 - 15 seconds and the films were then dried. The slides were examined under an ordinary light microscope using

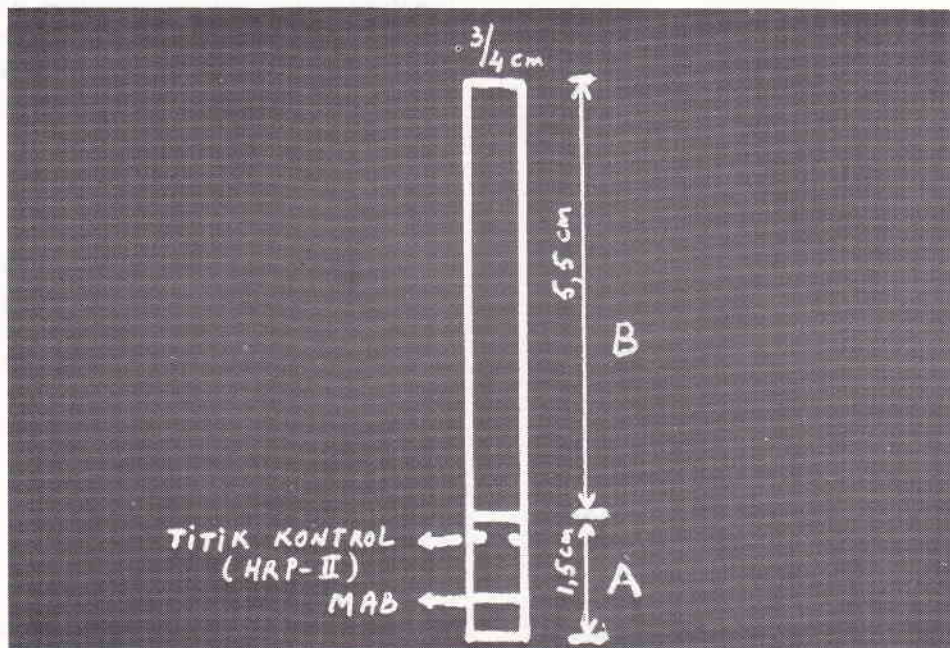


Figure 1.




Figure 2.




Figure 3.

Test sticks show positive (left), negative (middle) and not be interpreted (right) reactions.

immersion oil. The result was negative when malaria parasites were not found in the blood smear after examining 200 fields, under the light microscope (5x100). In positive blood smears, the nucleus of the parasite appeared red and the cytoplasm violet-blue while the pigment was brown-black.<sup>9</sup>

**RESULTS**

Based on 117 blood samples collected (113 adults aged 15-43 years and only 4 children aged 2-10 years), 39 samples (33.3%) were positive for *P.falciparum* whereas 62 samples (53.0%) were negative by both methods. However, 13.7% samples showed different results. Statistical analysis showed that the sensitivity and specificity of the RM test were 73.3% and 82.5% respectively; the positive predictive value was 81.2% and the negative predictive value was 74.6% (Table 1). Out of the 33 samples with *P.falciparum* positive by the conventional method, 32 showed positive results with the RM test. 5 out of 20 samples with *P.vivax* infection showed positive results with the RM test, and all of the 7 samples with mixed infection (*P.falciparum* and *P.vivax*) showed positive results by the RM test (Table 2).

The major clinical symptoms of the 60 patients examined were shown in Table 3.

Table 1. Comparison of results of the Rapid Manual test and the conventional method on 117 patients with *P.falciparum* infection from ITCI Hospital, Kenangan, Balikpapan, East Kalimantan.

Rapid Manual test	Conventional method		Total
	positive	negative	
positive	44	10	54
negative	16	47	63
<b>Total</b>	<b>60</b>	<b>57</b>	<b>117</b>

Sensitivity = 44/60 x 100% = 73.3%

Specificity = 47/57 x 100% = 82.5%

Positive Predictive Value = 44/54 x 100% = 81.2%

Negative Predictive Value = 47/63 x 100% = 74.6%

Table 2. Comparison of positive results of conventional method and Rapid Manual test according to species.

Species	Conventional method	Rapid Manual Test	
	positive	positive	negative
<i>P. falciparum</i>	33	32	1
<i>P. vivax</i>	20	5	15
Mixed infection ( <i>P. falciparum</i> + <i>P. vivax</i> )	7	7	0

Table 3. Results of both test according to symptoms and sign on 60 patients on ITCI Hospital, Kenangan, Balikpapan, East Kalimantan.

Characteristic	Total	Conventional method positive	Rapid Manual test positive
<b>Symptoms :</b>			
headache	56	23.2% (13/56)	42.9% (24/56)
chills	47	23.4% (11/47)	42.6% (20/47)
fever above 37.5°C	24	25.0% ( 6/24)	37.5% ( 9/24)
nausea or vomiting	41	31.7% (13/41)	48.8% (20/41)
<b>Signs :</b>			
splenomegaly	20	25.0% ( 5/20)	50.0% (12/20)
anemic conjunctivae	11	18.2% ( 2/11)	45.5% ( 5/11)

## DISCUSSION

In 1993, Taylor and Voller<sup>6</sup> introduced an ELISA test to detect *P.falciparum* antigen. This assay was quite sensitive, however it was time-consuming and required laboratory support facilities. In this study, a new method, the Rapid Manual test was used. Compared to the ELISA test, the RM test has certain advantages; it does not require special equipments and the results could be obtained more rapidly. The results of the RM test differed from the conventional method. Based on 117 samples examined, only 33.3% samples were positive by both methods (Table 1), whereas 17.5% samples which were negative with the conventional method were positive with the RM test. It might be possible that the number of the parasites was too small (submicroscopic level) so that only the RM test could detect. According to Shiff et al.<sup>10,12</sup> PfHRP-II antigen persisted longer in the blood than the parasite itself; the antigen can still be detected until 2 weeks. In this study, samples were collected from patients with clinical symptoms (acute phase) and PfHRP-II antigen could be found in large amounts, that was during schizont rupture. However, not all malaria infections are accompanied by specific clinical symptoms like fever, chills and headache. The results showed only 9 (37.5%) out of the patients with fever who had a positive RM test. A possible explanation was that probably the patients had been living in an endemic malaria area and were infected continuously so they became semi-immune and asymptomatic with no fever on physical examination, although they had a history of fever or of taking analgetic-antipyretic drugs. By statistical analysis it was shown that the sensitivity and specificity of the RM test were 73.3% and 82.5%, which was different from the results of Shiff et al.<sup>10</sup> who found that the sensitivity and specificity were

88.9% and 87.5% respectively. In mixed infection (*P.falciparum* and *P.vivax*) both tests gave almost equal results. On the contrary in infection with *P.vivax* as a single species the RM test should give a negative result, but 5 of 20 *P.vivax* slides were positive with the RM test, which could be due to the presence of mixed infection with *P.falciparum*; not detected by the conventional method because of the low parasitemia (Table 2). To detect parasites in the blood by the conventional method, the number of counts should be minimally 50 parasites per  $\mu\text{l}$  of blood, whereas according to Beadle et al.<sup>11</sup> an inexperienced microscopist often had difficulties in detecting parasites if the count was less than 60 parasites per  $\mu\text{l}$  of blood. According to Shiff et al.<sup>10</sup> a positive result of the RM test could be reached if the parasite count was about 40 parasites per  $\mu\text{l}$  blood; whereas Beadle et al.<sup>11</sup> claimed that the test was 96.5%-100% sensitive if the parasite count was more than 60 parasites per  $\mu\text{l}$  blood, 70%-81% sensitive for 11-60 parasites per  $\mu\text{l}$  blood and 11%-67% sensitive for 10 parasites or less per  $\mu\text{l}$  blood. Until now the conventional method is assumed as a reliable gold standard for detecting malaria parasites. In this study the conventional method was conducted by an experienced microscopist.

## CONCLUSION

The Rapid Manual test is a new diagnostic method for detecting *P.falciparum* antigen. As a dipstick test this method is very simple and could be performed by anyone. The results can be obtained within approximately 10 minutes and it does not need a microscope. Therefore it is applicable in primary health centers and peripheral hospitals. The RM test is quite sensitive and specific, and severe malaria can be diagnosed quickly so that treatment could be given immediately.

In Indonesia, *P.falciparum* and *P.vivax* are the most prevalent species, hence a combined RM test for both *P.falciparum* and *P.vivax* in one test strip should be developed and species specific diagnosis could be made so that proper treatment could be given instantly.

## Acknowledgements

We thank the manager of PT International Timber Corporation Indonesia for allowing us to use the hospital facilities. Also to Dr. Tekky Jokom, Director of PT ITCI Hospital and his staff for their assistance in performing this study, we would like to extend our gratitude. The RM test kits were provided by Becton Dickinson Company, Jakarta, Indonesia.

## REFERENCES

1. World Health Organization. Weekly Epidemiological record. Geneva, 1991.
2. Pornsilapatip P, Namsiripongpun V, Wilde H, Hanvanich M, Chutivongse S. Detection of plasmodia in acridine orange stained capillary tubes ( The QBC System ). Southeast Asian J Trop Med Pub Hlth 1990; 21 : 3 - 15.
3. Wardlaw SC, Levine RA. Quantitative buffy coat analysis : a new laboratory tool functioning as a screening complete blood cell count. JAMA 1983; 249 : 617 - 20.
4. Rickman LS, Long GW, Oberst R *et al.* Rapid diagnosis of malaria by acridine orange staining of centrifuged parasites. Lancet 1989; 68 -71.
5. Parzy D, Raphenon B, Martet G, *et al.* Quantitative buffy coat test ( QBC test) monofluo kit falciparum. Comparative value in the rapid diagnosis of malaria. Medicine Tropicale 1990; 50 : 97 - 1.
6. Taylor DW, Voller A. The development and validation of a simple antigen detection ELISA for *Plasmodium falciparum* malaria. Trans R Soc Trop Med Hyg, 1993; 87 : 29 - 31.
7. Parra ME, Evans CB, Taylor DW. Identification of *Plasmodium falciparum* histidine-rich-protein-2 in the plasma of humans with malaria. J Clin Microbiol 1991; 29 : 1629-34.
8. Rapid test for *P.falciparum* malaria. Becton Dickinson and Company. Jakarta, 1992
9. World Health Organization. Manual for processing and examination of blood slides in malaria eradication programmes. Geneva, 1961.
10. Shiff CJ, Premji Z and Minjas J. The rapid manual ParaSight<sup>R</sup>- F test. A new diagnostic tool for *Plasmodium falciparum* infection. Trans R Soc Trop Med Hyg 1993; 87 : 646 - 8.
11. Beadle C, Long GW, Weiss WR, McElroy PD, Maret SM, Oloo AJ, Hoffman SL. Diagnosis of malaria by detection of *Plasmodium falciparum* HRP-2 antigen with a rapid dipstick antigen- capture assay. Lancet 1994; 343 : 564 - 8.
12. Shiff CJ, Minjas J, Premji Z. The ParaSight<sup>R</sup>-F test: a simple rapid manual dipstick test to detect *Plasmodium falciparum* infection. Parasitology Today 1994; 10(12) : 494 - 5.
13. Premji Z, Minjas J, Shiff CJ. Laboratory diagnosis of malaria by village health workers using the rapid manual Parasight<sup>TM</sup>-F test. Trans R Soc Trop Med Hyg, 1994; 88 : 418.