

# Tracing the Neural Connections between the Subfornical Organ and the Supraoptic and Paraventricular Nuclei

## Using Neuroanatomical-tract tracing and Immunoperoxidase Methods in Albino Rats

Daryanto

### Abstrak

Penelitian ini bertujuan untuk memastikan hubungan anatomik saraf antara organum subfornicale dengan nucleus supraopticus dan nucleus paraventricularis hypothalami, dengan menggunakan metode pelacakan neuroanatomi yang menggunakan 4', 6-diamidino-2-phenylindol dihydrochloride (DAPI) dan salah satu metode imunoperoxidase yang menggunakan kit "Labeled StreptAvidin- Biotin" (LSAB) dan antibodi kelinci terhadap neurofislin manusia sebagai antibodi primer. Pada penelitian ini digunakan 7 ekor tikus putih dewasa galur Wistar untuk pelacakan neuroanatomi dan 15 ekor tikus putih dewasa galur Lembaga Makanan Rakyat, Jakarta (LMR) untuk pengkajian imunoperoxidase. Hasil penelitian menunjukkan bahwa secara anatomik organum subfornicale dihubungkan dengan nucleus supraopticus dan nucleus paraventricularis hypothalami.

### Abstract

The objective of this investigation is to ascertain the anatomical connections between the subfornical organ and the supraoptic and paraventricular nuclei of the hypothalamus by utilizing a neuroanatomical-tract tracing method using a single tracer 4', 6-diamidino-2-phenylindol dihydrochloride (DAPI) and one of the immunoperoxidase methods, using Labeled StreptAvidin- Biotin (LSAB) kit and Rabbit anti Human neurophysin as a primary antibody. The neuroanatomical-tract tracing study used 7 adult albino rat of the Lembaga Makanan Rakyat, Jakarta (LMR) strain. The results revealed that the subfornical organ was anatomically connected with the supraoptic and paraventricular nuclei of the hypothalamus.

**Keywords :** Subfornical organ, supraoptic nucleus, paraventricular nucleus, neural connections, neuroanatomical, tract tracing method, immunoperoxidase method.

### INTRODUCTION

The subfornical organ is one of the circumventricular organs (Hofer, 1958, cit. Weindl, 1973)<sup>1</sup> located in the roof of the third cerebral ventricle and attached to the ventral surface of the hippocampal commissure<sup>2,3</sup> (see Figure 1 and 2).

The subfornical organ has been a curiosity mostly to embryologists and comparative anatomists. The subfornical organ has been identified in at least 131 vertebrate species.<sup>3</sup> Its topography is consistent among animals. It is a midline tubercle at the dorsal aspect of the third ventricle near the interventricular foramina of Monro. It is only about 1 mm<sup>2</sup> in total tissue area, and appears to be uniform in size among species<sup>3,4</sup> (Figure 2).

The subfornical organ is embryologically derived from the telencephalic ependyma at the point where the tela choroidea and lamina terminalis merge.<sup>2</sup>

The subfornical organ has attracted considerable attention because of its unusual characteristics and its location within the cerebral ventricle space. It is a small structure possessing distinct morphological features that set apart from other neuronal nuclear systems,<sup>3</sup> and contains neuron, glial cells and a dense plexus of fenestrated capillaries<sup>2,3</sup> (Figure 2).

Morphologically it is highly vascular,<sup>3</sup> and lacks a blood-brain-barrier.<sup>5</sup>

Miselis and colleagues has identified a substantial system of efferent fibers emanating from the SFO.<sup>6</sup> Recent anatomical<sup>7,8</sup> and physiological studies<sup>9</sup> indi-

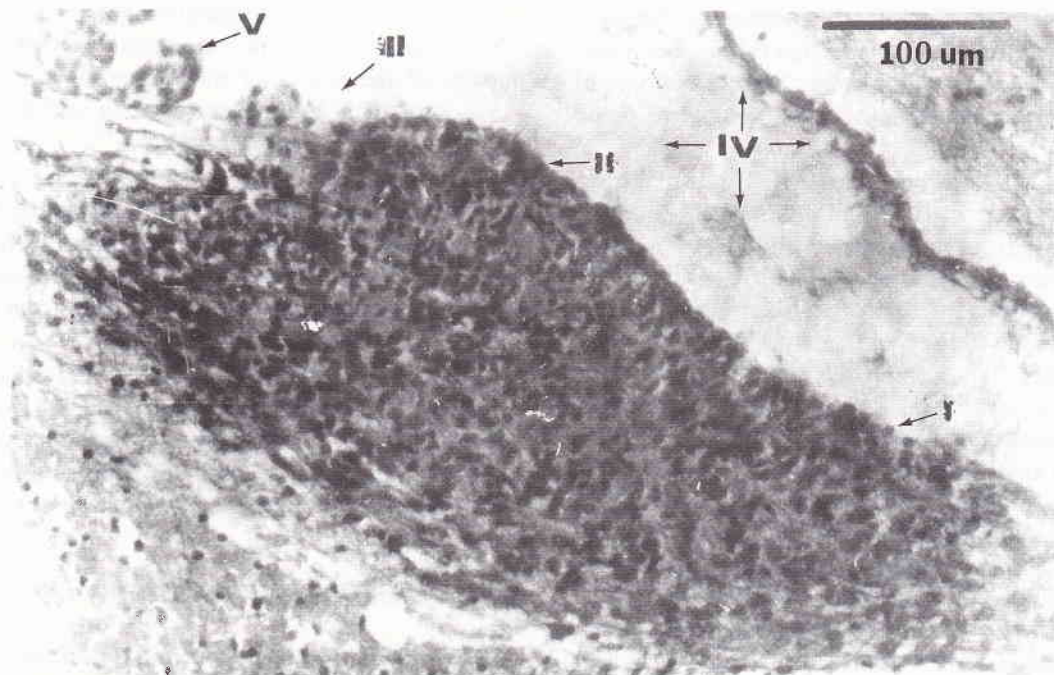


Figure 1. Median sagittal view of the rat brain, showing the location of the subfornical organ among the circumventricular organs, AP, area postrema; ME, median eminence; NL, neural lobe; OVLT, organum vasculosum of the lamina terminalis; PIN, pineal organ; Rec. recessus collicularis of the aqueduct; SFO, subfornical organ; SCO, subcommissural organ; I, cerebral third ventricle; II, choroid plexuses (from Weindl & Sofroniew, 1978).<sup>26</sup>

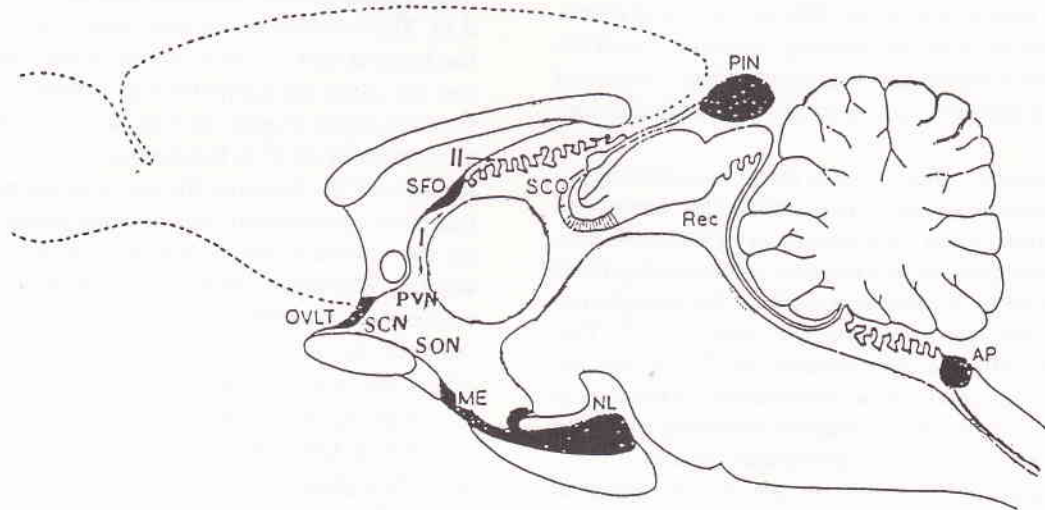


Figure 2. Median sagittal view of the rat brain, showing the structure of the subfornical organ, stained by hematoxylin-eosin (HE) staining technique. I, dorsal column; II, the body of the SFO; III, ventral column; IV, cerebral third ventricle; V, choroid plexuses of the cerebral third ventricle.

cated that the SFO is in fact a nucleus with neurons that appears to innervate directly other neurons in the paraventricular and supraoptic nuclei that release vasopressin from the posterior pituitary, as well as neurons in the median preoptic nucleus that project to those nuclei.<sup>8</sup>

The SFO is known to participate in drinking induced by angiotensin-II<sup>10,11</sup> and the control of vasopressin release from the posterior pituitary.<sup>12</sup>

The neurons in the subfornical organ have efferent projections to both the paraventricular and supraoptic nuclei of the hypothalamus (electrophysiological studies)<sup>7</sup> suggesting the importance of these pathways for controlling body fluid balance and central cardiovascular regulation.

Recent anatomic tracing studies done by Miselis by using an autoradiographic method,<sup>6</sup> Lind *et al.* by using horseradish peroxidase method (HRP method),<sup>7</sup> Renaud *et al.* by using electrical stimulation<sup>13</sup> and electrophysiological studies done by Ferguson *et al.*<sup>14</sup> and Ferguson and Kasting<sup>15</sup> have revealed the existence of afferents and efferents to and from the subfornical organ to both the supraoptic (SON) and paraventricular (PVN) nuclei of the hypothalamus, a region known to contain the cell bodies of oxytocin and vasopressin-secreting neurons<sup>14,16</sup> and regulate the circulating levels of the hormones. Electrical stimulation to the region of the SFO influences the excitability of the magnocellular neurosecretory neurons and the de-generation of the terminal axon both of SON and PVN.<sup>14,17</sup> Destruction of the SFO by electrical stimulation abolishes both the drinking response<sup>18</sup> and the rise in plasma vasopressin concentration<sup>12</sup> observed following intravenous administration of angiotensin-II.

The majority of neurons in the mammalian hypothalamic supraoptic and paraventricular nuclei are classic magnocellular neurosecretory cells synthesizing either vasopressin or oxytocin, and releasing these peptides from their axon terminals in the neurohypophysis in response to appropriate stimuli.<sup>17,19</sup> This process is called a neurosecretion.<sup>16,19</sup> From an anatomical viewpoint, these neurosecretory neurons in that receive a diversity of synaptic contacts, a third of which at least arise from extranuclear sources.

Oxytocin and vasopressin are typical neuronal hormones, i.e. hormones secreted into the circulation by nerve cells. The term neurosecretion was originally coined to describe the secretion of hormones by neurons.<sup>16</sup>

Like other peptide hormones, both vasopressin and oxytocin granules have a characteristic *neurophysin* associated with the granules in the neurons which secrete them, neurophysin I in the case of oxy-

tocin and neurophysin II in the case of vasopressin. The neurophysins were originally thought to be binding polypeptides, but it now appears that they are simply parts of the precursor molecules. The precursor for vasopressin is *preprovasopressin* and the precursor for oxytocin is *prepro-oxyphysin*.<sup>16</sup>

The SFO is implicated in angiotensin II-induced drinking,<sup>20</sup> a centrally mediated pressor response, and the release of vasopressin from the posterior pituitary.<sup>12,17</sup> Recent reports have described efferent projections to the supraoptic nucleus arising from neurons in the SFO.<sup>7,22</sup>

The aim of this investigation was to ascertain the anatomical nerve connections between the subfornical organ and the supraoptic and paraventricular nuclei of the hypothalamus, by utilizing neuroanatomical-tract tracing and immunoperoxidase method.

## MATERIALS AND METHODS

### Neuroanatomical-tract tracing method

Seven adult albino rats of the Wistar strain weighing between 250-350 g, were used in this experiment. Each animal was anesthetized intraperitoneally using 10% chloralhydrate and these rats were placed in the stereotaxic frame (Figure 3). One small hole in the skull was made into which a fine glass micropipette was placed, filled with a small amount of 4'-6-diamidino-2-phenylindol dihydrochloride (DAPI) (Figure 3,1). The location of the hole were 1,40 mm caudal to the bregma and 1,0 mm lateral to the linea sagittalis, and the glass micropipette was lowered into the subfornical organ (Figure 4). The depth was 4,31 mm and at an angle of 12,5° to the stereotaxic vertical plane. The location of the hole and the depth of the penetration of the glass micropipette was decided empirically, based on the animal's weight and also from the rats brain atlas by Paxinos & Watson.<sup>23</sup> The bregma was taken as the point of reference to establish a fixed relation between the measurement and geometry of the head where the hole is to be drilled.

The injection volume ranges from 0,03 - 0,04 ml of 2,5% DAPI. The solution was delivered into the SFO via a glass micropipette (Figure 3,1) connected to a Hamilton's microsyringe (Figure 3,3) over a period of 1 - 5 minutes. Each animal was allowed to survive for 48 - 72 hours and individually housed in a cage covered by a paper box and given food and water *ad lib* in the dark room, and sacrificed by intraventricular perfusion of 10% formalin in phosphate buffer (Millonig), under 10% chloralhydrate deep anaesthesia; afterwards the whole brain was removed.



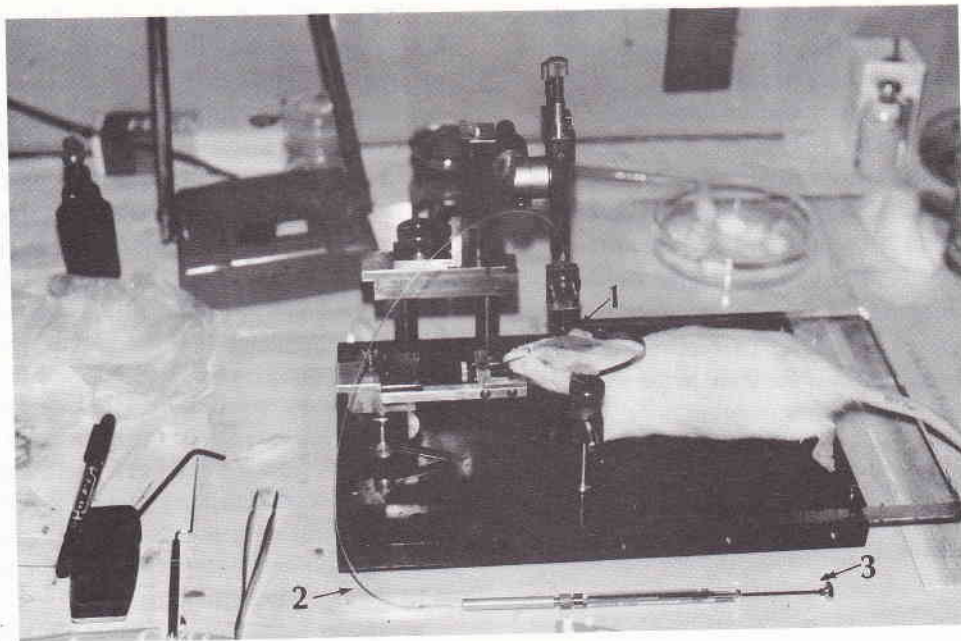


Figure 3. A figure showing a position of the rat in the stereotaxic apparatus. 1, a glass micropipette filled by a single fluorescent tracer DAPI; 2, polyethylene tube (PE-20); 3, Hamilton's microsyringe.

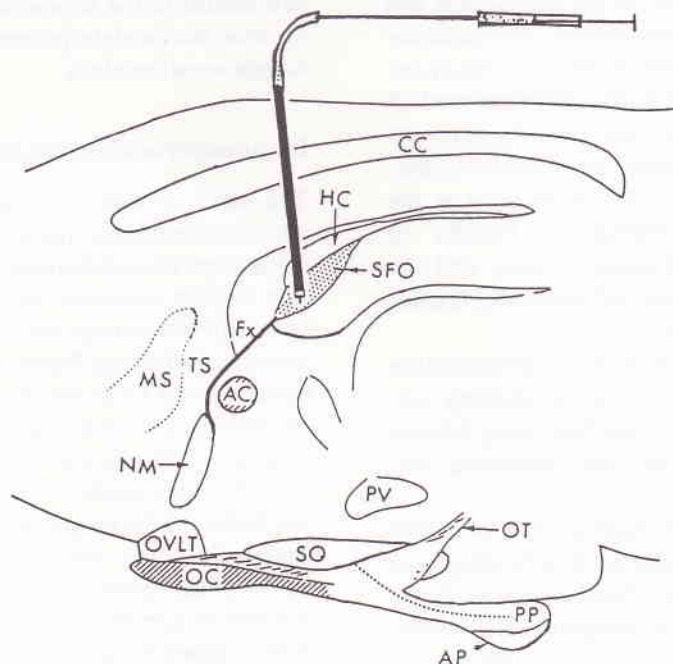


Figure 4. A schematic sagittal drawing of the rat diencephalon depict the location of the subfornical organ among the other nuclei in the brain and the position of the glass micropipette connected to a Hamilton's microsyringe (Figure 3, 3) at the stereotaxic coordinates, according to Paxinos & Watson,<sup>23</sup> which were 1,4 mm behind the bregma, and 1,0 mm lateral to the sulcus sagittalis (para sagittalis). The depth was 4,31 mm and at an angle of 12,5° to the stereotaxic vertical plane. CC, corpus callosum; HC, hypocampal commissure; SFO, subfornical organ; Fx, fornix; TS, triangular septal nucleus; MS, medial septal nucleus; AC, anterior commissure; NM, nucleus medianus; PV, hypothalamic paraventricular nucleus; OT, optic tract; OVLT, organum vasculosum of the lamina terminalis; SO, hypothalamic supraoptic nucleus; OC, optic chiasm; PP, posterior pituitary; AP, anterior pituitary (from Sgro et al.) Arrow indicates the exact location of the organ.

The brain was further immersed in 10% formalin (pH 7,3) for a while and then cut serially in frontal slices at 20  $\mu$ m thickness in a cryostat. The specimen was air-dried in a dark box and covered with non-fluorescent glycerine. Two out of every five sections were mounted on clean glycerine coated glass slides and the exact site of injections as well as the extent of diffusion within each structure were examined.

The sections were microscopically examined under the fluorescent microscope (Nikon optiphot-EF) with a filter system of U + 40K. Thereafter the exact location of the labeled cell was depicted in the enlarged map (18 X) of the brain section (camera lucida drawings).

This investigation by utilizing neuroanatomical-tract tracing method was done at the Department of Anatomy, Kobe University School of Medicine, Kobe, Japan.

### Immunoperoxidase method

This investigation used one of the immunohistochemical method, i.e. the immunoperoxidase method, and was based on the assumption of the production and secretion of neurosecretoric substances. The immunoperoxidase method, was based on the reaction of antigen-antibody complexes. This investigation used 15 adult, male and female albino rats, primary antibody (*Rabbit anti-human Neurophysin*), and *Labeled Strept-Avidin-Biotin* (LSAB) Kits, and were done at the Department of Anatomical Pathology, Faculty of Medicine, University of Indonesia, Jakarta and the Laboratory of Histology, Faculty of Medicine, Gadjah Mada University, Yogyakarta.

The staining procedure used in this investigation is one of the many immuno-enzymatic staining methods, i.e. the two-step indirect method using labeled streptAvidin-Biotin kit on parafine embedded sections.

These methods utilize the high affinity of avidin or streptavidin for biotin. Avidin has four binding sites for biotin. This method require a biotinylated antibody as a link antibody.<sup>24</sup> In this investigation the Rabbit anti-Human-Neurophysin was used as a primary antibody.

## RESULTS

### Neuroanatomical-tract tracing study

Seven animals received injection of DAPI in the subfornical organ.

Figure 5 is a frontal section of the brain, showing the site of DAPI injection, and the SFO filled with the injected DAPI (arrow).

Figure 6 is a frontal section of the rat brain at the stereotaxic coordinates of IA (interaural) 7,60 mm and bregma - 1,40 mm and IA 7,20 mm and bregma - 1,80 mm showing the sites of the DAPI labeled parent cell bodies in the supraoptic nucleus (a) and paraventricular nucleus (b). The color of the labeled parent cell body is a clear white upon a blue colored background. The results revealed that the parent nerve cell bodies in both paraventricular and supraoptic nuclei of the hypothalamus are clearly labeled. This figure also depicts the topography of the neurons in the supraoptic and paraventricular nuclei of hypothalamus.

The results of this investigation demonstrated that the single fluorescent tracer (DAPI) has labeled the parent cell bodies of the neurons in the paraventricular and supraoptic nuclei.

Figure 7. A camera lucida drawing the frontal section of the rat brain, at the stereotaxic coordinate of: (a) IA (interaural) 7,60 mm and bregma - 1,40 mm and IA 7,20 mm and bregma - 1,80 mm to depicts the topography and the sites of the DAPI labeled parent cell bodies in the supraoptic nucleus, paraventricular nucleus, the caudate-putamen nuclues and in the dorsal hippocampal nucleus.

### Immunoperoxidase study

The result of this investigation by using one of the immunoperoxidase methods using the LSAB kits revealed that the subfornical organ gave a positive reaction (*brown reaction*) and the location of the neurosecretoric substances which gave the positive reaction is extracellular (see Figure 8 and 9). On the other hand, figure 11 and 12 ab (frontal sections of the rat brain at the stereotaxic coordiates between IA 7,60 mm and bregma - 1,40 mm and IA 7,20 mm and bregma - 1,80 mm) showed a positive reaction (brown reaction) in the cell bodies of the magnocellular neurosecretory system (intracellular) in the paraventricular and supraoptic nuclei of the hypothalamus. The location of the brown reaction suggested that the neurosecretoric materials were synthesized and secreted by the nerve cell bodies of the magnocellular neurosecretory system in those nuclei.

## DISCUSSION

In this investigation the neural connection between the subfornical organ and supraoptic and paraventricular nuclei of the hypothalamus were verified using one

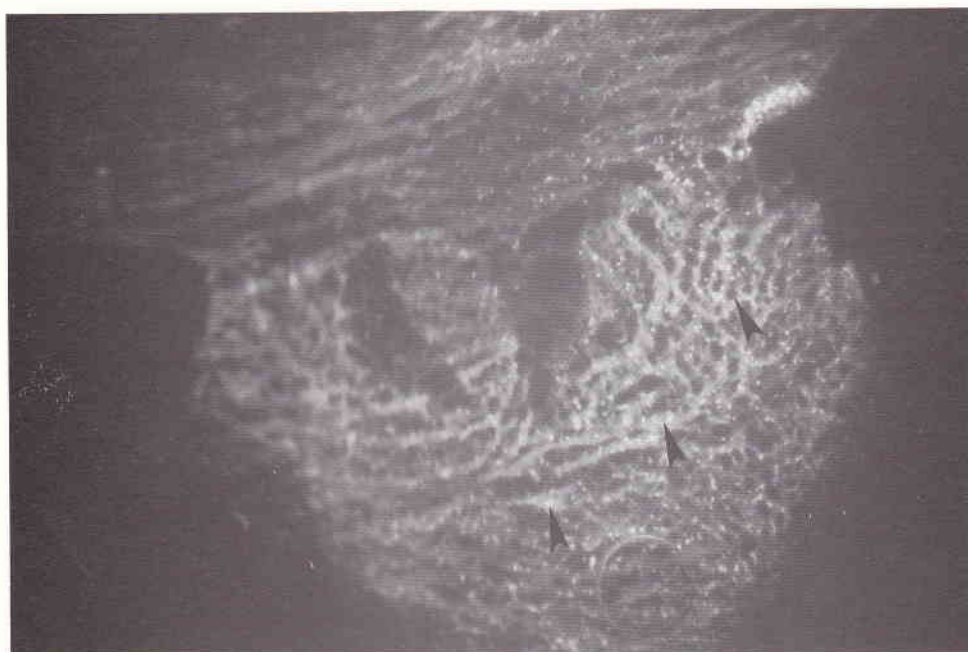

Figure 5. A frontal section of the rat brain at the stereotaxic coordinates between IA 7,60 mm and bregma - 1,40, and IA 7,20 mm and bregma - 1,80 mm, showing the examples of the sites of DAPI injection in the subfornical organ.

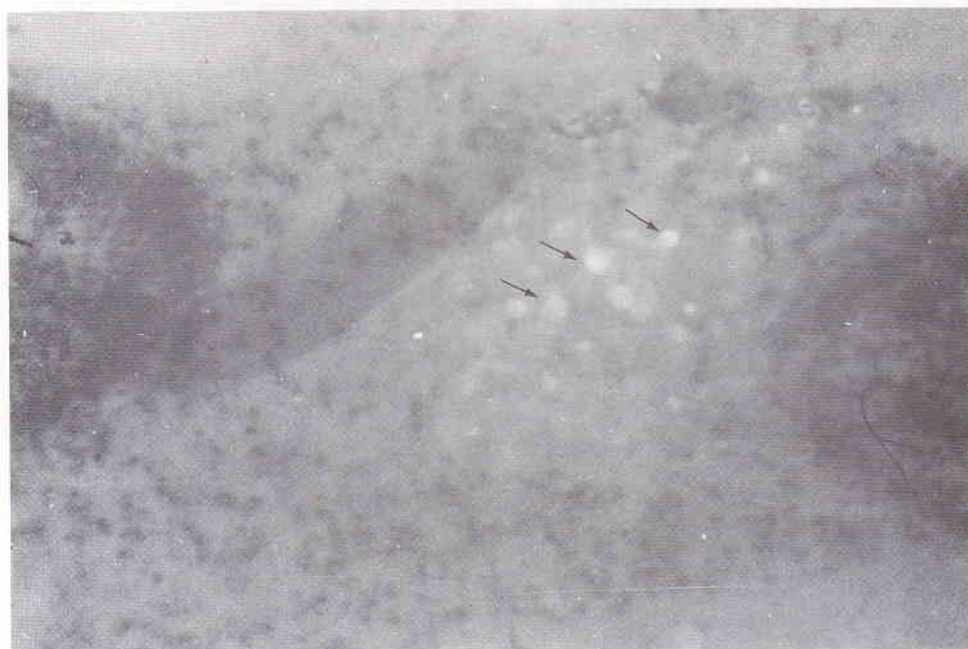

Figure 6. A frontal section of the rat brain at the stereotaxic coordinates of IA 7,60 mm and bregma - 1,40 mm showing an example of the sites of DAPI labeled parent cell bodies in the paraventricular nucleus (a) and IA 7,20 mm and bregma - 1,80 mm showing an example of the sites of DAPI labeled parent cell bodies in the supraoptic nucleus (b).



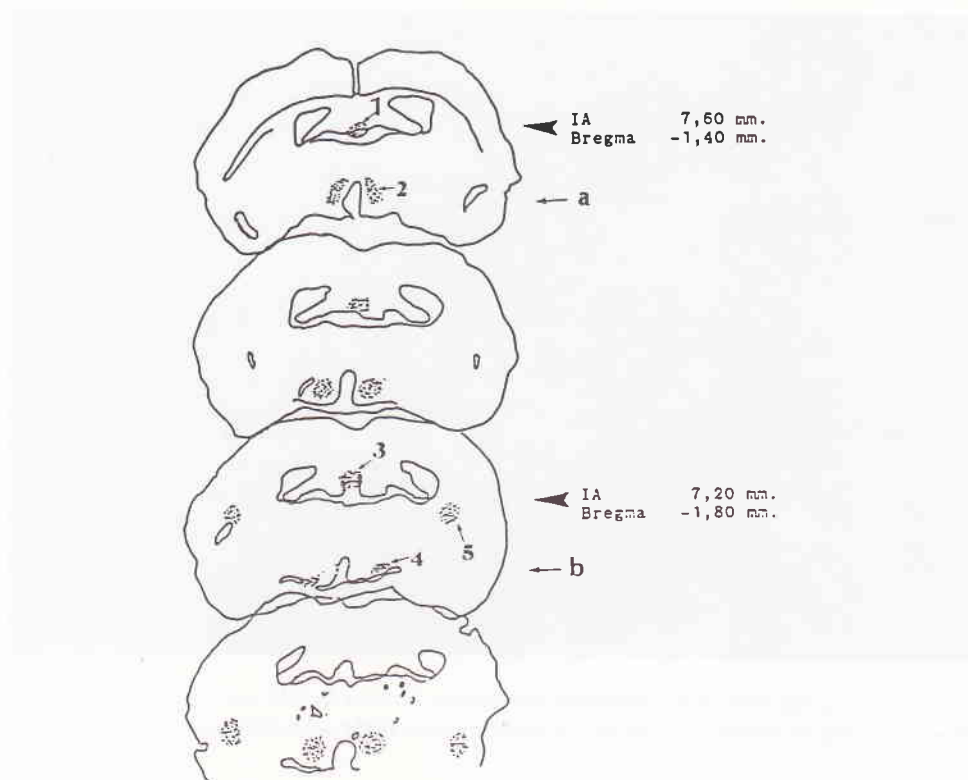


Figure 7. A camera lucida drawing of the frontal section of the rat brain, at the stereotaxic coordinates of: (a) IA (interaural) 7,60 mm and bregma - 1,40 mm showing the sites of the DAPI injection in the subfornical organ (1) and labeled parent cell bodies in the paraventricular nucleus (2); (b) IA 7,20 mm and bregma - 1,80 mm showing the sites of the DAPI labeled parent cell bodies in the dorsal hippocampal nucleus (3), the supraoptic nucleus (4), the caudate-putamen (5).

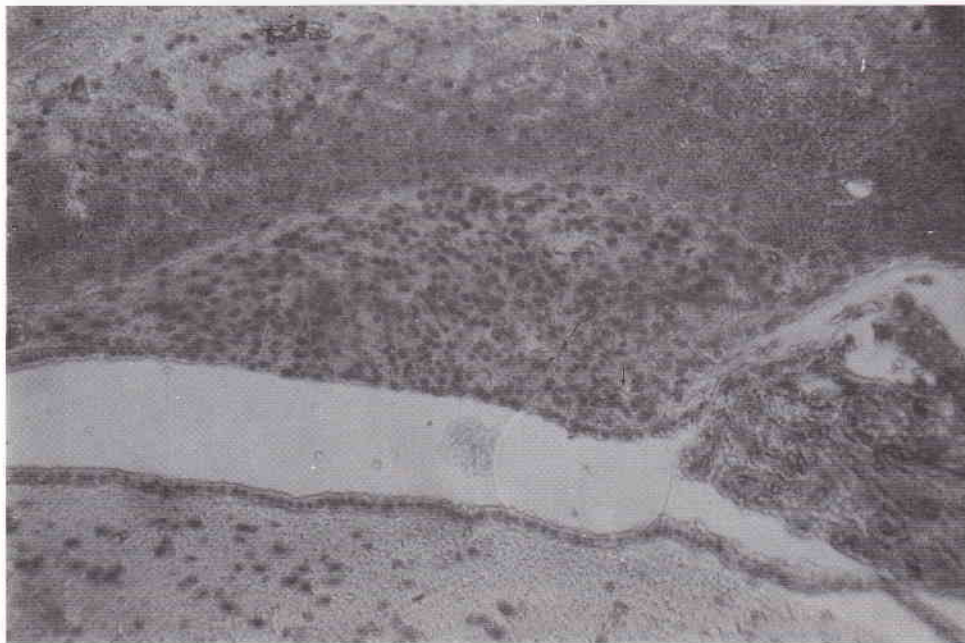


Figure 8. Photomicrograph of a median sagittal view of the rat brain, showing an example of the sites of positive reaction (brown reaction) to the Labeled StreptAvidin-Biotin staining method (LSAB) in the subfornical organ. The location of the brown reaction is extracellular. X 40.

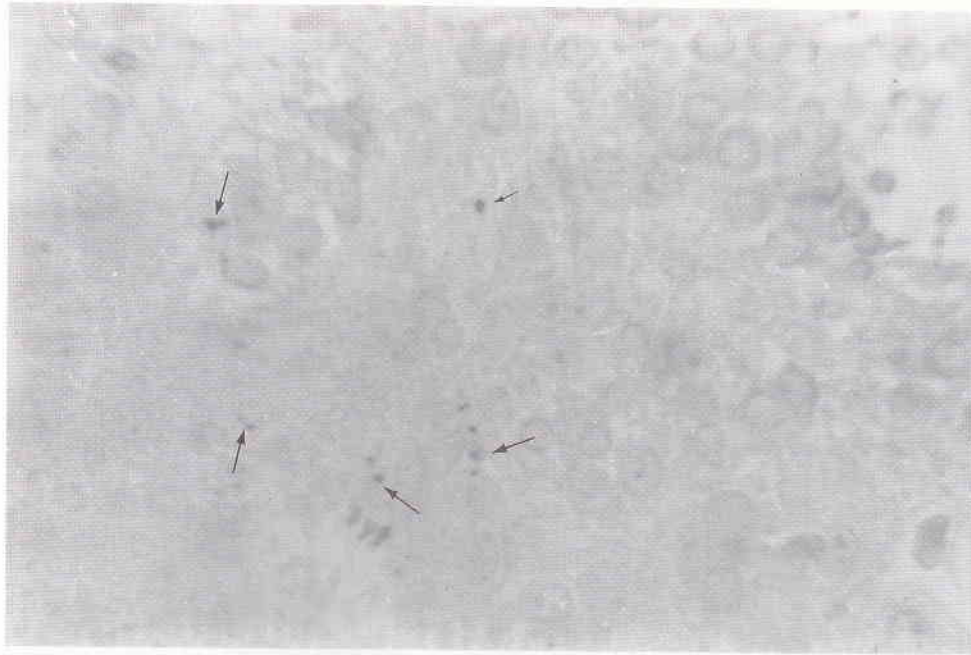

Figure 9. Photomicrograph of a median sagittal view of the rat brain, showing an example of the sites of positive reaction (brown reaction) to the Labeled StreptAvidin-Biotin staining method (LSAB) in the subfornical organ. The location of the brown reaction is extracellular. X 400.

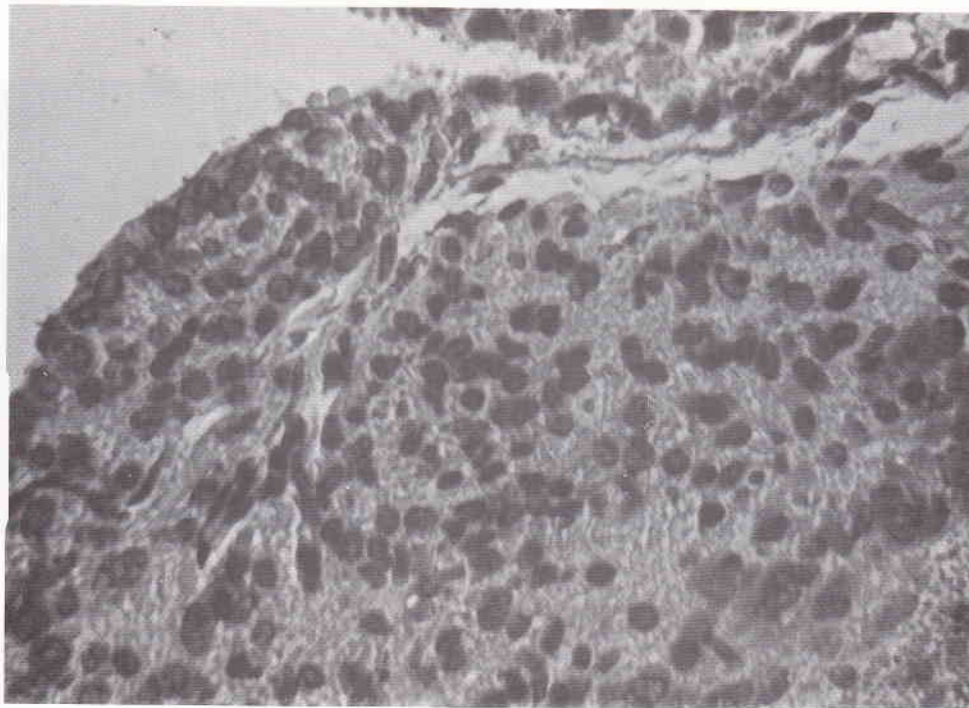
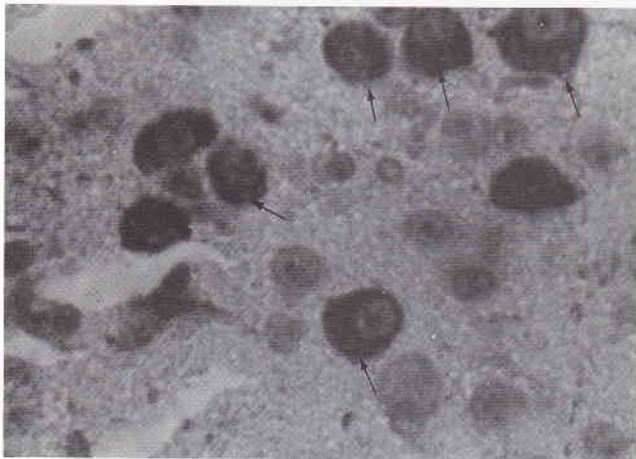


Figure 10. Photomicrograph of a median sagittal view of the rat brain, showing a negative control of the subfornical organ, stained by the LSAB staining method, but without adding a primary antibody. X 400.

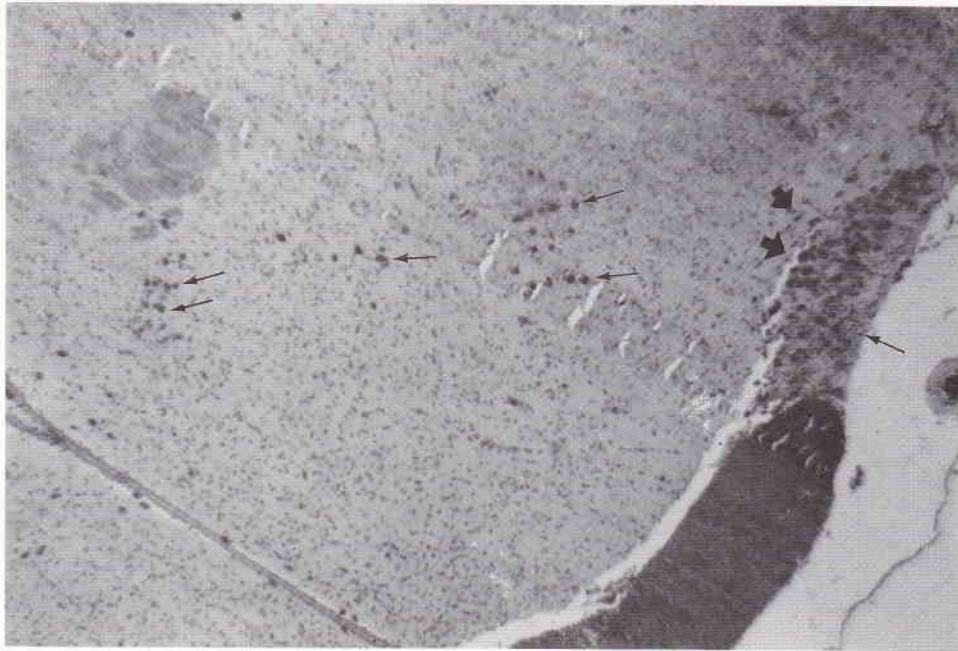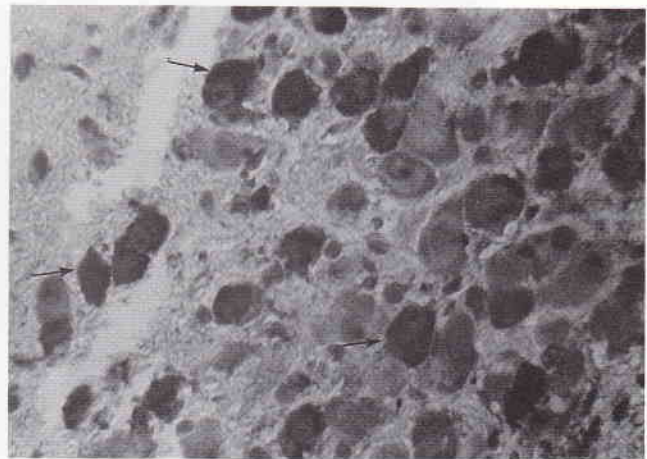




Figure 11. Photomicrograph of a frontal section of the rat brain at the stereotaxic coordinates between IA 7,60 mm and bregma - 1,40 mm, and IA 7,20 mm and bregma - 1,80 mm showing an example of sites of positive reaction (brown reaction) to the Labeled StreptAvidin-Biotin staining methods. The location of the brown reaction is in the nerve cell bodies of the magnocellular neurosecretory system (intracellular) in the supraoptic and paraventricular nuclei of the hypothalamus. The location of the brown reaction suggested that the neurosecretory were synthesized and produced by these nerve cell bodies of the magnocellular neurosecretory system in those nuclei. X 40.



**a**



**b**

Figure 12 ab. Photomicrograph of a frontal section of the rat brain at the stereotaxic coordinates between IA 7,60 mm and bregma - 1,40 mm, and IA 7,20 mm and bregma - 1,80 mm, showing an example of sites of positive reaction (brown reaction) in the nerve cell bodies of the magnocellular neurosecretory system (intracellularly) in the paraventricular (a) and supraoptic nuclei (b) of the hypothalamus. X 400.

of the neuroanatomical-tract tracing methods using a single fluorescent tracer 4',6-diamidino-2-phenylindol dihydrochloride (DAPI) (which was developed by Heimer and Robards)<sup>25</sup> and one of the immunoperoxidase methods, i.e. the Labeled StreptAvidin-Biotin techniques (LSAB), which was developed by Naish *et al.*<sup>24</sup>

Injection of a single fluorescent tracer (DAPI) in seven adult albino rats of the Wistar strain, demonstrated that DAPI had labeled the parent cell bodies of the neuron in the fourteen nuclei and areas in the brain, including the supraoptic and paraventricular nuclei of the hypothalamus.

In this study, the projections of nerve fibers to the subfornical organ from those nuclei, especially the supraoptic and the paraventricular nuclei, were verified by the retrogradely transported DAPI. These results that all labeled nerve fibers and cell bodies that were traced from the SFO were afferents of the supraoptic and paraventricular nuclei, according to the observations that labeled axons can be followed to retrogradely labeled neurons that may give rise to them.

Similar findings have been reported by investigators using other techniques, for examples, using electrophysiological methods, which stated that there were some connections between the SFO and the supraoptic and paraventricular nuclei of the hypothalamus,<sup>14,15</sup> and using the autoradiographic and tracer's anterograde transportation method which demonstrated the connections between the SFO and the median preoptic, supraoptic and paraventricular nucleus. Based upon an electrophysiological method and using acetylcholine, saralasin and atropin Saro *et al.*<sup>17</sup> demonstrated that there were some connections between the subfornical organ and the paraventricular nucleus.

The results of this investigation by utilizing the immunoperoxidase method on 15 rats of the LMR strain, showed a positive response by giving *brown reaction* in the subfornical organ. The location of the brown reaction, however, is extracellular. So this result revealed that the SFO contains neurosecretory materials, which was positive to the immunoperoxidase method. This method used *Rabbit anti-human neurophysin* as a primary antibody, and LSAB kit; the biotin linked to the primary antibody, produces a biotinylated conjugate which, when added to the tissue section, localizes the sites of antigen within the section.<sup>27</sup> The neurophysin, is a precursor of vasopressin and oxytocin hormones. Moreover, the existence of neurosecretory material extracellularly proves that this neurosecretory material was synthesized and produced by another nuclei in the brain. This result ensured that, in fact, no secretory cell were found in the SFO.

The origin of the neurosecretory material which gave a positive result by giving a brown reaction, turned out to be the neurosecretory material found in the cytoplasm of the cell bodies of the magnocellular neurosecretory system of the supraoptic and paraventricular nuclei of the hypothalamus. The neurosecretory material's existence in the cell bodies of those nuclei proved that this neurosecretory material was synthesized and produced by those nuclei.

Similar findings have been reported by other investigators, i.e. Stutinsky<sup>19</sup> and Ganong<sup>16</sup> which stated that the neurosecretory material was synthesized and produced by the cell bodies of the magnocellular neurosecretory system in the supraoptic and paraventricular nuclei of the hypothalamus. This neurosecretory material was then transported to the neurohypophysis via the hypothalamo-hypophyseal tract through the neurosecretion process (see Figure 13).

There was some neurosecretory material in the SFO which gave positive reaction to the immunoperoxidase staining methods, even though in small amounts. This proved that the SFO sends efferent projections in small amounts to those nuclei (see Figure 13).

This investigation using the LSAB kits, in fact, can be used as a tracer to trace the nerve fiber connections between the subfornical organ and the supraoptic and paraventricular nuclei of the hypothalamus and the results were in concordance with the other result by using the neuroanatomical-tract tracing method.

This investigation, concluded that by utilizing neuroanatomical-tract tracing method and immunoperoxidase method (LSAB kits) the subfornical organ was proved to be anatomically connected to the supraoptic and paraventricular nuclei of the hypothalamus.

## REFERENCES

1. Weindl A. Neuroendocrine aspects of circumventricular organ. In: Ganong WF, Martini L, eds. *Frontiers in neuroendocrinology*. New York: Oxford University Press, 1973:3-22.
2. Akert K, Potter HD, Anderson JW. The subfornical organ in Mammals. *Comparative and topographical anatomy*. *J Comp Neurol* 1961; 116:1-14.
3. Dellmann HD and Simpson JB. The subfornical organ. *International Rev Cytol* 1979; 58:333-421.
4. Mark MH, Farmer PM. The human subfornical organ: an anatomic and ultrastructural study. *Annals of clinical and Laboratory Science* 1984; 14(5):427-42.
5. Dellmann HD, Simpson JB. Regional differences in the morphology of the rat subfornical organ. *Brain Res*. 1976;116:389-400.
6. Miselis RR, Saphiro SE, and Hand PJ. Subfornical organ efferents to neural systems for control of body water. *Science* 1979;205:102-07.

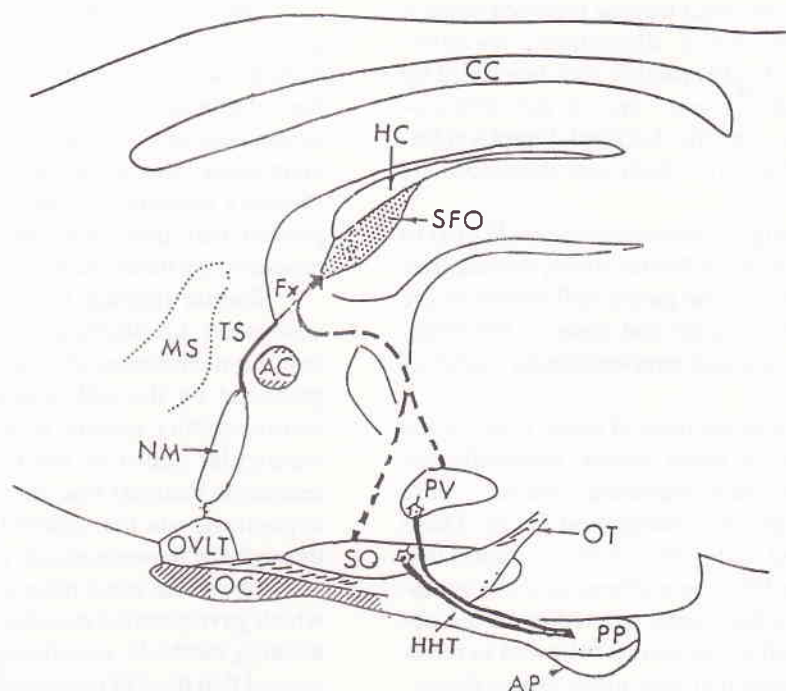


Figure 13. A schematic sagittal drawing of the rat diencephalon depict the location of the subfornical organ (SFO) lying in the rostral-dorsal of the third ventricle under the hippocampal commissure (HC) and fornix (Fx); in accordance with recent anatomical data,<sup>17,19</sup> neurosecretoric material is to be transported through a neurosecretion process in the hypothalamo-hypophysealis-tract (HHT) (solid heavy lines) from the supraoptic and paraventricular nuclei of the hypothalamus to the posterior pituitary (PP), some nerve fibers also projected to the SFO from those nuclei (intermittent lines). This nerve fibers transport a small amount of neurosecretoric material to the SFO and release it to the blood capillaries via terminal nerve ending (from Sgro et al.)<sup>17</sup>

7. Lind RW, Van Hoesen GW, and Johnson AK. An HRP study of the connections of the subfornical organ of the rat. *J Comp Neurol* 1982;210:265-77.
8. Sawchenko PE, Swanson LW. The distribution and cells of origin of some afferent projections to the paraventricular and supraoptic nuclei of the rat. *Soc Neuro-sci* 1981;7:325.
9. Ferguson AV, Day TA, Renaud LP. Subfornical organ efferents influence the excitability of neurohypophyseal and tuberoinfundibular paraventricular nucleus in the rat. *Neuroendocrinology* 1984;39:423-8.
10. Eng R, Miselis RR. Polydipsia and abolition of angiotensin-induced drinking after transections of subfornical organ efferent projections in the rat brain. *Brain Res.* 1981, 225:200-6.
11. Lind RW, Johnson AK. Subfornical organ-median preoptic connections and drinking and pressor responses to angiotensin-II. *J of Neuroscience* 1982;2(8):1043-51.
12. Knepel W, Nutto D, and Meyer DK. Effect of transection of subfornical organ efferent projections on vasopressin release induced by angiotensin or isoprenaline in the rat. *Brain Res* 1982;248:180-4.
13. Renaud LP, Rogers J, and Sgro S. Terminal degeneration in supraoptic nucleus following subfornical organ lesions: ultrastructural observations in the rat. *Brain Res* 1983; 275:365-8.
14. Ferguson AV, Day TA, Renaud LP. Subfornical organ stimulation excites paraventricular neurons projecting to dorsal medulla. *Am J Physiol* 1984;247:R1088.
15. Ferguson AV, Kasting NW. Electrical stimulation in subfornical organ increase plasma vasopressin concentrations in conscious rat. *Am J Physiol* 1986;251:R425-R428.
16. Ganong WF. *Review of Medical Physiology*. Los Altos, California. Lange Medical Publications, 1993.
17. Sgro S, Ferguson AV, Renaud LP. Subfornical organ-supraoptic nucleus connections: an electrophysiologic study in the rat. *Brain Res* 1984;303:7-13.
18. Summy-Long JY, Keil LC, Hernandez L, Emmert S, Chee O, and Severs WB. Effects of dehydration and renin on vasopressin concentration in the subfornical organ area. *Brain Res* 1984;300:219-29.
19. Stutinsky F. The place of neurosecretion in modern neurobiology. In : Vincent JD, Kordon C, eds. *Cell biology*



- of hypothalamic neurosecretion. Paris: Editions Du Centre National De La Recherche Scientifique, 1978.
20. Buggy J, Fisher AE, Hoffman WE, Johnson AK, Phillips MI. Ventricular obstruction: Effect on drinking induced by intracranial injection of angiotensin. *Science* 1975;190:72-4.
  21. Simpson JB, Epstein AN, and Camardo Jr JS. Localization of receptors for the dipsogenic action of angiotensin II in the subfornical organ of the rat. *J Comp Physiol Psychol* 1978;92(4):581-608.
  22. Swanson LW, Sawchenko PE. Hypothalamic integration: organization of the paraventricular and supraoptic nuclei. *Ann Rev Neurosci* 1983;6:269-324.
  23. Paxinos G, Watson C. *The Rat Brain, In Stereotaxic Coordinates*. San Diego, New York, London, Toronto: Academic Press, Harcourt Brace Jovanovich Publishers, 1986.
  24. Naish Sally J, Boenisch T, Farnilo AJ, Stead Ron H. *Handbook Immunochemical Staining methods*. Denmark : DAKO Corporation, 1989.
  25. Heimer L, Robards MJ. *Neuroanatomical-tract tracing methods*. New York: Plenum Press, 1981.
  26. Weindl A, Sofroniew MV. Neurohormones and circumventricular organs. In: Knigge KM, Scott DE, Weindl A eds. *Brain-endocrine interaction III. Neural hormones and reproduction*. Bassel : Karger, 1978; 117-37.
  27. Taylor CR, Bennington JL. *Immunomicroscopy: A Diagnostic Tool for the Surgical Pathologist*. Philadelphia, London, Toronto, Mexico City, Rio De Janeiro, Sydney, Tokyo, Hongkong: WB Saunders Company, 1986.