

## Surgical outcome of phacofragmentation and phacoemulsification in senile white mature cataract

Istiantoro Soekardi and Nandia Primadina

### Abstrak

*Tujuan : membandingkan efektifitas dan keamanan antara teknik fakofragmentasi dan fakoemulsifikasi yang dilakukan pada katarak senilis matur. Metoda : penelitian ini merupakan penelitian prospektif dengan metoda tersamar ganda terhadap 32 pasien katarak senilis matur putih yang dilakukan bedah katarak insisi kecil dengan pemasangan lensa intra okular (LIO). Pasien dibagi menjadi 2 kelompok secara acak, 16 pasien menjalani bedah katarak dengan teknik fakofragmentasi (kelompok I) dan 16 pasien lain dengan teknik fakoemulsifikasi (kelompok II). Parameter keamanan adalah perubahan diameter pupil sesaat sebelum pembedahan dan sesaat sebelum implantasi LIO, ketebalan kornea dan jumlah sinar di bilik mata depan (BMD). Lama waktu mengeluarkan nukleus, tajam penglihatan tanpa koreksi (TPTK) dan surgically induced astigmatism (SIA) yang terjadi dipakai sebagai parameter efektifitas. Tindak lanjut dilakukan pada hari ke-1, ke-7, ke-15 dan ke-30 pasca bedah. Hasil : tidak terdapat perbedaan bermakna pada variabel usia, tajam penglihatan, ketebalan kornea dan jumlah sinar sebelum pembedahan antara kedua kelompok. Rerata diameter pupil sebelum pembedahan dan sebelum implantasi LIO tidak berbeda bermakna, serta tidak didapatkan perubahan konstiksi pupil yang signifikan pada kedua kelompok. Lama waktu mengeluarkan nukleus lebih lama pada kelompok II ( $4.38 \pm 2.51$  mnt) dibanding kelompok I ( $1.98 \pm 1.61$  mnt). Perbedaan bermakna hanya terjadi pada TPTK ( $p=0.00067$ ) dan ketebalan kornea ( $p=0.0044$ ) pada tindak lanjut hari pertama. Namun, tidak didapatkan lagi perbedaan bermakna pada tindak lanjut selanjutnya. Tidak terdapat perbedaan bermakna pada variabel jumlah sinar dan SIA selama tindak lanjut. Kesimpulan : teknik fakofragmentasi dan teknik fakoemulsifikasi yang dilakukan pada katarak senilis matur memberikan hasil keamanan dan efektifitas yang sama baik. Teknik fakofragmentasi tampaknya dapat merupakan suatu alternatif bedah katarak insisi kecil dan dapat menggantikan bedah katarak konvensional, dengan tujuan untuk meningkatkan kualitas bedah katarak. (Med J Indones 2003; 12: 94-102)*

### Abstract

*Purpose : To compare the effectiveness and safety of phacofragmentation and phacoemulsification techniques on senile white mature cataract. Methods : Prospective, double masked, randomized study comprises 32 eyes of senile white mature cataract randomly divided into 2 groups, 16 eyes had phacofragmentation (group I) and 16 eyes had phacoemulsification (group II). The evaluated safety parameters were pupil diameter pre surgery and prior to intra ocular lens (IOL) implantation, corneal thickness and flaremeter. Nucleus delivery, uncorrected visual acuity (UCVA) and surgically induced astigmatism (SIA) were the effectiveness parameters. Follow-up were scheduled for post-operative day 1, 7, 15 and 30. Results : prior to the surgery there were no significant differences in age, visual acuity, corneal thickness and flaremeter between two groups. Pre surgical and prior to IOL implantation mean pupillary diameters in both groups were not significantly different. There was no significant difference in pupillary constriction on both groups. The mean of time to deliver the nucleus was significantly longer in the group II ( $4.38 \pm 2.51$  min) than in the group I ( $1.98 \pm 1.61$  min). There was significant difference on UCVA ( $p=0.00067$ ) and corneal thickness ( $p=0.0044$ ) only on the first post-operative day. However, there was no significant difference on further evaluations ( $p>0.05$ ). There were also no significant difference on flaremeter and SIA during follow-up. Conclusion : Both phacofragmentation and phacoemulsification techniques were effective and safe for cataract surgery on senile white mature cataract. Phacofragmentation technique therefore could be an alternative small incision cataract surgery. (Med J Indones 2003; 12: 94-102)*

**Keywords :** phacofragmentation, phacoemulsification, senile white mature cataract

Senile white mature cataract is an advanced form of cataracts disease that constitutes a significant

proportion of blindness in developing countries such as Indonesia. These kind of cataract is relatively dangerous and unpredictable due to the absence of retroillumination, which makes a consistent achievement of continuous curvilinear capsulorhexis (CCC) difficult. In addition, the hardness of the

nucleus suggests potential complications such as corneal endothelial injury, posterior capsule rupture and zonular dialysis.<sup>1-4</sup>

Presently, phacoemulsification is the ideal technique for the management of cataract because of the rapid wound healing, minimal post-operative induced astigmatism and early visual rehabilitation.<sup>1,5,6</sup> This surgical technique and phacoinstrumentation can be safely applied in varying hardness cataract including white mature cataract. Unfortunately, it gives satisfactory result only if it is performed by experienced surgeons.<sup>3,4</sup> Phacoemulsification of mature cataracts doing by novice surgeon is often accompanied by intraoperative complications. Moreover, the cost of the phaco unit also prevents its use by many surgeons in developing countries.

Therefore, there is a significant interest to perform small incision cataract surgery without phacoemulsification in order to avoid the sometimes difficult and long learning curve of phacoemulsification. Manual techniques were thus developed to achieve benefits similar to phacoemulsification, which enables safe and easy nucleus removal, even by novice surgeons.<sup>6-9</sup> One of alternative techniques of small incision cataract surgery for mature cataract is phacofragmentation.

Phacofragmentation is a manual fragmentation of nucleus into small pieces for reducing the size of the nucleus.<sup>9-11</sup> This technique is economical, requires inexpensive and uncomplicated mechanical instrumentation.<sup>6-9</sup>

Although some literatures reported a successful result of manual small incision cataract surgery techniques, a comparative analysis between phacoemulsification and phacofragmentation has not been reported.<sup>4,8,12,13</sup> There is still a question whether phacofragmentation and phacoemulsification in senile white mature cataract will give similar results.

This article presents a comparison of the effectiveness and safety of phacofragmentation and phacoemulsification in white mature cataract.

## METHODS

### Patients and Study Design

We prospectively evaluated cases of senile white mature cataract patients at dr. Cipto Mangunkusumo

Hospital and Dharmais Cataract Project, Jakarta. The inclusion criteria were patients with senile white mature cataract, 50-75 years of age, best corrected visual acuity less than 3 meters finger counting, and no history of diabetes, hypertension, intra ocular inflammation, glaucoma, retinal disease nor intra ocular surgery and ocular injury. The patients were excluded from the study if there was endophthalmitis post-operatively or having posterior segment abnormalities except cystoid macular edema known after follow-up or the patients did not come in post-operative evaluation. The ethic committee approved the study and written informed consents were obtained from all patients. The eyes of the patients included in this study, were randomly assigned to 1 of 2 groups, one group had phaco-fragmentation and another group had phacoemulsification.

### Pre-operative Examinations

Pre-operative examinations comprised a complete ocular examination, uncorrected and corrected visual acuity using Snellen chart. The result of visual acuity was converted into Snellen decimal fraction. Keratometry, ultrasonic corneal pachymetry, laser flaremetry and intra ocular pressure (IOP) using non-contact tonometer were also performed. The pre-operative examinations were performed by an expert (AI).

### Surgical technique

All surgeries were performed by one surgeon (IST), who has reasonable experience in both phacofragmentation and phacoemulsification. All patients were given topical anesthesia with Tetracaine 0.5% (Pantocain<sup>®</sup>) and tropicamide 0.5% (Mydriatyl<sup>®</sup>) to achieve a good dilated pupil, beginning at one hour pre surgery and every 15 minutes until the operation started.

After cleaning the surgical area and separated the eyelid with eye speculum, 2% Lignocaine hydrochloride was injected at the superior conjunctiva. A 6.0 mm fornix-based conjunctival flap was created superiorly, and a half-thickness 6.0 mm frown incision was made 2.5 to 3.0 mm behind the limbus. Then, scleral tunnel was performed with crescent knife. A side entry was made at 10 o'clock continued with injecting air. About 0.1 ml of 0.1 % Trypan Blue solution (Vision Blue<sup>®</sup>) was injected for staining the anterior capsule of the lens, and sodium hyaluronate was then injected to remove the air. After that, a CCC with diameter of 7 mm was made with a bent cystotome.

The anterior chamber was entered through the tunnel with a 3.2 mm keratome followed by hydrodissection in phacoemulsification. The Alcon Universal II was used and posterior chamber phacoemulsification was done using phaco-chop technique. The residual cortex was removed using the irrigation / aspiration (I/A) handpiece. Then, the tunnel was enlarged to 5.5 mm with a crescent knife. A single-piece PMMA posterior chamber IOL was implanted in the bag with the aid of viscoelastic material. After the IOL was centered, the residual viscoelastic material was removed followed by a carbachol (Myostat<sup>®</sup>) injection. The anterior chamber was reformed with Balanced Salt Solution (BSS) and the wound tested for integrity. No sutures were used.

Surgical technique of phacofragmentation, began with perforation through the base of the tunnel into the anterior chamber with a 3.2 mm keratome, followed by the crescent knife to enlarge the internal aspect to 5.5 mm. Hydrodissection was performed by injecting BSS with a cannula. The injection of BSS was continued until the nucleus was completely separated from the lens capsule and cortex, after that the nucleus was luxated into the anterior chamber using the cannula. Once the nucleus was luxated into the anterior chamber, sodium hyaluronate was injected into the surrounding area to fill the anterior chamber, and a small amount of sodium hyaluronate was injected behind the nucleus to hold it in the tilted position. Then, the nucleus was fragmented by placing a cutting board beneath the nucleus, and the nucleus cutter on top of the nucleus. Pressure was created by slowly pressing the nucleus cutter against the cutting board until the nucleus was fragmented into 2 pieces. Additional viscoelastic was injected and the cannula was used to position the first nucleus fragment accessible for removal. Then, the first nucleus fragment was extracted using conjunctival pincers. Additional viscoelastic was used to isolate the second nucleus fragment for further extraction. After the entire nucleus fragments was removed out from the anterior chamber, the residual cortex was aspirated with an I/A cannula. A single-piece PMMA posterior chamber IOL was implanted in the bag with the aid of viscoelastic. After the IOL was centered, the viscoelastic material was aspirated followed by a carbachol (Myostat<sup>®</sup>) injection. The anterior chamber was reformed with BSS and the wound tested for integrity. No sutures were used.

The surgery concluded with a subconjunctival injection of antibiotic and steroid. Then, the eye was

instilled with a mixture of dexamethasone, neomycine and polymixine sulfate (Cendo Xitrol<sup>®</sup>) eye drops and continued to instill six times daily for 2 weeks and 4 times daily for the following week.

### Post-operative Examinations

Follow-up examinations were scheduled for day 1, 7, 15 and 30 post-operatively. The examinations are similar to pre-operative examinations, i.e. visual acuity without and with correction, IOP, pachymetry and flaremetry. The post-operative examinations were also performed by an expert (AI). Surgically Induced Astigmatism (SIA) was calculated using Olsen vector analysis<sup>14</sup> for day 15 and day 30 post-operatively.

The result was used to evaluate the effectiveness and the safety for each technique. Nucleus delivery, UCVA and SIA were the effectiveness parameter and the safety parameter comprised of pupil diameter, corneal thickness and flare value. Complication during surgery and follow-up were also evaluated.

### Statistical Analysis

The comparison between the two techniques was analysed with the t test and chi-square test. Statistical analysis of the relationship between the visual acuity, corneal thickness, flare value and IOP was done using Pearson correlation test and regression analysis. P-values that are less than 0.05 were considered statistically significant

## RESULTS

Thirty-three patients (33 eyes) with senile white mature cataract underwent small incision cataract surgery between April 2001 to August 2001. One patient was excluded from this study, because the patient did not come in follow-up examination. There were 16 eyes in the phacofragmentation group and 16 eyes in the phacoemulsification group. Comparison of pre-operative variable means showed no statistical difference between the two groups, thus both groups were comparable (Table 1).

This study compared the efficacy and safety between two techniques. One of the safety parameters was the change of pupil diameter, which measured before operation and before IOL implantation.

Table 1. Patient characteristics after randomization

Pre-operative Characteristic	Group		p value
	Fragmentation (n = 16)	Emulsification (n = 16)	
Age (years)	57.8 ± 6.87	57.8 ± 8.02	0.5
Visual Acuity	HM*	HM*	-
IOP (mmHg)	11.88 ± 3.05	12.38 ± 3.09	0.32
Pachymeter (µm)	533.3 ± 27.3	528.1 ± 20.97	0.28
Flaremeter (photons/msec)	12.73 ± 9.02	11.15 ± 7.25	0.29

\*HM : hand movement

Table 2. Pupil diameter pre surgery and prior to IOL implantation

	Pupil Diameter (mm) ( Mean ± SD )		p value
	Fragmentation	Emulsification	
Pre surgery	8.28 ± 0.63	8.03 ± 0.65	0.138
Prior to IOL implantation	7.72 ± 0.71	7.81 ± 0.73	0.357
p value	0.012	0.188	

Table 2 shows that there was no significant difference (p>0.05) on pupil diameter pre surgery between two groups, and prior to IOL implantation. If the t test was done within group, it showed that there was no significant difference on phacoemulsification group, however, there was significant difference (p<0.05) on the phacofragmentation group.

The mean of nucleus remove time was significantly higher in the phacoemulsification group (4.38 ± 2.51 min) than in phaco-fragmentation group (1.98 ± 1.61 min).

Intraoperatively, there were two cases with scleral flap tearing (1 eye on phacofragmentation group and 1 eye on phacoemulsification group) and one case in phacofragmentation group with small capsulorhexis

diameter. All cases were caused by poor patient cooperation; so that, the surgeon had difficulties to make scleral flap and capsulorhexis with diameter of 7 mm. Two cases with scleral flap tearing needed one suture, and a relaxing incision was performed in one case with small capsulorhexis diameter.

Figure 1 shows a significant difference in corneal thickness on day 1 (p= 0.0044). Corneal edema on the phacofragmentation group (871.94 ± 289.24 µm) was more severe than in the phacoemulsification group (646.50 ± 109.08 µm) on day 1. Then, the corneal edema was dramatically decreased on the subsequent examination and no statistically difference (p > 0.05) between two groups on day 7, 15 and 30 post-operatively.

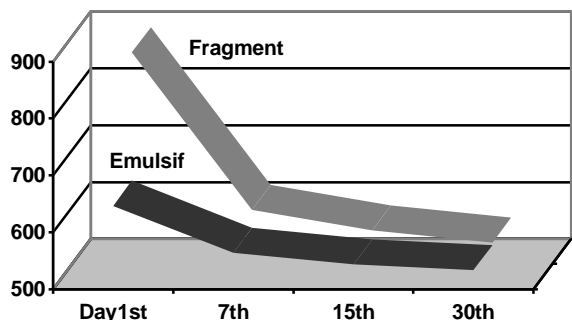


Figure 1. Post-operative corneal thickness (µm)

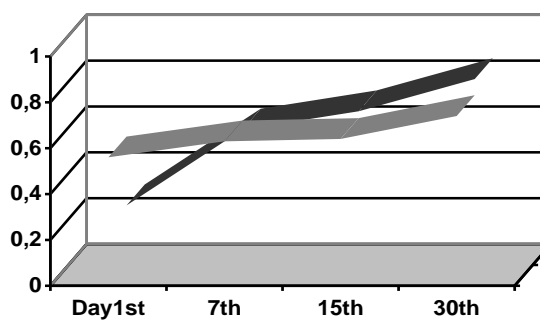


Figure 2. Post-operative uncorrected visual acuity

Post-operative UCVA was significantly better in the phacoemulsification group ( $0.56 \pm 0.24$ ) than in the phaco-fragmentation group ( $0.26 \pm 0.24$ ) only at day 1 ( $p= 0.00067$ ). There was no statistically difference ( $p>0.05$ ) during the subsequent examinations (Figure 2).

Figure 3 shows post-operative flare value on the two groups, and statistically there was no difference between the 2 groups. The highest flare value occurred on the first post-operative day in the phacoemulsification group. However, in the phaco-fragmentation group, flare readings could be obtained in only 12 patients on the first post-operative day because of severe corneal edema.

Post-operative IOP comparison between two groups showed that there was no statistical difference for all follow-up schedule (Figure 4).

Pearson correlation and analysis of regression are shown in Table 3 which resulted a negative correlation between pachy value, flare value and IOP variables

with visual acuity variable. The highest correlation was between pachy value and visual acuity variables.

Multivariate analysis evaluating contribution of pachy value, flare value and IOP variables against visual acuity variable, reveals that only pachy value gives the highest contribution and statistically significant to visual acuity.

Comparison between total SIA vectors which calculated with Olsen’s vector analysis, shows that there is no significant difference between two groups on day 15 and day 30. Mean induced astigmatism post-operatively on day 15 was  $1.16 \pm 0.62$  D in phaco-fragmentation group and  $1.33 \pm 0.83$  D in phacoemulsification group. The total vector of SIA was decreased on day 30 compared to total vector on day 15, on both groups. Mean induced astigmatism was  $0.79 \pm 0.51$  D in phaco-fragmentation group and  $0.95 \pm 0.75$  D in phacoemulsification group. The axis component was changed on both groups, and tends to with the rule direction.

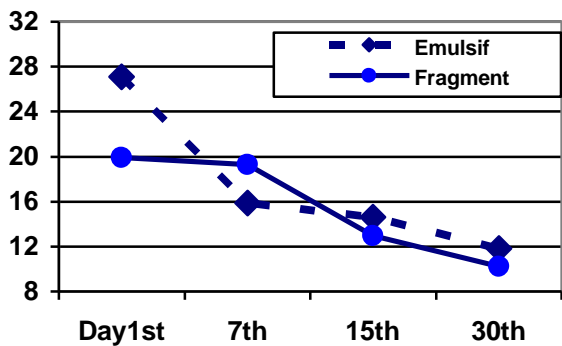


Figure 3. Post-operative flare value in the anterior chamber (photons/msec)

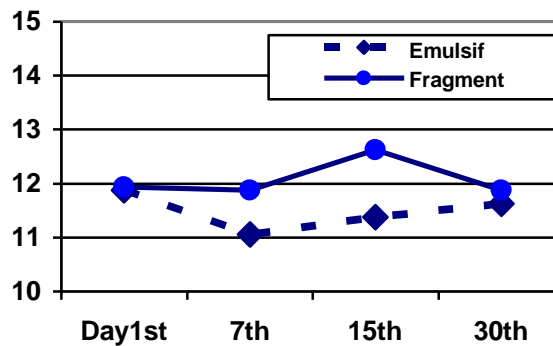


Figure 4. Post-operative intra ocular pressure (mmHg)

Table 3. Correlation between visual acuity and post-operative variables

	Pearson Correlation		Regression Analysis		
	Corr.	p value	Beta	t	p value
<b>Pachymetry</b>	-0.464	0.000	-0.450	-5.459	0.000
<b>Flaremeter</b>	-0.133	0.067	-0.088	-1.090	0.278
<b>IOP</b>	-0.021	0.407	-0.029	-0.362	0.718

Dependent variable : visual acuity

## DISCUSSION

Small incision cataract surgery leads to less induced astigmatism, faster visual rehabilitation and stability from the early post-operative stage.<sup>8</sup> Phacoemulsification has overtaken the large incision extra capsular cataract extraction (ECCE) and multiple suture methods. It is an ideal technique for the management of cataract and being the method of choice for most surgeons.<sup>1,3,4</sup> However, it requires expensive instrumentation and has a relatively long learning curve, and in mature cataract cases, it is often accompanied by a high incidence of serious complications.<sup>5-7</sup>

Hence, manual techniques such as mininuc, phaco-sandwich and phacofrag-mentation techniques, were then developed to achieve benefits similar to the phacomulsification.<sup>6,8,11,12,15</sup> If ECCE is performed using a small self sealing incision, post-operative visual recovery and stability could rival that of phacoemulsification.

Phacofragmentation is one of the alternative techniques of small incision cataract surgery on mature cataract. The aim of phacofragmentation technique is to reduce the size of a hard and big nucleus in senile mature cataract, thus it can be extracted through a small incision by cutting the nucleus into small pieces.<sup>7,8,10,12,16</sup>

The aim of this study is to compare the safety and the effectiveness of phacofrag-mentation and phacoemulsification techniques. Pre-operatively, both groups were tested to ensure that the groups had no significant difference statistically. The method was to compare each group with respect to age, visual acuity, IOP, corneal thickness and flare value (Table 1).

One of the safety parameters during operation is the change of pupil diameter pre surgery and prior to IOL implantation. The result of pupil diameter in the two groups is shown in table 2. It can be seen that there is no significant difference on pupil diameter before operation and before IOL implantation between two groups. Although the t-test within phacoemulsification group shows no significant difference, there is significant change in phacofragmentation group.

It seems that in phacofragmentation technique, there was an excessive nucleus manipulation in the anterior chamber, especially in luxation, cutting and extraction phases, which resulted in a greatest pupil diameter

change.<sup>8</sup> This miosis is usually caused by increasing iris manipulation which stimulates the iris and causing an irritation response of the eye ball. It can be also caused by an unstable anterior chamber with multiple collapse and inadequate dilatation before surgery.<sup>17-19</sup>

The pupil diameter change of more than 3 mm is considered to affect the safety of surgery. In this study the difference is less than 3 mm in both groups, so that both techniques are acceptable and safe for mature cataract.

The effectiveness parameter during surgery is nucleus delivery time. The average time to remove the nucleus in the phacoemulsification group ( $4.38 \pm 2.51$  min) was significantly longer than in the phaco-fragmentation group ( $1.98 \pm 1.61$  min). On phacoemulsification technique, the time to remove the nucleus was dependent on ultrasound energy, vacuum energy and the surgeon skill, while in phacofragmentation technique was only surgeon dependent.

During the surgery, there were 3 complication cases, although there was no serious complications such as posterior capsule rupture, vitreous loss, zonular dialysis or dislocation lens fragment into the vitreous. These cases occurred because of non-cooperative patients, so that the surgeon had difficulties to perform the surgery. Two cases with scleral flap tearing need one suture each on the edge of the scleral flap, because the incision was less water tight. The suture was not expected to increase the SIA value. Another case of small capsulorhexis diameter needs relaxing incision in prolapsing the nucleus into the anterior chamber. There was no sequential complication on the three cases.

The safety and effectiveness parameters during follow-up examinations are corneal thickness and UCVA. This study shows that there is a significant difference in corneal thickness and UCVA on the first post-operative day (Figure 1 and 2). There was severe corneal edema on phacofragmentation group that decreased the visual acuity.

Corneal edema has been reported as a significant post-operative complication of phacofragmentation technique. Intra ocular manipulation around the nucleus because of the two instruments and difficulties in delivering the nucleus, may have been responsible for the endothelial damage in phacofragmentation technique.<sup>8</sup> In phacoemulsification, the operative factors associated with corneal endothelial injury include

nuclear hardness, irrigating solution turbulence, the use of high vacuum, traumatic ultrasonic energy and IOL contact.<sup>8,20</sup> Matheu et al<sup>21</sup> reported that the endothelial cell loss with phacoemulsification was 7-15% and 11% on phacofragmentation technique. The same result was also reported by Vajpayee et al.<sup>8</sup>

The severe corneal edema on phacofragmentation group in this study, could be caused by excessive manipulation in the anterior chamber or difficulties in extracting the nucleus fragment through the small incision. More viscoelastic material was needed in phacofragmentation technique for minimising the damage of corneal endothel, iris and posterior capsule.<sup>8</sup> Hepsen et al<sup>9</sup> reported that the critical step in endothelial safety is the point of fragmentation and minimising endothelial contact by adding the viscoelastic material. He also reported that viscoelastic use and progression in the learning curve can lower the endothelial related complications.

The corneal edema is a common transient post-operative phenomenon resulted from compromised endothelial function after intraocular surgery. However, if corneal edema persists post-operatively, this may reflect irreversible endothelial damage.

The corneal edema on phacofragmentation group was dramatically decreased, so there is no statistically significant difference of UCVA and corneal thickness on the subsequent examinations. The corneal thickness returned to its pre-operative values by one month on both groups. Same results were also reported by Hepsen et al<sup>9</sup> and Singh et al<sup>22</sup>. The decrease of corneal edema may caused by good corneal endothel function which ideally measured by specular microscope. Due to unavailability of the instrument, pachymeter is utilised to evaluate the corneal thickness.

Post-operative inflammatory response after cataract surgery maybe related to such factors as surgical technique, IOL type, previous inflammatory disease and degree of iris pigmentation. And inflammation may induce complications such as corneal edema, IOP spikes, cystoid macular edema and posterior capsule opacification.<sup>23</sup> Anterior segment inflammation causes blood aqueous barrier breakdown and this disruption is clinically detected in the form of aqueous flare, measured by laser-flare meter.<sup>23,24</sup>

The other safety parameter in this study was flare value, which could also affect the post-operative

visual acuity. This study shows a highest flare on the first post-operative day,  $19.89 \pm 14.13$  photons/ms in the phacofragmentation group and  $27.09 \pm 13.25$  photons/ms in the phacoemulsification group. However, comparison of the means shows no statistical difference between the two groups. The low flare readings in the phacofragmentation group were obtained in only 12 patients (75%) because of severe corneal edema or excessive anterior chamber cell activity in the rest of patients. It seems that the difficulty in flare detection was only caused by corneal edema, since the IOP in phacofragmentation group on the first post-operative day was normal (Figure 3).

The flare values on both groups decreased on the subsequent follow-ups, with no statistical difference between the two groups. The flare values returned to pre-operative levels by day 15. This result is different from Chee et al<sup>23</sup> who reported, that flare returning to pre-operative levels within 1 month in the phacoemulsification group. Therefore, the excessive manipulation and a lot of viscoelastic material utilisation in phacofragmentation group did not affect post-operative flare values.

Elevated IOP often occurs in the first post-operative day, even in the absence of a history of glaucoma or physical abnormalities on examination. Outflow through the trabecular meshwork may be decreased in the early post-operative period because of inflammatory cells, blood, fibrin, viscoelastic material and lens or iris debris.<sup>17,24</sup> The incidence of elevated IOP on the first post-operative day has been reported as high as 30% after ECCE and 8% after phacoemulsification, though most cases spontaneously resolve in the first few days. Topical steroids maybe also helpful in suppressing the release of inflammatory cells into the aqueous.<sup>17</sup>

This study reveals a relative stable and normal IOP value on both groups for all follow-up schedules, which was indicated by univariate analysis showing no statistical difference between two groups (Figure 4). The greater amount of viscoelastic material used in the phacofragmentation group which might increase IOP on the first post-operative day, did not appears in this study. It may be caused by a complete evacuation of viscoelastic material by the surgeon, and the utilisation of cohesive viscoelastic material which may be aspirated easier and completely.

The SIA in both groups was also comparable, and decreased on the next follow-up schedule. The axis

component tends into “with the rule” direction on the two groups. Akura et al<sup>20</sup> reported that mean SIA was 1.07 D in 1<sup>st</sup> week and 0.92 in 6<sup>th</sup> month post-operatively, and 96% of the cases showed some reduction in astigmatism post-operatively. Carmona<sup>7</sup> also reported that the post-operative astigmatism decreased progressively over time and with the rule axis component is related to the incision at 12 o'clock.

The excessive manipulation and a lot of viscoelastic material utilisation in phacofragmentation group seemed only affect the visual acuity and corneal thickness on the first post-operative day, but did not affect the flare values and the IOP. Bivariate and multivariate analyses show that only the pachy values give the high contribution for the visual acuity variable.

Statistical analysis demonstrates that the differences of both techniques only occur until the first post-operative day. The differences were in UCVA results which were caused by the change in corneal thickness.

In conclusion, this study shows that both phacofragmentation and phacoemulsification techniques produce indifference results with respect to effectiveness and safety.

Hence, phacofragmentation can be considered as an alternative for mature cataract since it does not have a higher complication rate. The benefits of phacofragmentation can be obtained by using few instruments and relatively cheaper viscoelastic material. So it is less expensive for surgeons who could not acquire costly phacoemulsification equipment. Moreover, phacofragmentation is easier to perform as planned ECCE and can serve as an intermediate step for surgeons who wish to convert to phacoemulsification.

Finally, phacofragmentation is an economical and viable technique that can be recommended as a safe and equivalent alternative to phacoemulsification, particularly in eyes with hard and dense cataracts, as commonly seen in the developing countries.

## REFERENCES

- Chakrabarti A, Singh S, Krishnadas R. Phacoemulsification in eyes with white cataract. *J Cataract Refract Surg* 2000; 26: 1041-7.
- Vasavada A, Singh R, Desai J. Phacoemulsification of white mature cataracts. *J Cataract Refract Surg* 1998; 24: 270-7.
- Brazitikos PD, Tsinopoulos IT, Papadopoulos NT, Fotiadis K, Stangos NT. Ultrasonographic classification and phacoemulsification of white senile cataracts. *Ophthalmology* 1999; 106: 2178-83.
- Kimura H, Kuroda S, Mizoguchi N, Terauchi H, Matsumura M, Nagata M. Extracapsular cataract extraction with a sutureless incision for dense cataract. *J Cataract Refract Surg* 1999; 25: 1275-9.
- Linebarger EJ, Hardten DR, Shah GK, Lindstrom RL. Phacoemulsification and modern cataract surgery. *Surv Ophthalmol* 1999; 44: 123-47.
- Sacca SC, Patrone G, Macri A, Rolando M. Small incision nucleus capture: Results of 200 cases. *J Cataract Refract Surg* 1999; 25: 969-74.
- Carmona FJ. Manual multi-phacofragmentation through a 3.2 mm clear corneal incision. *J Cataract Refract Surg* 2000; 26: 1523-8.
- Vajpayee RB, Sabarwal S, Sharma N, Angra SK. Phacofracture versus phacoemulsification in eyes with age-related cataract. *J Cataract Refract Surg* 1998; 24: 1252-5.
- Hepsen IF, Cekic O, Bayramlar H, Totan Y. Small incision extracapsular cataract surgery with manual phacotrisection. *J Cataract Refract Surg* 2000; 26: 1048-51.
- Duch Mestres F, Matheu A, Torres F. Intraoperative complications of planned extracapsular cataract extraction versus manual nucleofragmentation. *J Cataract Refract Surg* 1996; 22: 1113-5.
- Boyd BF. The small incision phaco section planned extracapsular manual technique. In: Boyd BF. *Highlights of Ophthalmology*. Panama: Highlights of Ophthalmology Int'l; 1997.p.15-24.
- Bartov E, Isakov I, Rock T. Nucleus fragmentation in a scleral pocket for small incision extracapsular cataract extraction. *J Cataract Refract Surg* 1998; 24: 160-5.
- Akura J, Kaneda S, Ishihara M, Matsuura K. Quarters extraction technique for manual phaco-fragmentation. *J Cataract Refract Surg* 2000; 26: 1281-7.
- Olsen T, Johansen MD. Evaluating surgically induced astigmatism. *J Cataract Refract Surg* 1994; 20: 517-22.
- Bayramlar H, Cekic O, Totan Y. Manual tunnel incision extracapsular cataract extraction using the sandwich technique. *J Cataract Refract Surg* 1999; 25: 312-5.
- Berger RR. Manual Nucleofragmentation. *J Cataract Refract Surg* 1997; 23: 148-9.
- Mamalis N. Inflammation. In: Charlton JF, Weinstein GW eds. *Ophthalmic surgery complications. Prevention and management*. Philadelphia: J.B. Lippincott Company; 1995.p. 313-38.
- Kruger A, Schauersberger J, Findl O, Petternel V, Svolba G, Amon M. Postoperative inflammation after clear corneal and sclerocorneal incisions. *J Cataract Refract Surg* 1998; 24: 524-8.
- American Academy of Ophthalmology Staff. Iris-ciliary body. In: Denny M, Taylor F eds. *Fundamentals and principles of ophthalmology. Basic and Clinical Science Course. Section 2*. San Francisco: American Academy of Ophthalmology; 1997.p. 316-24.
- Akura J, Kaneda S, Hatta S, Matsuura K. Manual sutureless cataract surgery using a claw vectis. *J Cataract Refract Surg* 2000; 26: 491-6.



21. Matheu A, Castilla M, Duch F, Marti M, Lillo J, Gill M. Manual nucleofragmentation and endothelial cell loss. *J Cataract Refract Surg* 1997; 23: 995-9.
22. Singh R, Vasavada AR, Janaswamy G. Phacoemulsification of brun`escent and black catarats. *J Cataract Refract Surg* 2001; 27: 1762-9.
23. Chee SP, Ti SE, Sivakumar M, Tan DTH. Postoperative inflammation: Extracapsular cataract extraction versus phacoemulsification. *J Cataract Refract Surg* 1999; 25: 1280-5.
24. Alio JL, Sayans JA, Chipont E. Flare-cell meter measurement of inflammation after uneventfull cataract surgery with intraocular lens implantation. *J Cataract Refract Surg* 1997; 23: 935-9.