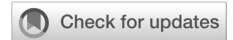

## Nine-segment laminectomy is safe for the resection of a schwannoma extending from C-2 to T-3: a rare case report

Mohamad Saekhu,<sup>1</sup> Nuryati Chairani Siregar,<sup>2</sup> Kevin Gunawan,<sup>1</sup> Setyo Widi Nugroho<sup>1</sup>



pISSN: 0853-1773 • eISSN: 2252-8083  
<https://doi.org/10.13181/mji.cr.192844>  
**Med J Indones.** 2020;29:326–31

**Received:** August 08, 2018

**Accepted:** December 11, 2019

### Authors' affiliations:

<sup>1</sup>Department of Neurosurgery, Faculty of Medicine, Universitas Indonesia, Cipto Mangunkusumo Hospital, Jakarta, Indonesia, <sup>2</sup>Department of Anatomical Pathology, Faculty of Medicine, Universitas Indonesia, Cipto Mangunkusumo Hospital, Jakarta, Indonesia

### Corresponding author:

Mohamad Saekhu  
 Department of Neurosurgery, Faculty of Medicine, Universitas Indonesia, Cipto Mangunkusumo Hospital, Jalan Pangeran Diponegoro No. 71, Kenari, Senen, Central Jakarta 10430, DKI Jakarta, Indonesia  
 Tel/Fax: +62-21-3145554  
**E-mail:** m.saekhu@ui.ac.id/  
 saekhu2010@hotmail.com

### ABSTRACT

Cervical spine schwannoma, which is long and entirely intracanal, is rare to be found. Its rarity and atypical feature leads to difficulty in diagnosing and managing cases because of the scarcity of available literature. The surgical removal of this type of schwannomas via multisegment laminectomy is a great challenge because of various risks of postoperative complications. This report describes cervical spine schwannoma that was initially was not suspected as schwannoma and was subject to surgical removal via nine-segment laminectomy. In one year after surgery, motor function returned to normal strength, no new neurological deficits occurred, and no kyphotic deformity, which is a common complication of multisegment laminectomy.

**KEYWORDS** kyphosis, laminectomy, schwannoma

Spinal schwannoma originates from Schwann cells in the spinal nerve root and grows along the affected nerve.<sup>1</sup> In the cervical spine (C-spine), intradural nerve roots are short, and they immediately enter the intervertebral foramen. Therefore, schwannomas in the C-spine tend to be dumbbell-shaped tumors. Schwannomas that are entirely in the intraspinal canal of the C-spine and extending by more than three vertebral segments are rare entities. However, the incidence and prevalence of C-spine schwannomas with a length of more than nine spinal segments are unknown. To date, only three reports have presented spinal schwannomas with more than

nine spinal segments affected with each report only describing one case.<sup>2-4</sup>

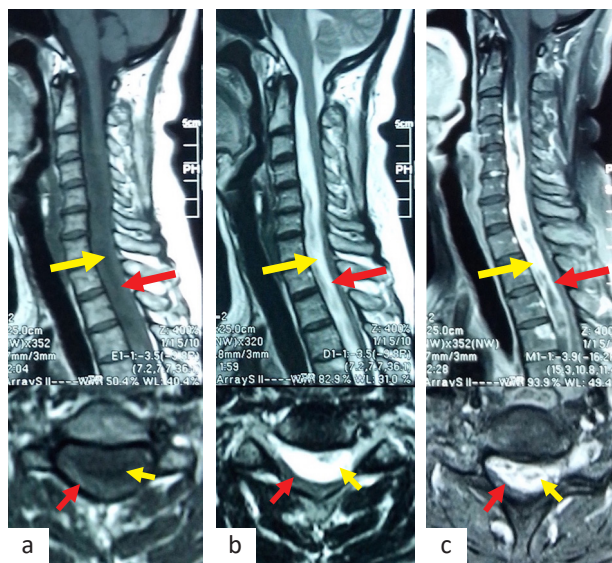
The rarity of this case and studies discussing it, leads to difficulty in its diagnosis and management. The resection of long tumors in the cervicothoracic spine and significant compression to the spinal cord with multisegment laminectomy remains challenging because of various risks of postsurgical complications.<sup>2,5,6</sup> This report shows a case of a spinal schwannoma which covered nine vertebral levels. We also described the challenges in establishing the diagnosis and selection of a safe and effective surgical technique with one year of follow-up after surgery.

Copyright © 2020 Authors. This is an open access article distributed under the terms of the Creative Commons Attribution-NonCommercial 4.0 International License (<http://creativecommons.org/licenses/by-nc/4.0/>), which permits unrestricted non-commercial use, distribution, and reproduction in any medium, provided the original author and source are properly cited. For commercial use of this work, please see our terms at <https://mji.ui.ac.id/journal/index.php/mji/copyright>.

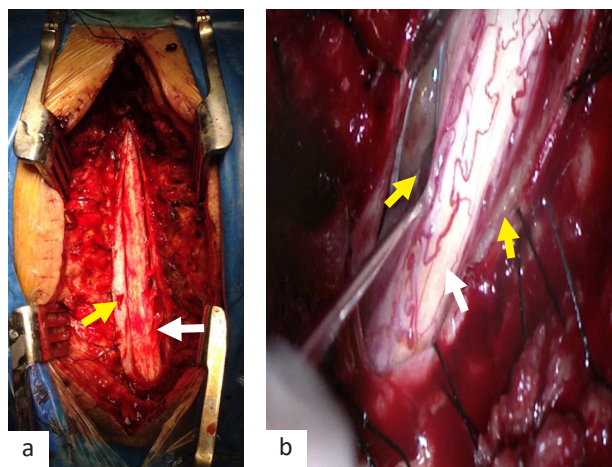
### CASE REPORT

A 53-year-old woman, who gave consent to demonstrate her case, presented with an inability to walk without assistance and preceded by radicular neck pain and progressive weakness of the upper and lower extremities for the last 9 months. Physical examination showed the weakness on both sides of the arms and legs with a motor strength of 3 (motor strength ranges from 0 to 5; 0 is complete paralysis, and the normal motor strength is 5), numbness below bilateral clavicles matching with the hypoesthesia below C4 dermatome. Hyperreflexia and Babinski sign were also found on the legs that signified an upper motor lesions. The Nurick grade was 4, and the Japanese Orthopedic Association (JOA) score was 9. The radiologist suspected abscess or malignancy as shown by the magnetic resonance imaging (MRI) result (Figure 1). Laboratory blood tests showed an increase in the erythrocyte sedimentation rate (ESR) (64 mm) and lactate dehydrogenase (LDH) concentration (269 u/l). Lumbar puncture showed a partial block; the color of the cerebrospinal fluid (CSF) is yellowish (xanthochromia), normally is clear or colorless; cell count was 84 cells/ $\mu$ l, predominated with mononuclear cells; protein was 2,180 mg/dl; Nonne and Pandy test was positive; cytologic examination revealed myeloproliferative lesion; polymerase chain reaction tuberculosis from the CSF and Bence Jones protein was negative. This case was suspected to be a malignancy or abscess as shown by MRI and laboratory test findings.

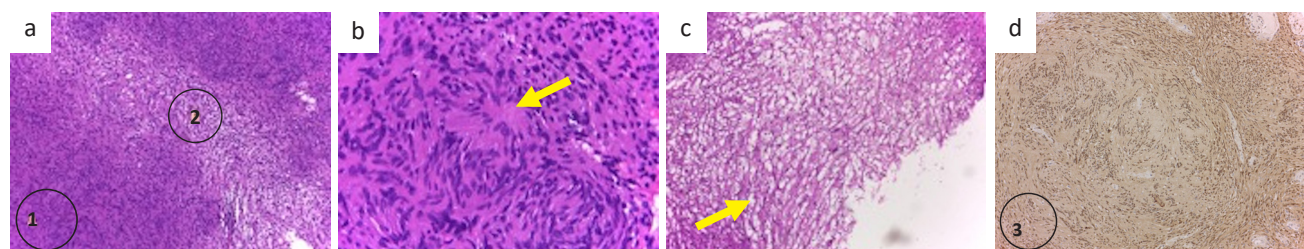
Surgery was carried out in two stages. The first stage of surgery was originally planned only for biopsy. As such, the surgical procedure was removing the lower part of the right-side lamina cervical 4 (laminotomy), along with small skin incision and muscle dissections in the level of the



**Figure 1.** Magnetic resonance imaging (MRI) of the cervical spine demonstrating a long heterogeneously enhancing mass lesion from the C-3 to T-4 spinal cord. Red arrows: spinal cord; yellow arrows: tumor. (a) Iso and hypointense in T1-weighted; (b) hyperintense on the edge/wall of the tumor in T2-weighted; (c) hyperintense on the edge/wall of the tumor in postcontrast T1-weighted



**Figure 2.** (a) Duramater spinalis has opened from C-2 to T-3, showed spinal cord (white arrow), duramater (yellow arrow); (b) microscopic view; the tumors (yellow arrows) is located anterior to the spinal cord (white arrow)



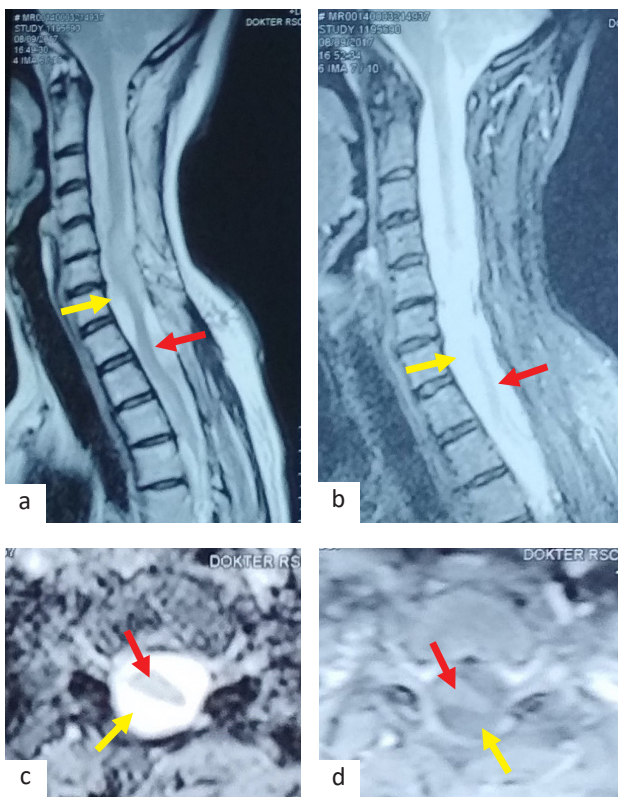
**Figure 3.** Pathologic examination with hematoxylin and eosin (H&E) staining (a–c) (a, 100 $\times$  magnification; b, 400 $\times$  magnification; c, 100 $\times$  magnification) showed a more cellular Antoni 1 pattern (a1) with palisading nuclei surrounding the pink areas (Verocay bodies, yellow arrow) and Antoni 2 pattern (a2) with lesser stroma, fewer cells, and myxoid change with atypical nuclei (c, yellow arrow). Immunohistochemistry assay (d, 100 $\times$  magnification) showed strong S100 positive immunoreactivity in the majority of tumor cells (d3)



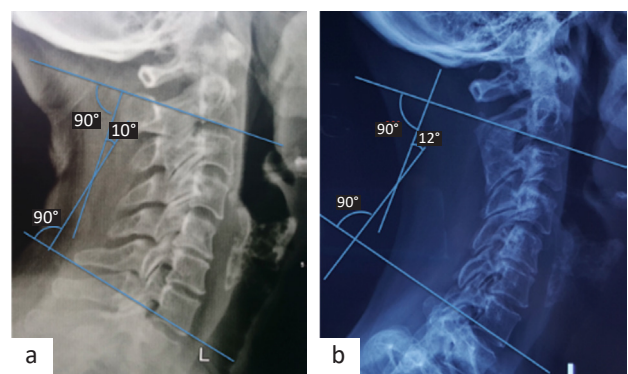
**Table 1.** Clinical and radiological outcomes

Indicator	Follow-up periods			
	Presurgery	3 months	6 months	1 year
Nurick grades	2	3	1	1
JOA scores	11	11	16	16
10-meter walk test (sec)	NA	14	8	6
<b>SF-36</b>				
Physical function	65	70	85	95
Role limitation due to physical health	50	50	75	100
Role limitation due to emotional health	33	33	67	100
Energy	60	60	80	90
Emotional	70	64	88	92
Social functioning	25	50	100	100
Pain	10	68	90	100
General health	40	45	75	90
Cervical lordosis (Cobb's angle)	10°	NA	NA	12°
Tumor resectability	Gross total resection			

JOA=Japanese Orthopedic Association; SF-36=36-item short form health survey; NA=not applicable  
 Nurick grade is a six-grade system from grade 0 to 5 (grade 1 shows no difficulty in walking, grade 2 shows a slight difficulty in walking that does not hinder full-time work, and grade 3 is difficulty in walking that prevents full-time work or the ability to do all household chores, but is not so severe that it requires people's help for walking). The JOA score ranges from 0 to 17 (<12 indicates severe myelopathy, 12–14 indicates moderate myelopathy, ≥15 indicates mild myelopathy). Normal time of 10-meter walk test is ≤13 seconds. A higher score of SF-36 items indicates a better health state.



**Figure 4.** Sagittal T2-weighted magnetic resonance imaging (MRI) showing no evidence of tumor (a and b); the spinal cord was decompressed and placed in the center of the spinal canal after the tumor removal (a, b, c, and d). Red arrows: spinal cord; yellow arrow: cerebrospinal fluid (CSF)



**Figure 5.** Cervical plain radiograph before (a) and 1 year after operation (b) showed the improvement of cervical lordosis. Cobb's angle improved from 10° before operation to 12° after operation

vertebral lamina cervical 4. The duramater was opened approximately 5 mm. After it was opened, a yellowish-gray intradural mass was observed. The mass/tumor was not attached to the duramater and bled easily. A tumor of approximately 5 ml was taken for the frozen section examination, and the result was meningioma. Considering that the frozen section result was not a malignancy or an abscess, we decided to continue the surgery by performing laminectomy from C-3 to T-2 to prepare for the

second-stage surgery. Laminectomy was conducted in conjunction with the maintenance of facet joint integrity.

The second-stage surgery was carried out 2 weeks after the first surgery, the first week after the definitive histopathological result showing schwannomas. In this stage, laminectomy was performed to the lamina C-2 and the lamina T-3 to expose the upper and lower poles of the tumor (Figures 1c and 2a). Midline durotomy was performed from C-2 to T-3. The tumor was exposed after the spinal cord was gently shifted to the right (Figure 2b). Then, the denticulate ligaments in the affected segments were cut so the spinal cord is easily shifted to expand access to the tumor. The tumor was a discrete mass of a yellowish-gray tissue and most of the tumor mass along with a small cystic part was easily suctioned. The tumor bled easily when it was dissected, but the bleeding could be controlled. The gross total resection of the tumor was achieved. The histopathological features (Figure 3) showed schwannomas. Although postoperative instability and kyphotic deformity could occur, external stabilization with a soft neck collar was used instead of rigid internal stabilization for 3 months to obtain a good image when postoperative imaging (MRI) was performed.

Clinical outcomes were assessed 3 months, 6 months, and 1 year after the surgery. The instruments used were Nurick grade, JOA, 10-meter walk test, and 36-item short form health survey (SF-36) (Table 1). MRI examinations and plain cervical spine X-ray was performed at 1 year post-surgery. There were no residual or new tumor growth and kyphotic deformity (Table 1). The patient could normally walk again 1 year after the surgery as measured by the 10-meter walking test, i.e., she could achieve the normal duration (6 sec). No new neurological deficits and no tumors were detected during the MRI examinations (Figure 4). No kyphotic deformity was observed (Figure 5).

## DISCUSSION

A fully intracanal long-sized schwannoma is a rare entity. Initially, we considered either malignancy or abscess for this case. The hallmarks of malignancies and/or spinal abscess were found from the blood and CSF examinations. However, she was finally diagnosed as schwannoma using histopathological examinations; and then it was confirmed by immunohistochemical

(IHC) assay (Figure 3). She was initially diagnosed as meningioma based on the frozen section results. Spinal meningioma usually grows lengthwise and is entirely intradural because the cells are originally from meningothelial (arachnoidal) cells. The previous study showed the accuracy of frozen section in intraoperative diagnosis of central nervous system is high.<sup>7</sup> The discrepancy between frozen section with final diagnosis was approximately 2.7%, but most of these are originated from spindle cells.<sup>8</sup> Both meningioma and schwannoma have spindle cells, therefore it is often difficult to distinguish them using frozen section.<sup>9</sup> To reduce this limitation, there should be a good communication between the surgeon and pathologist and an adequate tumor samplings.<sup>10,11</sup> The classic histopathological feature of schwannoma is the presence of a verocay bodies (Figure 3), but a morphology alone is not sufficient. The diagnosis should be confirmed by IHC assay to differentiate meningioma and schwannoma.<sup>12,13</sup> IHC assay showed strong S100 positive immunoreactivity in the tumor cells, which is a specific marker for schwannoma.<sup>14</sup>

Several findings from blood and CSF examinations showed a malignancy and tumor bleeding and/or a cystic component consisting of necrotic tumor mass that enters the spinal subarachnoid space. An increase of LDH levels in CSF also indicates a malignancy and a presence of hemolysis because of tumor bleeding.<sup>15</sup> Therefore the CSF color becomes xanthochromia (yellowish). On the other hand, an increase of ESR reflecting an infection or an increase of inflammatory response due to blood irritation in the spinal cord and meninges.<sup>16</sup> The tumor bleeding and/or necrotic mass made myeloproliferative cells was available in CSF.

Neurological deficits that develop slowly for 9 months are not a typical of either spinal malignancy or abscess. Previous reports showed intratumoral hemorrhage,<sup>17</sup> subarachnoid hemorrhage,<sup>18</sup> intradural hemorrhage,<sup>19</sup> and necrosis during cell division in tumor growth,<sup>20</sup> hence those patients with spinal schwannoma had acute neurological deficits.

Complete tumor resection is the target of any spinal schwannoma surgery. The preferred surgical procedures are laminoplasty and laminectomy.<sup>21</sup> Laminoplasty is considered safer than laminectomy because it returns the spinal lamina to be an anatomical protector of the spinal cord but is more expensive because it adds implants. Less invasive techniques

with endoscopic or hemilaminectomy approaches are considered safe and effective surgical procedures for small schwannomas.<sup>22,23</sup>

Our case is a giant tumor that extends to nine vertebral segments so it is not suitable for less invasive techniques. The effectiveness and safety of less invasive techniques for long-segment or giant schwannomas remain to be proven. We performed a nine-segment laminectomy instead of laminoplasty as in the previous reports.<sup>2,3,4</sup> Indeed, laminectomy is associated with postoperative deformity and instability.<sup>24,25</sup> However, the study on intradural spinal tumors surgeries showed both laminoplasty and laminectomy provide comparable results in the term of neurological recovery and post-surgical spinal deformity.<sup>26,27</sup> On the other hand, postoperative kyphotic deformity that requiring subsequent surgery, has also occurred by nine-segment laminoplasty.<sup>2</sup> Preservation of the facet joint is one of the tricks to avoid post-laminectomy kyphotic deformity.<sup>28</sup> We showed that the preservation of the facet joint could avoid post-laminectomy deformity (Figure 5) without compromising the gross total resection of the tumor (Figure 4).

The success of certain treatments or surgical procedures can be observed in outcomes. Many measurement tools are used to assess the outcomes of spinal surgery. These tools should not only address local pathologic manifestations but also examine patients' quality of life after treatment.<sup>29</sup> The JOA scale, Nurick grade, SF-36, and walking test are widely used to evaluate.<sup>30</sup> Walking or ambulation after spinal cord dysfunctions can reflect spinal cord recovery. Also, the ability to walk tends to have a better score regarding the quality of life.<sup>31</sup> A 10-meter walk test is a valid and reliable tool to assess the independence level of ambulatory patients.<sup>32</sup> This case showed an improvement in the functional outcomes based on all the measurement tools. The 10-meter walk test and SF-36 revealed that clinical improvement occurred 3 months after surgery. One year after surgery, the MRI showed no residual tumors, and the plain C-spine radiograph indicated no kyphotic deformity as denoted by Cobb's angle measurement. Therefore, multisegment laminectomy with a special attention of facet joint preservation, was safe and effective for the resection of long tumors.

In conclusion, managing a rare case for the first time is a big challenge, both in terms of diagnosis and

choosing the optimal surgical procedure. Nine-segment laminectomy from C-2 to T-3 is safe and can facilitate complete resection of long segment schwannomas without causing post-operative kyphotic deformity.

#### Conflict of Interest

The authors affirm no conflict of interest in this study.

#### Acknowledgment

We would like to thank the medical staff of Department of Neurosurgery, Faculty of Medicine Universitas Indonesia, Cipto Mangunkusumo Hospital, Jakarta, Indonesia.

#### Funding Sources

None.

## REFERENCES

- Jinnai T, Koyama T. Clinical characteristics of spinal nerve sheath tumors: analysis of 149 cases. *Neurosurgery*. 2005;56(3):510–5.
- Kim SH, Doh JW, Yoon SM, Yun IG. Huge schwannoma extended from craniocervical junction to upper thoracic spine. *J Korean Neurosurg Soc*. 2003;34(6):589–92.
- Mahore A, Muzumdar D, Chagla A, Goel A. Pure ventral midline long segment Schwannoma of the cervicodorsal spine: a case report. *Turk Neurosurg*. 2009;19(3):302–5.
- Das JM, Peethambaran A. Total excision of a giant ventral midline cervical spinal intradural schwannoma via posterior approach. *Asian Spine J*. 2016;10(1):153–7.
- Kaptain GJ, Simmons NE, Replogle RE, Pobereskin L. Incidence and outcome of kyphotic deformity following laminectomy for cervical spondylotic myelopathy. *J Neurosurg*. 2000;93(2 suppl):199–204.
- Mehta AI, Adogwa O, Karikari IO, Thompson P, Verla T, Null UT, et al. Anatomical location dictating major surgical complications for intradural extramedullary spinal tumors: a 10-year single-institutional experience. *J Neurosurg Spine*. 2013;19(6):701–7.
- Modi M, Nilkanthe R, Trivedi P, Shah A, Shah J, Chaudhari J. Importance of intraoperative consultation for the diagnosis of central nervous system lesions and evaluation of its diagnostic accuracy. *J Cancer Res Ther*. 2018;14(6):1176–9.
- Plesec TP, Prayson RA. Frozen section discrepancy in the evaluation of central nervous system tumors. *Arch Pathol Lab Med*. 2007;131(10):1532–40.
- Nanarg V, Jacob S, Mahapatra D, Mathew JE. Intraoperative diagnosis of central nervous system lesions: comparison of squash smear, touch imprint, and frozen section. *J Cytol* 2016;32(3):153–8.
- Al-Ajmi R, Al-Kindi H, George M, Thomas K. Correlation of intraoperative frozen section report and histopathological diagnosis of central nervous system tumors - a six-year retrospective study. *Oman Med J*. 2016;31(6):414–20.
- Çakir E, Oran G, Yüksek GE, Ding C, Tihan T. Intraoperative consultations of central nervous system tumors: a review for practicing pathologists and testing of an algorithmic approach. *Turk Patoloji Derg*. 2019;35(3):173–84.
- Gogoi G, Teronpi J, Changsan LL, Saikia P, Borgohain M. A study on schwannomas: morphology alone is insufficient. *J Mol Biomark Diagn*. 2016;7(5):300.
- Jaiswal S. Role of immunohistochemistry in the diagnosis of central nervous system tumors. *Neurol India* 2016;64:502–12.
- Boulagnon-Rombi C, Fleury C, Fichel C, Lefour S, Bressenot AM, Gauchotte G. Immunohistochemical approach to the differential diagnosis of meningiomas and their mimics. *J Neuropathol Exp Neurol*. 2017;76(4):289–98.
- Jialal I, Sokoll LJ. Clinical utility of lactate dehydrogenase: a historical perspective. *Am J Clin Pathol*. 2015;143(2):158–9.

16. Bochen K, Krasowska A, Milaniuk S, Kulczyńska M, Prystupa A, Dzida G. Erythrocyte sedimentation rate – an old marker with new applications. *J Pre Clin Clin Res.* 2011;5(2):50–5.
17. Yeh HM, Leung JH, Huang KC, Tung CL, Huang CL, Huang KM. A long segmental hemorrhagic spinal schwannoma with atypical presentation. *J Radiol Sci.* 2011;36:191–4.
18. Ji C, Ahn JG, Huh HY, Park CK. Cervical schwannoma presenting with acute intracranial subarachnoid hemorrhage. *J Korean Neurosurg Soc.* 2010;47(2):137–9.
19. Sahoo RK, Das PB, Sarangi GS, Mohanty S. Acute hemorrhage within intradural extramedullary schwannoma in cervical spine presenting with quadriplegia. *J Craniovertebr Junction Spine.* 2015;6(2):83–5.
20. Ando K, Imagama S, Ito Z, Kobayashi K, Yagi H, Hida T, et al. How do spinal schwannomas progress? The natural progression of spinal schwannomas on MRI. *J Neurosurg Spine.* 2016;24(1):15–9.
21. Lenzi J, Anichini G, Landi A, Piciocchi A, Passacantilli E, Pedace F, et al. Spinal nerve schwannomas: experience on 367 cases-historic overview on how clinical, radiological, and surgical practices have changed over a course of 60 years. *Neurol Res Int.* 2017;2017:3568359.
22. Zong S, Zeng G, Du L, Fang Y, Gao T, Zhao J. Treatment results in the different surgery of intradural extramedullary tumor of 122 cases. *PLoS One.* 2014;9(11):e111495.
23. Parihar VS, Yadav N, Yadav YR, Ratre S, Bajaj J, Kher Y. Endoscopic management of spinal intradural extramedullary tumors. *J Neurol Surg A Cent Eur Neurosurg.* 2017;78(3):219–26.
24. Sciubba DM, Chaichana KL, Woodworth GF, McGirt MJ, Gokaslan ZL, Jallo GI. Factors associated with cervical instability requiring fusion after cervical laminectomy for intradural tumor resection. *J Neurosurg Spine.* 2008;8(5):413–9.
25. Lu FZ, Zhang F, Xia XL, Ma XS, Wang LX, Jiang JY. Reconstruction to decrease postoperative deformity after cervical benign extramedullary tumor resection. *Int J Clin Exp Med.* 2016;9(4):7234–46.
26. Onyia CU, Menon SK. Laminectomy versus laminoplasty in the surgical management of long-segment intradural spinal tumors: any difference in neurological outcomes? *Asian J Neurosurg.* 2018;13(4):1128–33.
27. McGirt MJ, Garcés-Ambrossi GL, Parker SL, Sciubba DM, Bydon A, Wolinsky JP, et al. Short-term progressive spinal deformity following laminoplasty versus laminectomy for resection of intradural spinal tumors: analysis of 238 patients. *Neurosurgery.* 2010;66(5):1005–12.
28. VanPelt C, Ulibarri JA, Kang JD. Cervical kyphosis following laminectomy: etiology, prevention, and surgical reconstruction. *Semin Spine Surg.* 2006;18(4):202–6.
29. Vavken P, Ganai-Antonio AK, Quidde J, Shen FH, Chapman JR, Samartzis D. Fundamentals of clinical outcomes assessment for spinal disorders: clinical outcome instruments and applications. *Global Spine J.* 2015;5(4):329–38.
30. Zileli M, Maheswari S, Kale SS, Garg K, Menon SK, Parthiban J. Outcome measures and variables affecting prognosis of cervical spondylotic myelopathy: WFNS spine committee recommendations. *Neurospine.* 2019;16(3):435–47.
31. Lam T, Noonan VK, Eng JJ, the SCIRE Research Team. A systematic review of functional ambulation outcome measures in spinal cord injury. *Spinal Cord.* 2008;46(4):246–54.
32. Poncumhak P, Saengsuwan J, Kamruecha W, Amatachaya S. Reliability and validity of three functional tests in ambulatory patients with spinal cord injury. *Spinal Cord.* 2013;51(3):214–7.