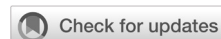

Association between SOX2 and OCT4 expression and the chemoradiation therapeutic response in undifferentiated non-keratinizing nasopharyngeal carcinoma

Lisnawati Rachmadi, Kusmardi, Monik Ediana Miranda, Maria Mayella Vianney



pISSN: 0853-1773 • eISSN: 2252-8083
<https://doi.org/10.13181/mji.0a.203647>
Med J Indones. 2020;29:354–8

Received: March 02, 2019

Accepted: August 21, 2020

Authors' affiliations:

Department of Anatomical Pathology,
 Faculty of Medicine, Universitas
 Indonesia, Cipto Mangunkusumo
 Hospital, Jakarta, Indonesia

Corresponding author:

Lisnawati Rachmadi
 Department of Anatomical Pathology,
 Faculty of Medicine,
 Universitas Indonesia, Cipto
 Mangunkusumo Hospital, Jalan Salemba
 Raya No. 6, Central Jakarta 10430,
 Indonesia
 Tel/Fax: +62-21-80675408
 E-mail: lisnawatidr@gmail.com

ABSTRACT

BACKGROUND Self-renewal ability of cancer stem cells (CSS) is one of the possible causes for nasopharyngeal carcinoma (NPC) to relapse and metastasize. SOX2 and OCT4 are markers for expression of the embryonic stem cells and crucial for the progression of various malignancies. This study was aimed to analyze the association between SOX2 and OCT4 expression and chemoradiation therapeutic response in undifferentiated non-keratinizing NPC.

METHODS This cross-sectional study used archival data from Department of Anatomical Pathology, Faculty of Medicine, Universitas Indonesia, Cipto Mangunkusumo Hospital from January 2014 to December 2016. The outcomes were classified into good-response (complete and partial response) and poor-response groups (progressive and stable disease) based on response evaluation criteria in solid tumors (RECIST). SOX2 and OCT4 immunohistochemistry staining was performed using the initial specimen (before chemoradiation therapy) and positively expressing tumor cells were counted. Staining intensity was graded as: strong, moderate, weak, and negative. Strong and moderate staining was considered positive expression.

RESULTS 33 males and 8 females were included; 48% were ≥ 50 years old. Most of the patients had stage IV ($n = 35$) and several patients had stage II ($n = 3$) and III ($n = 3$). More cells expressed OCT4 in the good-response group than the poor-response group (61.3% versus 37.0%, $p = 0.009$). Meanwhile, there were less cells expressing SOX2 in the good-response group than the poor-response group (36.3% versus 61.1%, $p = 0.097$).

CONCLUSIONS This study suggests that OCT4 is a potential predictive marker for therapeutic response in patients with NPC.

KEYWORDS nasopharyngeal carcinoma, OCT4, SOX2

Nasopharyngeal carcinoma (NPC) is defined as carcinoma derived from the nasopharyngeal epithelium and is the most common head and neck malignancy.^{1,2} According to GLOBOCAN 2018, NPC is the fifth most common malignancy in Indonesia after breast, uterine cervix, lung, and liver cancer. About 17,992 new cases have been reported in Indonesia, of which 13,966 were male cases. In 2017, the World Health Organization (WHO) classified NPC into non-keratinizing squamous cell carcinoma (SCC), keratinizing SCC, and basaloid

SCC. Non-keratinizing SCC is subclassified into differentiated and undifferentiated subtypes.²

There were total of 610 undifferentiated non-keratinizing NPC cases from January 2014 until December 2016 in Department of Anatomical Pathology, Faculty of Medicine, Universitas Indonesia, Cipto Mangunkusumo Hospital. NPC is sensitive to radiotherapy and chemotherapy, but local recurrence and distant metastasis often occur. It is considered that cancer stem cells (CSCs) contributed to this.³ CSCs

are a small subpopulation of the tumor mass that has the ability to self-renew and initiate carcinogenesis. CSCs can escape multiple therapy regimens to reach distant sites; therefore, they have an important role in metastasis in the years after curative surgical therapy of the primary tumor.

Sex determining region Y-related HMG-box 2 (SOX2) and octamer binding transcription factor 4 (OCT4) are embryonic stem cell markers that are important in malignant development of various organs, such as the prostate, lung, brain, large intestine, stomach, and the nasopharynx. SOX2 and OCT4 have important roles regulating pluripotency and self-renewal ability of embryonic stem cells. There were 17.2% of NPC cell nucleus expressing SOX2 and 35.2% expressing OCT4.³ No previous studies have associated NPC with CSC markers in Indonesia. In the present study, we investigated the possible association between SOX2 and OCT4 expression in NPC and the chemoradiation therapeutic response in undifferentiated non-keratinizing NPC.

METHODS

Patients and samples

From all undifferentiated non-keratinizing NPC cases (n = 610) archival data in Department of Anatomical Pathology, Faculty of Medicine, Universitas Indonesia, Cipto Mangunkusumo Hospital from January 2014 until December 2016, only 41 cases have met inclusion and exclusion criteria. Patients with double primary tumors (i.e., with two primary carcinomas in different organs) (n = 7), those who were not treated in this hospital (n = 106), those who had not finished chemoradiation (n = 60), or who had incomplete medical records (no data of therapeutic response [8–12 weeks post-complete treatment] based on computed tomography imaging) (n = 396) were excluded.

Relevant demographic and clinical data were obtained from the patients' medical records. Tumor types and histological grade classifications were designated according to the 2017 WHO classification. Cancer stage was evaluated based on 7th edition of the American Joint Committee on Cancer classification.² This study was approved by the Ethics Committee of the Faculty of Medicine, Universitas Indonesia (No: 0431/UN2.F1/ETIK/2018 and 0404/UN2.F1/ETIK/2018).

SOX2 and OCT4 immunohistochemistry (IHC) staining

Paraffin blocks were sectioned to 4 µm thick, placed on poly-L-lysine layered object glass, and heated to 55–58°C on a hotplate. After deparaffinization in xylol (xylol I–III, 5 min each) and rehydration through an ethanol series (absolute ethanol, 96%, 80%, and 70%, 4 min each), the slides were subjected to heat-induced antigen retrieval using 0.1 M NaOH citrate buffer (pH 7.0) in a 121°C autoclave for 15 min followed by washing in phosphate buffered saline (PBS; pH 7.4) for 5 min. The sections were incubated in 3% hydrogen peroxide for 30 min at room temperature followed by washing in running water for 5 min to block endogenous peroxidase activity. Non-specific protein was blocked using Novolink Protein Block (Novocastra™, RE7102, USA) for 15 min. The sections were incubated overnight at 4°C with primary antibodies to SOX2 H-65 diluted 1:300 (sc-20088, Santa Cruz Biotechnology, USA) and OCT4 diluted 1:100 (Cell Signaling Technology, USA), followed by washing in PBS for 5 min, then a 30 min incubation with biotinylated secondary antibody (Novolink, Novocastra, RE7111). After washing in PBS for 5 min, the sections were incubated with 3,3'-diaminobenzidine substrate for 2 min and washed in deionized and running water for 2 and 10 min respectively. The sections were incubated in Hematoxylin Lillie Mayer for 2 min for nuclear counterstaining, washed in running water for 5 min, soaked in lithium carbonate for 2 min, washed in running water for 5 min, dehydrated with alcohol (80%, 96%, absolute, absolute) for 5 min each, cleared in xylol for 5 min, and mounted. Positive and negative control stains for SOX2 and OCT4 were obtained from normal tonsil tissue and seminoma specimens respectively taken from the archive.

SOX2 and OCT4 expressions evaluation

The result of SOX2 and OCT4 IHC staining were evaluated blindly by three pathologists using the same microscope with a camera attached (Leica DM750, China). The nuclei stained positive for SOX2 and OCT4. Staining intensity was graded as strong, moderate, weak, and negative. Strong and moderate staining were considered positive expression, whereas weak and negative staining were considered negative expression. A total of 500 tumor cells were randomly marked and the proportion of positively stained tumor cells was counted with ImageJ software (National Institutes of Health, USA).

Chemoradiation response

The chemoradiation therapeutic response was evaluated using response evaluation criteria in solid tumors (RECIST), including complete response (disappearance of target lesion), partial response ($\geq 30\%$ decrease in the sum of the longest diameter of the target lesion compared to baseline), progressive disease ($\geq 20\%$ increase in the sum of the longest diameter of the target lesion compared to the smallest sum longest diameter recorded or the appearance of one or more new lesions), and stable disease (neither partial response nor progressive disease).⁴ Patients were categorized into good-response (complete and partial response) and poor-response groups (progressive and stable disease).

Statistical analysis

The data analysis was performed using SPSS software version 20.0 (IBM Corp., USA). The mean difference in SOX2 and OCT4 positive expression was analyzed between the good-response and poor-response groups using the independent t-test. A *p*-value < 0.05 was considered significant.

RESULTS

All of the characteristics are shown in Table 1. The most common clinical symptom was the neck mass (76%), while other symptoms included epistaxis (61%), hearing impairment (59%), tinnitus (54%),

Table 1. Subjects' characteristics

Variable	Total, n (%) (N = 41)	Good-response, n (%) (N = 35)	Poor-response, n (%) (N = 6)
Male gender	33 (80)	28 (68)	5 (12)
Age (years)			
10–19	1 (3)	1 (3)	0 (0)
20–29	4 (10)	4 (10)	0 (0)
30–39	3 (8)	2 (5)	1 (3)
40–49	13 (32)	10 (24)	3 (7)
50–59	10 (24)	9 (21)	1 (3)
>60	10 (24)	9 (21)	1 (3)
Cancer stage*			
II	3 (8)	2 (5)	1 (3)
III	3 (8)	3 (8)	0 (0)
IVA	18 (44)	14 (34)	4 (10)
IVB	7 (17)	6 (14)	1 (3)
IVC	10 (24)	10 (24)	0 (0)

*Based on 7th edition of the American Joint Committee on Cancer classification

double vision (51%), headache (46%), nasal obstruction (32%), dysphagia (24%), facial numbness (24%), visual impairment (22%), hoarseness (20%), impaired consciousness (17%), and facial nerve paralysis (15%).

Positive SOX2 and OCT4 staining was mainly localized to the nucleus of all tumor areas. SOX2 and OCT4 staining intensity varied among samples and among different areas within the same paraffin block

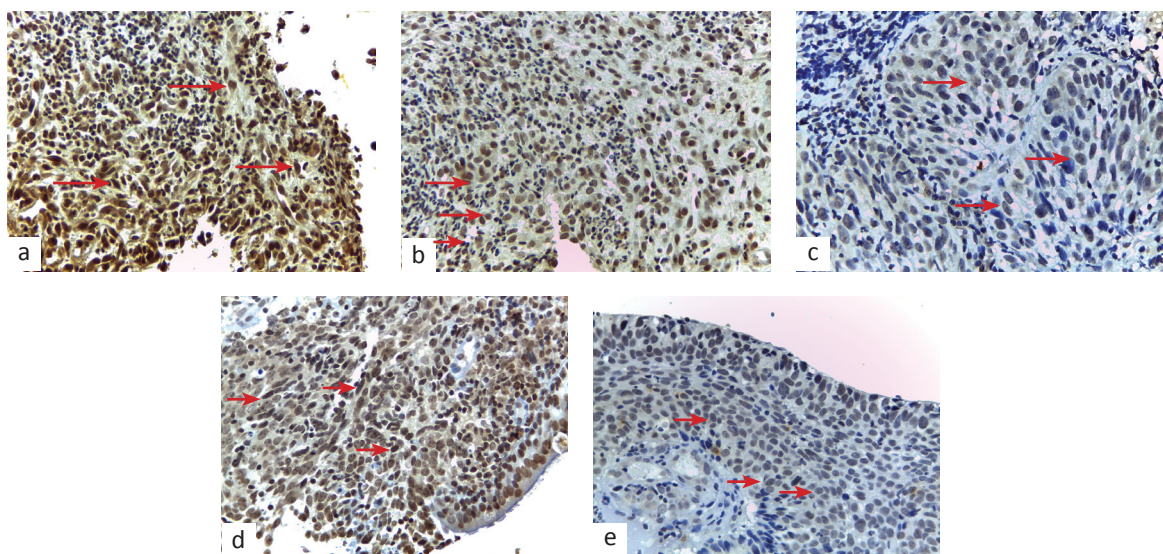


Figure 1. (a) OCT4 stained strongly in the nucleus (arrow); (b) OCT4 stained moderately in the nucleus (arrow); (c) OCT4 stained weakly in the nucleus (arrow); (d) SOX2 stained strongly in the nucleus (arrow); (e) SOX2 stained low to moderate positive in the nucleus (arrow). Magnification 400 \times . OCT4=octamer binding transcription factor 4; SOX2=sex determining region Y-related HMG-box2

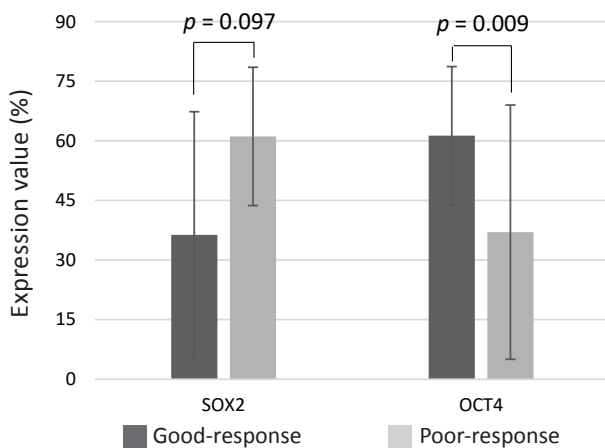


Figure 2. The mean (SD) SOX2 and OCT4 positive expression value in the good-response and poor-response groups. Mean difference of cells with positive expression of SOX2 was -24.8 (95% CI = -54.3-4.7). Mean difference of cells with positive expression of OCT4 was 24.3% (95% CI = 6.5-42.0). SD=standard deviation; SOX2=sex determining region Y-related HMG-box2; OCT4=octamer binding transcription factor 4; CI=confidence interval

(Figure 1a-e). The mean cells with positive expression of SOX2 and OCT4 in good-response and poor-response group were shown in Figure 2.

DISCUSSION

In our study, more cells expressing OCT4 in the good-response group than poor-response group, and only three of six poor-response cases had high expression of OCT4. Ge et al⁵ and Fu et al⁶ reported higher OCT4 expression associated with early stage, smaller tumor size, absence of lymph node metastasis, better prognosis, longer survival, and lower recurrence rate in patients with oral SCC. Singh et al⁷ also reported that only 2% of oral SCC tumor cells positively expressing OCT4. Petersen et al⁸ reported a similar result in glioblastoma. No significant association has been observed between increased OCT4 expression and the survival rate in glioblastoma patients.⁸

This study also showed a male to female ratio of 4:1. Male predominance has been reported in many studies, such as Adham et al¹ and Luo et al.³ Eighteen of 41 cases were diagnosed in the advanced stage.

Positive OCT4 staining was mainly localized in the nucleus and was observed in cancer cells. Ge et al⁵ and Petersen et al⁸ also reported that OCT4 staining was predominantly localized in tumor nuclei in hypopharyngeal SCC and glioblastoma, although weak

cytoplasmic staining was detected.^{5,8} The human OCT4 gene encodes two variants known as OCT4A and OCT4B. Importantly, only the OCT4A isoform sustains stem cell properties and is located in the nucleus, whereas the OCT4B isoform does not possess stem cell properties and is located in the cytoplasm.⁹ In this study, staining intensity varied considerably among samples and among different regions within the same paraffin block. Luo et al³ reported that strong nuclear OCT4 staining was mostly found at the tumor invasive front compared with the tumor center. In our study, nuclear OCT4 staining was detected in all tumor areas. The same result was reported by Ge et al⁵ in hypopharyngeal SCC.

SOX2 is well-known as an embryonic stem cell marker but there are ongoing studies on the role of SOX2 as a CSC marker. When tumor cells have stem cell properties, tumorigenesis increases and is the predicted cause of therapeutic resistance. Luo et al³ and Dong et al¹⁰ demonstrated that high SOX2 expression is closely associated with aggressive tumor behavior in NPC patients, while Bayo et al¹¹ reported that a decrease and loss of SOX2 expression were causes of a worse prognosis. In a later study, decreased SOX2 expression was correlated with a SOX2 mutation, resulted in inhibition of the vimentin pathway.¹¹

In this study, no significant mean difference was observed in cells expressing SOX2 between both groups. Luo et al³ reported that high SOX2 expression was not associated with poor survival.⁶ Whether increased SOX2 expression represents a CSC marker is controversial. Tam and Ng¹² and Rizzino and Wuebben¹³ suggested using other CSC markers, such as OCT4 and Nanog, for the final conclusion.

In multivariate analyses, Luo et al³ reported that high OCT4 expression but not that of SOX2 is associated with poor survival and has strong independent prognostic effects. Nuclear and invasive front OCT4 expression was correlated significantly among tumors with higher TNM classification and cancer stage.³ Qiao et al¹⁴ reported significant OCT4 and SOX2 co-expression at oral SCC primary sites and metastatic sites. Co-expression was also found in transforming oral epithelium in rat samples. These data suggest that these oral mucosa epithelial cells were in the early stage of carcinogenesis; therefore, the SOX2 and OCT4 positive profile should reflect the carcinomatous changes in the epithelial cells.¹⁴ Qiao

et al¹⁴ suggested that an OCT4 and SOX2 positive profile is a biomarker of stem cells that drives epithelial cells to oral SCC. Both Luo et al³ and Ge et al⁵ suggested that OCT4 expression is an independent predictor for patients with nasopharyngeal and hypopharyngeal SCC.

One study showed that endogenous OCT4 levels >150% or <50% serve as a trigger for the differentiation of somatic lineages, indicating that OCT4 acts differently at lower or higher levels.¹⁵ Recent experiments indicate that endogenous OCT4 expression levels of 50–150% in embryonic stem cells are important for self-renewal and maintenance of totipotency. However, upregulation of OCT4 causes stem cells to express genes involved in differentiation of primitive endoderm.¹⁵

Luo et al³ reported the importance of finding CSCs in the peripheral tumor area and the possibility of a tumor niche. Huch and Rawlins¹⁶ proposed that stem cells generate their own niche during homeostasis, and that these coexist in a dynamic equilibrium similar to the situation in a tumor. Unfortunately, the tumor niche was not evaluated in this study, as most of the specimens were fragmented. There were no whole thickness tissue available to be included as sample. Luo et al³ reported higher positive OCT4 expression at tumor invasive front compared to the central part. This statement cannot be proven in our study. Proper tissue sampling and a good pre-analytical process are necessary to gain further information about the tumor niche and CSC distribution. Moreover, there were only limited number of cases due to incomplete medical records. In conclusion, this study suggests that higher numbers of cells expressing OCT4 in good-response group of chemoradiation among subjects with undifferentiated non-keratinizing NPC.

Conflict of Interest

The authors affirm no conflict of interest in this study.

Acknowledgment

We express our gratitude to Universitas Indonesia who funded this research through *Hibah Publikasi Ilmiah Terindeks Tugas Akhir* (PITTA) and Cipto Mangunkusumo Hospital's medical record who provided data for this research.

Funding Sources

This study was funded by *Hibah Publikasi Ilmiah Terindeks Tugas Akhir* (PITTA).

REFERENCES

1. Adham M, Kurniawan AN, Muhtadi AI, Roezin A, Hermani B, Gondhowiardjo S, et al. Nasopharyngeal carcinoma in Indonesia: epidemiology, incidence, signs, and symptoms at presentation. *Chin J Cancer*. 2012;31(4):185–96.
2. Bell D, Petersson BF, El-Mofty SK, Gillison M, Lewis JS, Nadal A, et al. Tumors of the nasopharynx. In: Chan JKC, El-Naggar AK, Grandis JR, Takata T, Slootweg PJ. WHO classification of head and neck tumours. 4th ed. Lyon: IARC; 2017. p. 63–76.
3. Luo W, Li S, Peng B, Ye Y, Deng X, Yao K. Embryonic stem cells markers SOX2, OCT4 and Nanog expression and their correlations with epithelial-mesenchymal transition in nasopharyngeal carcinoma. *PLoS One*. 2013;8(2):e56324.
4. Eisenhauer EA, Therasse P, Bogaerts J, Schwartz LH, Sargent D, Ford R, et al. New response evaluation criteria in solid tumours: revised recist guideline (version 1.1). *Eur J Cancer*. 2009;45(2):228–47.
5. Ge N, Lin HX, Xiao XS, Guo L, Xu HM, Wang X, et al. Prognostic significance of Oct4 and Sox2 expression in hypopharyngeal squamous cell carcinoma. *J Transl Med*. 2010;8:94.
6. Fu TY, Hsieh IC, Cheng JT, Tsai MH, Hou YY, Lee JH, et al. Association of OCT4, SOX2, and NANOG expression with oral squamous cell carcinoma progression. *J Oral Pathol Med*. 2016;45(2):89–95.
7. Singh A, Srivastava AN, Akhtar S, Siddiqui MH, Singh P, Kumar V. Correlation of CD133 and Oct-4 expression with clinicopathological and demographic parameters in oral squamous cell carcinoma patients. *Natl J Maxillofac Surg*. 2018;9(1):8–13.
8. Petersen JK, Jensen P, Sørensen MD, Kristensen BW. Expression and prognostic value of Oct-4 in astrocytic brain tumors. *PLoS One*. 2016;11(12):e0169129.
9. Reers S, Pfannerstill AC, Maushagen R, Pries R, Wollenberg B. Stem cell profiling in head and neck cancer reveals an Oct-4 expressing subpopulation with properties of chemoresistance. *Oral Oncol*. 2014;50(3):155–62.
10. Dong Z, Liu G, Huang B, Sun J, Wu D. Prognostic significance of SOX2 in head and neck cancer: a meta-analysis. *Int J Clin Exp Med*. 2014;7(12):5010–20.
11. Bayo P, Jou A, Stenzinger A, Shao C, Gross M, Jensen A, et al. Loss of SOX2 expression induces cell motility via vimentin up-regulation and is an unfavorable risk factor for survival of head and neck squamous cell carcinoma. *Mol Oncol*. 2015;9(8):1704–19.
12. Tam WL, Ng HH. Sox2: masterminding the root of cancer. *Cancer Cell*. 2014;26(1):3–5.
13. Rizzino A, Wuebben EL. Sox2/Oct4: a delicately balanced partnership in pluripotent stem cells and embryogenesis. *Biochim Biophys Acta*. 2016;1859(6):780–91.
14. Qiao B, He B, Cai J, Yang W. The expression profile of Oct4 and Sox2 in the carcinogenesis of oral mucosa. *Int J Clin Exp Pathol*. 2014;7(1):28–37.
15. Stewart CL. Oct-4, scene 1: the drama of mouse development. *Nat Genet*. 2000;24(4):328–30.
16. Huch M, Rawlins EL. Cancer: tumours build their niche. *Nature*. 2017;545(7654):292–3.