

## Efficacy of adjuvant intrastromal and combination of intrastromal and intracameral voriconazole in *Aspergillus fumigatus*-induced moderate fungal keratitis in rabbits

Dyah Tjintya Sarika,<sup>1</sup> Melva Louisa,<sup>2</sup> Anna Rozaliyani,<sup>3</sup> Evelina,<sup>4</sup> Made Susiyanti<sup>1</sup>



pISSN: 0853-1773 • eISSN: 2252-8083  
<https://doi.org/10.13181/mji.oa.203726>  
**Med J Indones.** 2021;30:13–9

**Received:** April 22, 2019

**Accepted:** October 26, 2020

### Authors' affiliations:

<sup>1</sup>Department of Ophthalmology, Faculty of Medicine, Universitas Indonesia, Jakarta, Indonesia, <sup>2</sup>Department of Clinical Pharmacology, Faculty of Medicine, Universitas Indonesia, Jakarta, Indonesia, <sup>3</sup>Department of Parasitology, Faculty of Medicine, Universitas Indonesia, Jakarta, Indonesia, <sup>4</sup>Department of Anatomical Pathology, Faculty of Medicine, Universitas Indonesia, Jakarta, Indonesia

### Corresponding author:

Made Susiyanti

Department of Ophthalmology, Faculty of Medicine, Universitas Indonesia, Cipto Mangunkusumo Kirana Hospital, Jalan Kimia No 8–10, Pegangsaan, Menteng, Central Jakarta 10320, DKI Jakarta, Indonesia

Tel/Fax: +62-21-31902885

E-mail: madesusiyanti@yahoo.com

### ABSTRACT

**BACKGROUND** There is no *in vivo* evidence for the effectiveness of adjuvant intrastromal and combination of intrastromal and intracameral voriconazole (VCZ) for treating *Aspergillus fumigatus* keratitis. This study aimed to compare the efficacy of both agents against it.

**METHODS** A randomized, masked, controlled experimental study was conducted on 11 albino New Zealand white rabbits in which moderate fungal keratitis was induced by inoculating spores of *A. fumigatus* to the cornea. The rabbits were allocated into 3 groups: 50 µg/0.1 ml intrastromal VCZ injection, 50 µg/0.1 ml intrastromal and intracameral VCZ injections, and topical VCZ (control). The treatment was given 5 days after inoculation. Epithelial defect, infiltrate size, corneal ulcer depth, and hypopyon were evaluated clinically. Histopathological and mycological examinations were also done 14 days after treatment.

**RESULTS** All rabbits in the adjuvant treatment groups demonstrated a tendency of a better clinical response with decreasing size of epithelial defect ( $p = 0.679$ ) and infiltrate ( $p = 0.755$ ) than in the control group. Direct microscopy, corneal culture, and chop corneal tissue culture were still positive in most of the rabbits from all groups. Histopathological examination showed an increase of inflammatory cells after treatment in all groups, especially in rabbits which were inoculated with *A. fumigatus* spores in both eyes.

**CONCLUSIONS** An adjuvant combination of intrastromal and intracameral VCZ showed a tendency of better clinical response for *A. fumigatus*-induced moderate fungal keratitis in rabbits.

**KEYWORDS** *Aspergillus fumigatus*, fungal keratitis, intrastromal, voriconazole

Fungal keratitis, an acute or chronic inflammation caused by fungal species,<sup>1</sup> is the major cause of corneal blindness worldwide.<sup>2,3</sup> The disease is more prevalent in tropical or subtropical climates and agricultural regions.<sup>4</sup> In Indonesia, the estimated incidence of fungal keratitis is 5.3 per 100,000 populations with *Aspergillus fumigatus* being the most common etiology of corneal ulcer.<sup>5</sup>

Fungal keratitis can be diagnosed by clinical feature identification and some ancillary tests. It frequently manifests as a satellite infiltrate, inflammations in the anterior chamber, endothelial plaque, and/or

hypopyon. The ancillary tests which are commonly performed are a direct examination with 10% potassium hydroxide (KOH) and Sabouraud dextrose agar (SDA) tissue culture.<sup>6,7</sup> Once diagnosis has been made, fungal keratitis should be treated directly to prevent its destructive complications.<sup>3</sup>

Although many antifungal agents are available, treatment with these agents may not be adequate because of the limitations of their spectrum/activity, lack of penetration into the eye, and toxicity of the corneal surface.<sup>8</sup> Different classes of antifungals including polyenes and azoles have been used

previously for treating fungal keratitis. Polyenes has some limitations compared to azoles.<sup>8</sup> Voriconazole (VCZ) is the newest triazole that have a broader spectrum of activity and belongs to the second generation of triazole class, which selectively inhibits the fungal cytochrome P450-dependent enzyme sterol 14- $\alpha$  demethylase by interrupting an essential step in ergosterol biosynthesis.<sup>9</sup> Although VCZ has many excellent clinical properties for treating fungal keratitis, there are still limitations in maintaining effective drug concentrations on corneal lesions in moderate to severe fungal keratitis; therefore, intracameral and intrastromal VCZ injections are advised as adjunctive therapy for treating moderate to severe fungal keratitis.<sup>9,10</sup>

Intrastromal VCZ injection had been performed in an experimental study in the rabbit by Park et al.<sup>9</sup> They reported that injection with a dose of 50  $\mu\text{g}/0.1$  ml was proven to be safe because of its minimal toxicity to endothelial cells produced. Previous studies have demonstrated the effectiveness of adjuvant intrastromal and intracameral VCZ injections for treating fungal keratitis. Meanwhile, the effectiveness of adjuvant intrastromal, compared to combination of intrastromal and intracameral VCZ injections, is still unknown. Therefore, this study aimed to demonstrate the efficacy of adjuvant intrastromal and combination with intracameral VCZ injections for treating moderate fungal keratitis caused by *A. fumigatus* in a rabbit model.

## METHODS

This was a randomized, masked (the researchers and observers were not aware of the identity of the control or variable; the control in this study was the topical VCZ group, and only a third person knew all the data), controlled experimental study using a rabbit model that was conducted from October to November 2016 at the Health Research and Development Institution Animal Laboratory, Jakarta. Ethical approval (No: 870/UN2.F1/ETIK/2016) was obtained from the Ethics Committee of the Faculty of Medicine, Universitas Indonesia.

### Preparations of intrastromal and intracameral antifungal agents

VCZ (VFend®, Pfizer, USA) was reconstituted with 0.9% NaCl to a concentration of 50  $\mu\text{g}/0.1$  ml. The 50

$\mu\text{g}/0.1$  ml concentration was obtained by dissolving 200 mg of VCZ with 19 ml of 0.9% NaCl. Next, 1 cc of this solution was dissolved in 20 ml of 0.9% NaCl to reach a concentration of 50  $\mu\text{g}/0.1$  ml. All preparations were performed under sterile condition to avoid contamination, collected in individual syringes, and masked from researchers at the Central Pharmacy Cipto Mangunkusumo Hospital.

The dose of 50  $\mu\text{g}/0.1$  ml is based on several previous reports: (1) Lekhanont et al<sup>10</sup> reported that intrastromal and intracameral VCZ injection 50  $\mu\text{g}/0.1$  ml given to two patients with a fungal corneal ulcer showed corneal healing after 4 weeks; (2) Haddad and El-Mollayess<sup>11</sup> reported that intrastromal and intracameral VCZ injection 50  $\mu\text{g}/0.1$  ml given to a patient with a fungal corneal ulcer caused by *Acremonium* showed an improvement after 6 weeks; (3) Monika et al<sup>12</sup> reported that the intrastromal VCZ injection 50  $\mu\text{g}/0.1$  ml given to patients with recalcitrant fungal keratitis showed a significant improvement and decrease in the number of patients who will require therapeutic keratoplasty. This result was obtained from 80% of patients after 4 weeks injection.

Sample selection for each group was conducted randomly using the block randomization method. A third person who was not involved in the research conducted a randomization, but the results were concealed.

Based on the existing consensus and the ethical principle (replacement, reduction, and refinement) for experimental studies, the number of samples needed using experimental animal is five for each group. This study included 15 samples from three groups, and two extra samples were added to anticipate drop-out. So, the final total sample was 17.

### Animal model of *A. fumigatus*-induced moderate fungal keratitis

The right eyes of five New Zealand albino rabbits and both eyes of five New Zealand albino rabbits (total of 15 eyes from 10 rabbits) were used in this study. The animals were obtained from the Animal Research Institution, Ciawi, Indonesia with weight between 2.5 and 3.5 kg and age around 4 months. All animals were individually housed in a controlled environment with no restrictions of food and water and treated accordingly to The Association for Research in Vision and Ophthalmology (ARVO) statement for the use of

animal in ophthalmic and vision research. Each rabbit had been declared healthy and free of any ocular abnormalities.

The rabbits' corneas were inoculated with *A. fumigatus*. The *A. fumigatus* isolate used in this study was obtained from the culture collection of the Division of Mycology, Department of Parasitology, Faculty of Medicine, Universitas Indonesia. The isolate was grown on SDA at 25–29°C and was previously proven to be susceptible to VCZ using the disc diffusion method.

All rabbits were anesthetized before inoculation procedure using intramuscular injection of ketamine hydrochloride (50 mg/kg) and xylazine (5 mg/kg). Topical anesthesia used was 0.5% of tetracaine hydrochloride (Cendo Pantocain, Indonesia). Inoculation of the rabbits' cornea was performed by superficial keratectomy of the central epithelial cornea with 30-G needle, and the spores were applied to the center of the cornea. Prednisone acetate eyedrops (Cendo P-pred, Indonesia) were administered hourly for 5 days.

Five days after inoculation, the presence of corneal epithelial defects and infiltrates was determined, and then, corneal smear was obtained, stained with 10% KOH, and evaluated under light microscopy. Corneal scraping was also taken from the edge of the ulcer and inoculated into SDA media. The experimental animals were selected in this study after a direct microscopy and culture examination. Smears and culture from the eyes that showed bacterial contamination were excluded from the study. Intrastromal and intracameral injections were performed using 30-G needle under a microscope magnification by a masked ocular infection and immunology consultant under the supervision of a veterinarian.

### Treatment groups

All 15 eyes from 10 rabbits showed clinical signs of moderate fungal keratitis 5 days after *A. fumigatus* inoculation (9–36 mm epithelial defect size) and were randomly distributed into two treatment groups and one control group. The control group had topical VCZ. The treatment groups had topical VCZ and intrastromal VCZ injection or topical VCZ and intrastromal and intracameral VCZ injections. A trained nonmedical staff member instilled topical VCZ hourly from 8:00 AM to 4:00 PM. Intrastromal

VCZ injection was performed in five spots around the edge of the ulcer using 30-G needle and intracameral VCZ injection in the superotemporal region. Intrastromal and intracameral VCZ injections were administered twice on day-1 and -3 after treatment was started. During the study, two rabbits that were inoculated in both eyes died on day-3 and -5 of follow-up. The first rabbit was treated with topical VCZ in the right eye and topical VCZ and intrastromal VCZ in the left eye. The second rabbit was treated with topical VCZ in both eyes.

### Clinical evaluation

Epithelial defect size, infiltrate, ulcer depth, and hypopyon were evaluated by a masked observer on day-1, -3, -5, -7, -10, -12, and -14 after treatment using a slit-lamp biomicroscope. Ulcer depth was evaluated using the Pfister criteria.<sup>13</sup>

### Histopathological examination

The rabbits were euthanized with an intravenous 50 mg/kg sodium pentobarbital on day-14; afterward, the eyes were enucleated and placed in 10% of buffered formalin as fixation solution for at least 24 hours. The cornea was then divided into two equal parts and embedded in paraffin. The sections were cut in 5 µm depth and stained with hematoxylin and eosin (H&E). Inflammatory changes of the cornea were graded using a light microscope with a histopathological grading scale similar to Lee et al.<sup>14</sup>

### Mycological examination

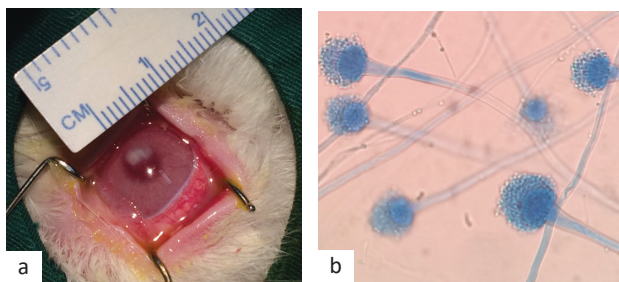
Direct smear examination using 10% of KOH and SDA culture was performed in all eyes on day-14 after treatment. After the eyes were enucleated, the cornea was divided into two equal parts: half of them were used for chopped corneal tissue culture with SDA media, and the rest were used for histopathological examination.

### Statistical analysis

Data were analyzed using SPSS software version 20.0 (IBM Corp., USA). Statistical significance between the three groups was determined using one-way analysis of variance or Kruskal–Wallis tests. Paired t and Wilcoxon tests were used to determine the statistical significance between each group. Categorical variables were not analyzed statistically because of the small sample size.

## RESULTS

Five days after inoculation of *A. fumigatus*, all eyes showed clinical signs of fungal keratitis without any perforation (Figure 1). Of 11 rabbits, 17 eyes (only 1 eye was used for each 5 rabbits) and 1 eye (the right eye of rabbit no. 4) were excluded from analysis because of 50 mm<sup>2</sup> corneal defects. Two rabbits (rabbit no. 4 and 5), which both eyes were inoculated, died on the day-3



**Figure 1.** Clinical feature and laboratory culture findings. (a) Fungal keratitis after inoculation; (b) Sabouraud dextrose agar (SDA) culture revealed a positive result

**Table 1.** Baseline characteristics

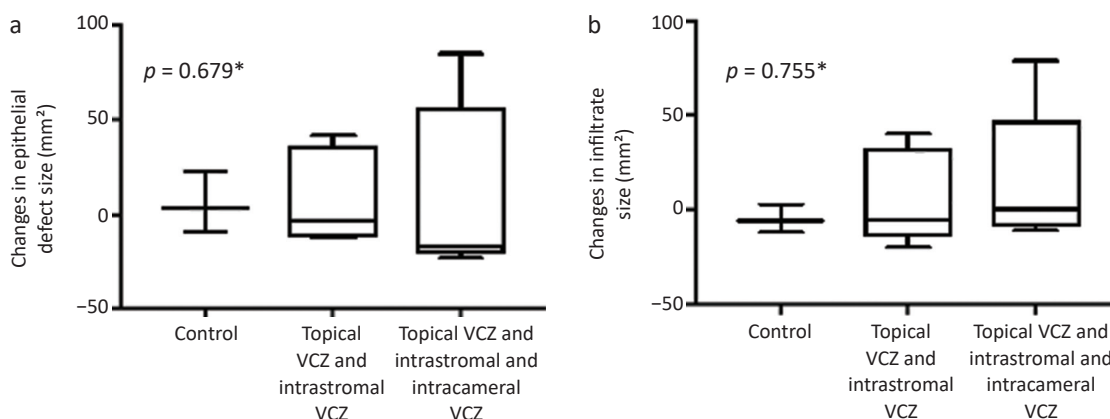
Characteristic	Control	Topical VCZ and intrastromal VCZ	Topical VCZ and intrastromal and intracameral VCZ
Total eyes	6	6	5
Age (months)	4	4	4
Gender	Male	Male	Male
Body weight (g), mean (SD)	3.14 (0.11)	3.15 (0.17)	3.18 (0.15)

SD=standard deviation  
Control: topical voriconazole (VCZ)

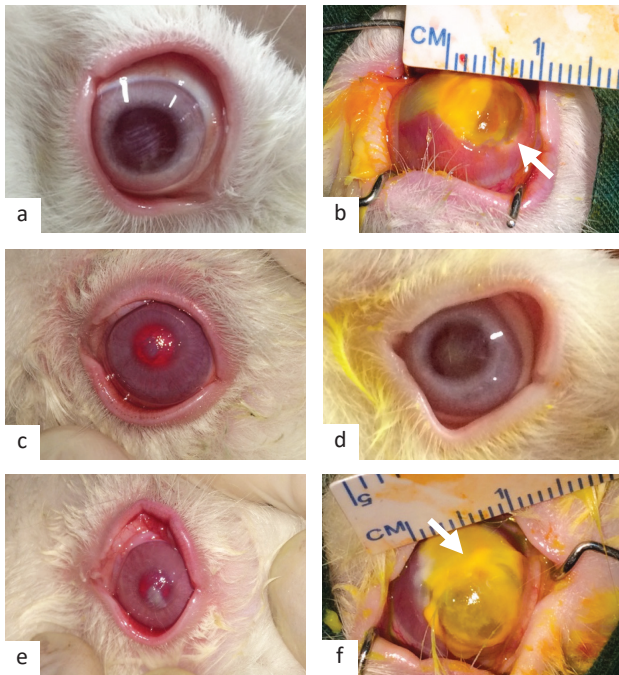
and -5 of evaluation. The total sample analyzed in this study was 13 eyes. Prior to the intervention, all rabbits had similar age, gender, and body weight among three groups (Table 1).

Figure 2a and b, shows no changes in epithelial defect size and infiltrate size between the three groups with  $p = 0.679$  and  $p = 0.755$ , respectively. Most of the eyes in the combination therapy groups showed a clinical improvement after therapy, whereas the control group showed the worst deterioration (Figure 3). The inoculated eyes showed the worst deterioration condition. For the infiltrate size, most of the eyes treated with topical VCZ and intrastromal VCZ and also control group gave clinical improvement, whereas eyes treated with topical VCZ and intrastromal and intracameral VCZ combination gave equal numbers of improvement and deterioration. After 14 days of treatment, only two eyes were found with hypopyon. Figure 3 shows the worst deterioration in most of the eyes in the combination of topical VCZ and intrastromal VCZ and the combination of topical VCZ and intrastromal and intracameral VCZ groups, whereas the control group showed no changes of corneal depth after the treatment.

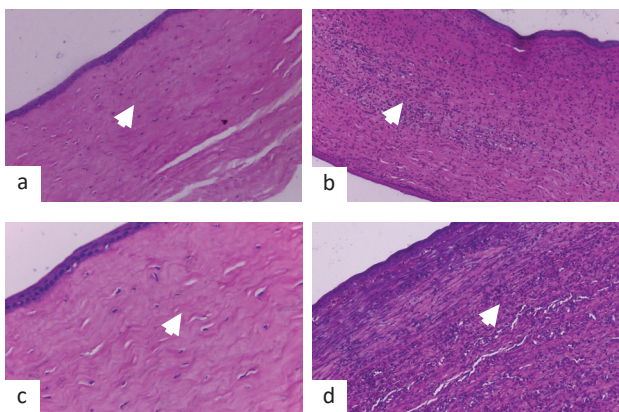
Fungal structures were still detected from all corneal samples using 10% of KOH direct examination, except one eye each from the control and combination of topical VCZ and intrastromal VCZ groups after treatment (Table 2). Fungal culture and chopped corneal tissue culture results were still positive in 85% of the sample (Table 2). All growth was identified as *A. fumigatus*. Statistical analysis from the mycological examination could not be analyzed because of the small sample size.



**Figure 2.** Changes in epithelial defect size (a) and infiltrate size (b) after 14 days of interventions. Control: topical voriconazole (VCZ)  
\*Kruskal–Wallis test



**Figure 3.** Clinical evaluation of rabbits' eyes after treatments in a subject. The control group (a and b) showed deterioration with an increasing corneal defect (arrow) and infiltrate size, descemetocoe, and conjunctivalization. Topical VCZ and intrastromal VCZ (c and d) showed an improvement as corneal defect disappeared and corneal cicatrix was left behind. Topical VCZ and intrastromal and intracameral VCZ (e and f) showed deterioration with an increase of corneal defect (arrow) and infiltrate, descemetocoe, and melting. Control: topical voriconazole (VCZ)



**Figure 4.** Histopathological examination 14 days after treatment. (a) Mild inflammation (arrowhead) in the cornea of rabbit no. 11; (b) severe inflammation (arrowhead) in the cornea of rabbit no. 10 (hematoxylin and eosin [H&E]; original magnification 40 $\times$ ); (c) mild inflammation (arrowhead) in the cornea of rabbit no. 11; and (d) severe inflammation (arrowhead) in the left cornea of rabbit no. 2 (H&E; original magnification 400 $\times$ )

All eyes were enucleated on day-14; half of the cornea was embedded in paraffin and stained with H&E to examine inflammatory changes as a reaction

of corneal damage by using a modification score from Lee et al.<sup>14</sup> Figure 4 shows that most of the eyes from all groups had severe inflammatory reactions, and of more than 3–5 neutrophil cells identified, only two eyes had mild inflammation.

## DISCUSSION

This study showed a better clinical improvement in the adjuvant intrastromal and combination of intrastromal and intracameral VCZ groups compared with that of the control group based on the size of corneal defects. Although the difference was not statistically significant, a clinical improvement was noted in most of the eyes of the adjuvant groups.

We observed that the average corneal defect size between control and treatment groups before therapy was incomparable. The eyes treated with topical VCZ and intrastromal and intracameral VCZ had a large average corneal defect size and more severe conditions than the eyes treated with topical VCZ and intrastromal VCZ and control. Eyes of the rabbits that were inoculated in both eyes suffered the worst condition. Therefore, this could be related to the immune system of the rabbit.<sup>15</sup> In addition, the pharmacokinetics of VCZ were nonlinear, depending on the given dose.<sup>16</sup>

The healing process of corneal defects depends on several factors, including fungi virulence factors, host inflammatory reactions, and host immune system. Virulence factors of fungi were controlled by the species and number of fungi that invade the cornea.<sup>17</sup> Thomas<sup>18</sup> showed that the average healing process of fungal ulcers due to *A. fumigatus* in rabbits is  $21.5 \pm 3.08$  days without perforation with 5% of natamycin therapy,  $27.8 \pm 2.28$  days and one perforation with 0.2% of polyhexamethylene biguanide therapy,  $25.4 \pm 2.57$  days with polyhexamethylene biguanide therapy, and  $36.4 \pm 2.57$  days and three perforations with 1% of povidone iodine therapy. From these previous studies, 14 days might not be sufficient to achieve corneal healing.

The changes in infiltrate size and corneal defects in this study showed similar results. Most of the eyes in adjuvant intrastromal and combination of intrastromal and intracameral VCZ showed a decreased infiltrate size, although it was not statistically significant. Most of the eyes in adjuvant intrastromal and combination of intrastromal and intracameral VCZ groups showed a worse clinical response in corneal infiltrate depth, which possibly

**Table 2.** Corneal smears with 10% of KOH, corneal culture, and chopped corneal tissue culture after treatment

Group	n	Direct examination		SDA culture		Chop corneal tissue culture	
		Positive, n (%)	Negative, n (%)	Positive, n (%)	Negative, n (%)	Positive, n (%)	Negative, n (%)
Control	3	2 (67)	1 (33)	2 (67)	1 (33)	2 (67)	1 (33)
Topical VCZ and intrastromal VCZ	5	4 (80)	1 (20)	4 (80)	1 (20)	4 (80)	1 (20)
Topical VCZ and intrastromal and intracameral VCZ	5	5 (100)	0 (0)	5 (100)	0 (0)	5 (100)	0 (0)
Total	13	11 (85)	2 (15)	11 (85)	2 (15)	11 (85)	2 (15)

SDA=Sabouraud dextrose agar  
Control: topical voriconazole (VCZ)

caused by the inability of the VCZ administration to tolerate the fungal infection growth. This finding was similar with a study by Thomas and Kaliamurthy<sup>19</sup> in treating fungal infections caused by *A. fumigatus* that had a deep infiltrate depth; nearly 60% of patients with such conditions did not respond to medical therapy and thus required surgical therapy.

In mycological examinations, only two eyes from all groups showed negative results in both 10% of KOH examination and chopped corneal tissue cultures. This showed that fungus was still infected and found in the stromal layer of anterior cornea in most of the eyes. It may be happened because the infection in the inoculated eyes was very severe. Hence, the organism was still capable of secreting toxins and protease enzymes that could inhibit epithelial defect closure. The other possibility of this result was the limited follow-up time as it may need longer than 14 days to eradicate the fungus. This result supported by previous study from Bourget et al<sup>20</sup> which showed complete corneal healing process was appeared in 8 weeks after treated fungal keratitis caused by *A. fumigatus* in rabbits with topical terbinafine (an anti-fungal with similar mechanism with VCZ). This may indicate that adjuvant intrastromal or combination of intrastromal and intracameral VCZ that were given for 14 days were not sufficient to eradicate fungal infection on the cornea.

The histopathological findings in this study showed severe inflammation with massive polymorphonuclear infiltration of the cornea in all eyes in topical VCZ and intrastromal and intracameral VCZ, 80% in topical VCZ and intrastromal VCZ, and 67% in control groups. This result demonstrated the severe condition of corneal ulcer after inoculation and the virulence of *A. fumigatus* in severe inflammation.

Clinical evaluation showed a tendency of clinical improvement in the combination of intrastromal and intracameral VCZ group, although not all fungi were able to be eradicated. Therefore, most of the corneal defects have not been completely closed, and the corneal tissue still had inflammation as stated in the mycological and histopathological examination results in most subjects. These may be related to poor fungi elimination, insufficient follow-up time, the rabbit's immune system (both eyes inoculation), and high stress levels along with VCZ nonlinear pharmacokinetics that required a loading dose followed by maintenance dose to maintain its effectiveness.<sup>15,18,19,21</sup>

Adjuvant intrastromal and combination of intrastromal and intracameral VCZ are ineffective in reducing corneal defects, infiltrates, hypopyon, and corneal ulcer depth due to *A. fumigatus*. This condition is related to the severity of corneal inflammation in most of the eyes.

Some limitations of this study include the small animal sample size, which might explain the statistically insignificant results shown in this study. Moreover, the follow-up time was relatively short and potential biases from clinical evaluation that were measured every 2 days could not be demonstrated. Further experimental studies to find the optimal treatment regimen in rabbits that are inoculated only in one eye as stated in the ARVO resolution for the use of animals in ophthalmic and vision research are still required. The similar experimental studies with longer follow-up time and mild and moderate fungal keratitis as an inclusion criteria to assess the effective treatment for fungal keratitis are needed.

In conclusion, both adjuvant intrastromal and combination of intrastromal and intracameral

VCZ groups showed a tendency of better clinical improvement against *A. fumigatus*-induced moderate fungal keratitis.

#### Conflict of Interest

Melva Louisa is the editorial board member but was not involved in the review or decision process of the article.

#### Acknowledgment

None.

#### Funding Sources

None.

## REFERENCES

- Keay LJ, Gower EW, Lovieno A, Oechsler RA, Alfonso EC, Matoba A, et al. Clinical and microbiological characteristics of fungal keratitis in the United States, 2001–2007: a multicenter study. *Ophthalmology*. 2011;118(5):920–6.
- Montgomery ML, Fuller KK. Experimental models for fungal keratitis: an overview of principles and protocols. *Cells*. 2020;9(7):1713.
- Niu L, Liu X, Ma Z, Yin Y, Sun L, Yang L, et al. Fungal keratitis: pathogenesis, diagnosis and prevention. *Microb Pathog*. 2020;138:103802.
- Keay J, Gower EW, Lovieno A, Oechsler RA, Alfonso EC, Matoba A, et al. Clinical and microbiological characteristics of fungal keratitis in the United States, 2001–2007: a multicenter study. *Ophthalmology*. 2011;118(5):920–6.
- Darsini IP, Edwar L. Descriptive study: demographic profile, clinical characteristic, and management of corneal ulcer in Infection Immunology division Cipto Mangunkusumo Kirana hospital from January to December 2013 (Unpublished). Jakarta: Universitas Indonesia; 2015. Indonesian.
- American Academy of Ophthalmology. Infectious diseases/ external eye: microbial and parasitic infections. In: American Academy of Ophthalmology, editors. *External disease and cornea*. San Francisco: American Academy of Ophthalmology; 2014–2015. p. 154–6.
- Kalkanci A, Ozdek S. Ocular fungal infections. *Curr Eye Res*. 2011;36(3):179–89.
- Sharma B, Kataria P, Anand R, Gupta R, Kumar K, Kumar S, et al. Efficacy profile of intracameral amphotericin B. The often forgotten step. *Asia Pac J Ophthalmol*. 2015;4(6):360–6.
- Park CH, Lee HS, Chung SK. Toxicity of intrastromal voriconazole injection on corneal endothelium in rabbits. *Cornea*. 2014;33(9):928–34.
- Lekhanont K, Nonpassopon M, Nimvorapun N, Santanirand P. Treatment with intrastromal and intracameral voriconazole in 2 eyes with *Lasioidiplodia theobromae* keratitis: case reports. *Medicine*. 2015;94(6):e541.
- Haddad RS, El-Mollayess GM. Combination of intracameral and intrastromal voriconazole in the treatment of recalcitrant *Acremonium* fungal keratitis. *Middle East Afr J Ophthalmol*. 2012;19(2):265–8.
- Monika, Chugh JP, Chauhan RS, Rathi A. Role of intrastromal voriconazole in recalcitrant fungal keratitis. *Int J Med Ophthalmol*. 2019;1(2):37–9.
- Pfister RR, Paterson CA, Hayes SA. Topical ascorbate decreases the incidence of corneal ulceration after experimental alkali burns. *Invest Ophthalmol Vis Sci*. 1978;17(10):1019–24.
- Lee SY, Ryu EH, Moon SK, Kim HJ, Woo SY, Cho MS, et al. The efficacy of intravitreal gatifloxacin in experimental *S. epidermidis* endophthalmitis. *J Korean Ophthalmol Soc*. 2008;49(4):651–60.
- Blanco JL, Garcia ME. Immune response to fungal infections. *Vet Immunol Immunopathol*. 2008;125(1–2):47–70.
- Theuretzbacher U, Ihle F, Derendorf H. Pharmacokinetic/ pharmacodynamics profile of voriconazole. *Clin Pharmacokinet*. 2006;45(7):649–63.
- Namrata S, Vajpayee RB, Hugh RT, Peter RL. *Fungal keratitis In: Corneal ulcers: diagnosis and management*. 1st ed. New Delhi: Jaypee Brothers and Medical Publishers; 2008.
- Thomas PA. *Aspergillus keratitis*. In: Pasqualotto AC, editor. *Aspergillosis: from diagnosis to prevention*. India: Springer Science + Business Media; 2010. p. 973–96.
- Thomas PA, Kaliamurthy J. *Mycotic keratitis: epidemiology, diagnosis and management*. *Clin Microbiol Infect*. 2013;19(3):210–20.
- Bourget A, Guyonnet A, Donzel E, Guillot J, Pignon C, Chahory S. Keratomycosis in a pet rabbit (*Oryctolagus cuniculus*) treated with topical 1% terbinafine ointment. *Vet Ophthalmol*. 2016;19(6):504–9.
- Shoham S, Levitz SM. The immune response to fungal infections. *Br J Haematol*. 2005;129(5):569–82.