

## One-sheet spiraling full thickness skin graft for penile resurfacing after paraffinoma excision

Theddeus O.H. Prasetyono

Department of Surgery, Faculty of Medicine Universitas Indonesia/ Cipto Mangunkusumo Hospital, Jakarta, Indonesia

### Abstrak

Praktik salah penyuntikan cairan silikon, parafin, atau beragam minyak lain ke berbagai bagian tubuh, diduga masih terus berlangsung dengan hadirnya pasien-pasien yang meminta pertolongan akibat menjadi korban praktik tersebut. Laporan ini menampilkan 3 kasus kerusakan kulit penis akibat silikonoma yang diterapi dengan eksisi kulit dan rekonstruksi dengan full thickness skin graft (FTSG). Eksisi kulit dilakukan dengan prosedur degloving dan defek yang dihasilkan ditutup dengan selembar FTSG yang diaplikasikan menutupi batang penis secara spiral. FTSG dipilih karena lebih tipis daripada flap dan lebih baik daripada split skin graft dalam hal kontraksi sekunder yang dihasilkan. Teknik aplikasi FTSG secara spiral mudah dikerjakan dan menghasilkan luaran estetik dan fungsi yang baik. Ketiga kasus yang dilaporkan tidak disertai dengan problem parut dan tampak relatif normal. Ketiga pasien menyatakan puas dengan kembalinya fungsi seksual mereka. (*Med J Indones 2011; 20:222-5*)

### Abstract

In the midst of on-going non-illicit practice of silicone or paraffin injection to enlarge penis, the author reported 3 cases of surgical treatment to resurface the body of the penis after excision of the destructed skin using full thickness skin graft. The skin excision was performed technically through penile body degloving procedure. Full thickness skin graft was then applied as a single sheet donor tissue to cover the denuded penile body spirally. The full thickness graft, which is relatively easy to be performed, is no doubt much thinner than a skin flap, while it also bears a smaller degree of secondary contraction than split skin graft. The color of the skin is considerably matched as it comes from the groin, which is a nearby area of penis. The size and skin sensitization of the penis looks to be natural. The only disadvantage is the common possibility of either spiral or circular junctional scar in between graft edges and between the graft and the penile mucosa and skin to develop hypertrophic scar. However, this possible scar problem applies also to any other surgical scar with any donor tissue. Fortunately, the 3 cases posed no scar problem and normal appearance. All the patients have also regained their normal sexual function. (*Med J Indones 2011; 20:222-5*)

**Key words:** full thickness skin graft, paraffinoma, siliconoma, sexual function

A misleading concept of a matter of male sexual organ seems to still exist to the extent of what people percept as “size does matter.” Injecting instant liquid to augment the penis seems to be an easy way to get the wanted results, which many might also want to increase the feelings of the sexual partners. Silicone liquid or mineral oils such as paraffin or vaselin are the common materials widely used in Asia and Europe<sup>1-9</sup> by non-medical personnel or the patient himself. However, instead of getting satisfying results, some had severe reactions and others had an aesthetically poor outcome. Finally, those complications will definitely end up with the inability to perform the sexual activity.

Treatments to such cases may include conservative medications,<sup>1</sup> symptomatic surgical mass reduction with primary suture or Z-plasty,<sup>6,7,9</sup> and radical excision with the need of tissue resurfacing elaborating subsequent flap<sup>6,8</sup> or split thickness skin graft.<sup>6,9</sup> Provided debatable better tissue material for resurfacing and its respective techniques, the author presents 3 cases of full thickness skin graft applied through one sheet spiraling technique.

Correspondence email to: teddyohprasetyono@yahoo.com

## CASE SERIES

### Surgical technique

After deliberately applying a- and antiseptic techniques under regional anesthesia, a tagging suture is placed at the glans to ease the surgery using silk #3-0. The skin and soft tissue of the penile body, which was almost completely involved in the tissue destruction due to mineral oil or silicone injection, is then excised subsequently. The excision is done radically down from the penile-pubic junction proximally to the distal body leaving a half centimeter of mucosal cushion proximal to the corona. The author calls it as a penile body degloving procedure. No tumescent injection or similar hemostatic injection procedure to limit blood loss is needed as the bleeding use to be not exaggerative.

Leaving the denuded penile body under saline soaked gauze, an elliptical designed full thickness skin graft is harvested from either groin. The donor site is closed primarily with intradermal polyglecaprone #3-0. Some subcutaneous sutures using the same material might

be placed as needed in advance before closing it. The penile body is then resurfaced with the skin graft, which is applied spirally as a single graft sheet. Suture material is polypropylene or polyglactin 910 #3-0 connecting the graft to the pubic skin edge, mucosal cushion, and also between the graft at the spiraling meeting line. The graft is also securely attached to the denuded penile body by continuous running suture covering the graft area here and there, and not only the graft edges. (Figure 1) Dressing with tulle grass and moist gauze is then applied. The dressing is kept for a week.

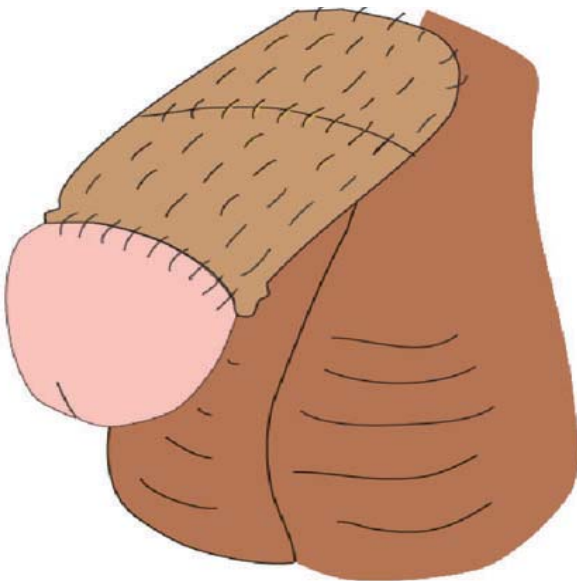


Figure 1. One-sheet full thickness skin graft is applied spirally and also securely attached to the denuded penile body by continuous running suture covering the graft here and there, and not only the graft edges.

### Cases

1. A 30 year-old professional football player walked into the clinic with chief complain pain on erection. He had been away from his sexual activity for 4 months waiting for the healing of his problem. Historically, he had two sessions of silicone injection to augment his penis about 6 months prior to admission. He had no fever, no skin redness on the injected area and no ulceration but bulky penis with blotchy skin appearance. (Figure 2) An unpleasing form of penis was obviously the appearance with firm, palpable masses on the body of the penis. The masses were scattered circularly around the penile body. Surgery has been undertaken to correct the aesthetic performance as well as restore the functional capability using the technique described at the above mentioned. Incision on pubic and scrotal area was performed to excise the silicone-caused fibrotic masses in the respective areas. The healing was noticeably uneventful and nice aesthetic performance and sexual function has been restored at the final follow up of 24 months (Figure 3), except that the patients sometimes suffered severe itching for the first 6 months after the surgery. The itchy area was mainly at the junction between the graft and the mucosa near the corona. (Figure 4) Finally, the patient was fully happy with the result.
2. A 49 year-old businessman had a paraffin liquid injection 5 months prior upon admission. He was suffering from slight skin redness and pain on erection. On the physical examination we found that the skin redness was on the palpable masses on the anterior and posterior area of the penile body. He suffered no ulcerations on the injected area. This patient also underwent a penile body degloving procedure and subsequent penile resurfacing with one-sheet spirally full thickness skin graft. The recovery was eventful. The patient can perform his sexual function normally. The final follow up was 12 months after the surgery.

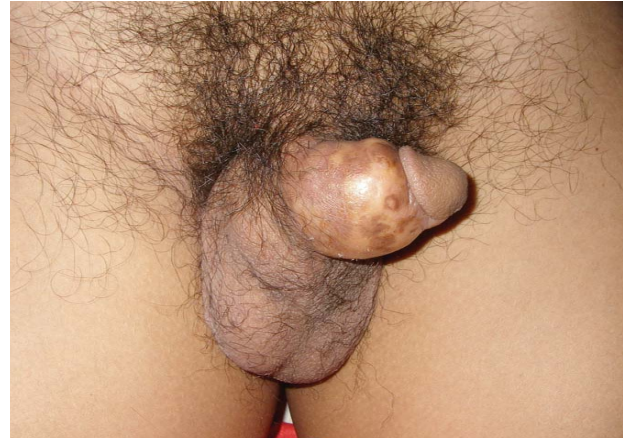

Figure 2. Presentation of penis of case #1, 6 months after silicone injection, with which the patient complained pain on erection. The skin of the penis is inelastic, tender, full and firmer than the normal penile skin.

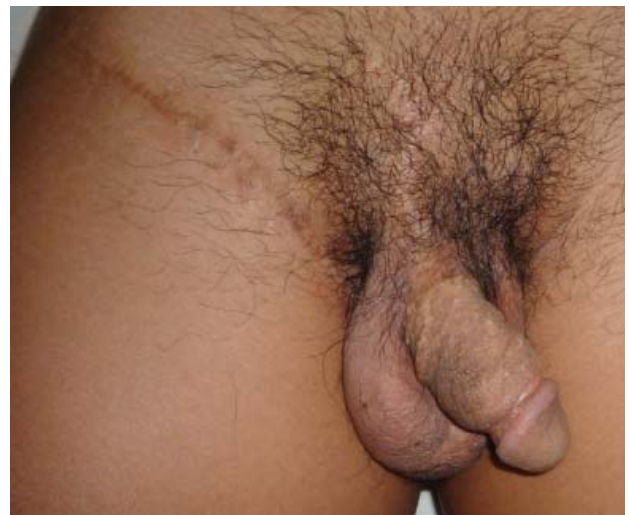

Figure 3. Apparently, the penis looks normal on the photo file taken 2 years after the surgery.

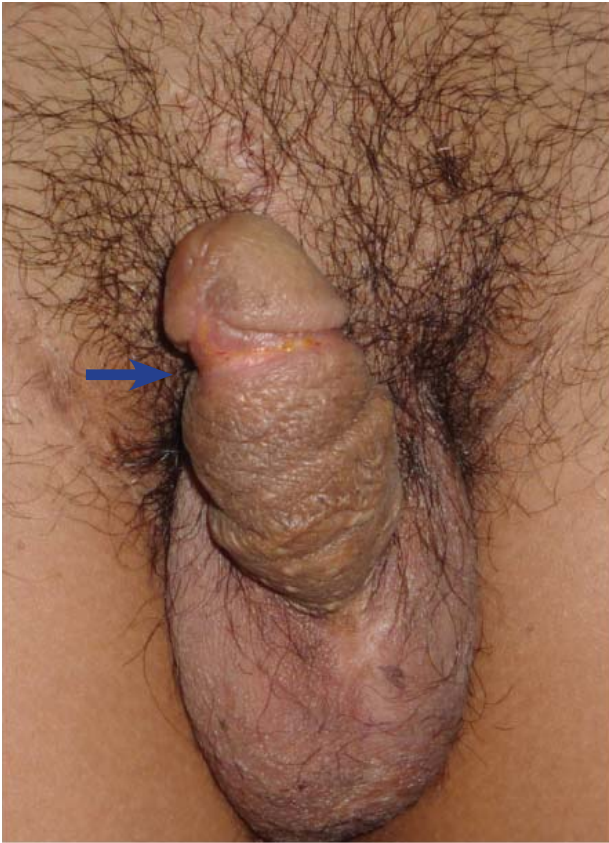

Figure 4. Arrow shows the junction between previously injected silicone bearing mucosa and the skin graft, which appears to be almost normal at 2 years follow up. The injected silicone liquid has been naturally ousted slowly, produced itchy sensation while forming scab.

3. A 50 years old entrepreneur complained of pain during erection. He admitted to have silicone injections 7 months prior to admission. There were palpable masses around his penile body. No skin redness, no ulceration was found. This patient also underwent the degloving of the penile body skin and one-sheet full thickness skin graft resurfacing procedure. The recovery was uneventful without any complication. He had his follow-ups within 14 months while telling his sexual activity has come to normal 6 months afterwards.

## DISCUSSION

Nowadays, silicone injections are unfortunately still widely done amongst those who want to enlarge their penis. As a result after the injections, many suffers from edema, erythema, ulcerations, fistulae, and phimosis.<sup>2</sup> Fourniere's gangrene has also been reported.<sup>2</sup> Other than those complications, a pseudocarcinomatous epithelial hyperplasia was also reported.<sup>3</sup> The base line is that there is no point to get any advantage by having silicone or paraffin injections to the penis.

Methods of treating and correcting the disfigured penile form was also done in many ways such as corticosteroids injections, antibiotics, excisions and flaps.<sup>1,4</sup> There were reports of success using corticosteroid injection for treatment of primary sclerosing lippogranuloma.<sup>2</sup> The radical excision gave the best result and minimal symptoms recurrence,<sup>1,4</sup> with subsequent resurfacing to get close to a normal function and form. A groin and bilateral superomedial thigh flaps, as well as bilateral scrotal flaps have been reported to gave a quite satisfactory result,<sup>5,10</sup> but one must consider the bulky flaps that might hamper the aesthetic and functional result. There was also reports of split thickness skin graft that has been done<sup>2,4</sup> with possible constrain of secondary contraction of the graft. It is indeed difficult to anticipate the secondary contraction after thin split skin graft due to the natural position of the penis. Once contracture takes place, a secondary surgery is inevitably needed.

The one sheet full thickness skin graft may plausibly give a very satisfactory result. There are some advantageous points of concern regarding the use of this single stage technique. First of all, the full thickness graft is no doubt much thinner than a skin flap, while it also bears a smaller degree of secondary contraction than split skin graft. The donor site is less obvious in terms of scar morbidity because it only occupies the groin line. Flaps from thigh and other regional and distant area bear more conspicuous scars, while split skin graft is considerably poses greater area of scarring.

In regards of aesthetic and functional result, full thickness graft possibly also gives better outcomes. The color of the skin is considerably matched as it comes from the surrounding area of penis. The size and skin sensitization of the penis seem to be more natural in comparison with the ones resurfaced with flaps which are mostly bulkier and insensate. The last one to be mentioned is that, technically, the one sheet graft is easy to apply. The only disadvantage of the technique is that the junctional scar line spiraling the body of the penis, which bear the potential of hypertrophic or even keloid. However, scar management is always needed to control every surgical scar, including the techniques elaborating flaps and split skin graft. Fortunately, the author has no scar problems in the three cases reported here.

All of the three patients regained their normal sexual function. There was no significant complains reported on the follow up reviews, except occasional itchy feeling in the patient no 1. This might come from the natural inflammatory response of the body to get rid of the foreign material. The ousted foreign material elicited the formation of scab chronically at the junctional area between the graft and silicone contained mucosa, which subsequently resulting with the itchy sensation.

## Acknowledgments

The author would like to express his thanks to Dr. Steven Narmada for the drawing of figure #1.

## REFERENCES

1. Rosenberg E, Romanovsky I, Asahi M, Kaneti J. Three cases of penile paraffinoma: a conservative approach. *J Urology*. 2007; 70: 372.e9-10.
2. Pehlivanov G, Kavaklieva S, Kazandjieva J, Kapnilov D, Tsankov N. Foreign-body granuloma of the penis in sexually active individuals (penile paraffinoma). *J EADV*. 2008; 22: 845 – 51.
3. Sang W L, Chi Y B, Jeong H K. Penoscrotal reconstruction using groin an bilateral superomedial thigh flaps: a case of penile vaserinoma causing Fournier’s gangrene. *Yonsei Med J*. 2007; 48(4): 723-6.
4. Kokkonouzis I, Antoniou G, Droulias A. Penis deformity after intra-urethral liquid paraffin administration in a young male: a case report. *Cases J*. 2008; 1: 223. Available from: <http://www.casesjournal.com/content/1/1/223>.
5. Magrill D, Shabbir M, Belal M, Cahill D, Hughes B, Corbishley C, et. al. Penile silicone pseudocarcinomatous epithelial hyperplasia; why bigger is not always better. *BMJSU*. 2008; 1: 139 – 41.
6. Lee T, Choi HR, Lee YT, Lee YH. Paraffinoma of the penis. *Yonsei Med J*. 1994; 35(3): 344-8.
7. Santos P, Chaveiro A, Nunes G, Fonseca J, Cardoso J. Penile paraffinoma. *J EADV*. 2003; 17(3): 583-4.
8. Muraro GB, Dami A, Farina U. Paraffinoma of the penis: one stage repair. *Arch Esp Urol*. 1996; 49(6): 648-50.
9. Manny T, Pettus J, Hemal A, Marks M, Mirzazadeh M. Penile sclerosing lipogranulomas and disfigurement from use of “1Super Extenze” among Laotian immigrants. *J Sex Med*. 2010; (Epub ahead of print). Available from: <http://www.ncbi.nlm.nih.gov/pubmed/20722776>
10. Angspatt A, Pungrasmi P, Jindarak S. Bilateral scrotal flap: pedicle and dimension of flap in cadaveric dissections. *J Med Assoc Thai*. 2009; 92(10): 1313-7.