

The application of human umbilical cord blood mononuclear cells in the management of deep partial thickness burn

Yefta Moenadjat,¹ Maurin Merlina,² Camy F. Surjadi,² Caroline T. Sardjono,² Yuyus Kusnadi,² Ferry Sandra²

¹ Burn Unit, Cipto Mangunkusumo Hospital, Jakarta, Indonesia

² Stem Cell Clinical Study Division, Stem Cell & Cancer Institute, PT Kalbe Farma Tbk., Jakarta, Indonesia

Abstrak

Latar belakang: Penyembuhan luka bakar merupakan proses rumit dan penutupan luka sering dihadapkan pada berbagai masalah. Berkembangnya bukti-bukti keberhasilan terapi sel punca pada regenerasi kulit menarik perhatian banyak klinisi yang mengelola kasus luka bakar. Diantara sumber sel punca alogenik yang tersedia, darah tali pusat mudah diperoleh dan tidak dihadapkan pada masalah etik, dan mengandung sel punca multipoten dengan imunogenisitas rendah. Penelitian ini ditujukan untuk evaluasi potensi terapi sel mononuclear darah tali pusat manusia (hUCBMNCs) pada proses re-epitelialisasi luka bakar derajat dua dalam.

Metode: Dua puluh pasien dengan luka bakar derajat dua dalam diberikan 2×10^7 hUCBMNCs secara topikal. Sebagai kontrol, setiap pasien juga menerima olesan silver sulfadiazine (SSD) untuk luka sebanding yang terdapat pada lokasi tubuh lain. Kedua perlakuan diberikan sebanyak enam kali berturut-turut dengan selang waktu satu hari. Luas luka diukur menggunakan Visitrak[®] pada hari ke-0, 7, dan 11. Intensitas nyeri pada pergantian balutan dinilai berdasarkan skala Wong Baker. Dilakukan pemeriksaan histologi pada beberapa sampel biopsi kulit pada luka yang sudah mengalami re-epitelialisasi pasca perlakuan. Dalam evaluasi keamanan terapi, dilakukan pemeriksaan HLA pada beberapa sampel. Kecepatan penyembuhan luka dianalisis dengan uji Wilcoxon Signed Rank.

Hasil: Enam belas pasien menunjukkan penutupan luka lebih cepat secara bermakna pada luka yang mendapatkan hUCBMNCs dibandingkan SSD; pada hari ke-7 ($p = 0,041$) dan 11 ($p = 0,021$). Penurunan intensitas nyeri dijumpai lebih sering pada kelompok perlakuan hUCBMNCs dibandingkan SSD; dari rata-rata skala 3 ke 1/0 pada hari ke-7 dan 11. Tidak ada reaksi alergi, penolakan, dan infeksi yang ditemukan pada studi ini, menunjukkan bahwa terapi hUCBMNCs tergolong aman, meski dijumpai ketidakcocokan HLA. Studi histologi menunjukkan terbentuknya penjururan-pertautan epidermis ke lapis dermis menyerupai konfigurasi kulit normal.

Kesimpulan: hUCBMNCs dinilai aman dan berpotensi dalam re-epitelialisasi luka lebih cepat dan baik pada luka bakar derajat dua dibandingkan dengan terapi konvensional. (*Med J Indones. 2013;22:92-9*)

Abstract

Background: Wound healing in burn is a complex process and early complete wound closure still enfaces many problems. Application of stem cells is found to be the future method of wound healing. Among the available sources of allogenic stem cells, umbilical cord blood is quite easy to be obtained, has less ethical issue, and contain multipotent stem cells, which are characterized by low immunogenicity. The study aims to evaluate the potential of human umbilical cord blood mononuclear cells (hUCBMNCs) treatment in the management of deep partial thickness burns.

Methods: Twenty patients with deep partial thickness burns were treated with topical application of 2×10^7 hUCBMNCs and silver sulfadiazine (SSD) cream on the comparable wound size in the other sites. The treatments were applied for six times in every two consecutive days. Wound surface area was measured with Visitrak[®] on day 0, 7, and 11. Pain intensity was evaluated using Wong Baker's faces scale on each wound dressing change. Histology examination was performed in some samples of collected skin biopsy of the newly re-epithelialized area of hUCBMNCs and SSD-treated wound at the end of treatment. HLA typing is used to evaluate the issue of safety. Wilcoxon signed rank test was used to compare the rate of wound healing.

Results: Sixteen patients of hUCBMNCs-treated showed a significant wound closure in faster than SSD-treated; measured on day 7 ($p = 0.041$) and day 11 ($p = 0.021$). Number of patients with reduced pain intensity, from approximately scale 3 to 1/0 on day 7 and 11, were higher in hUCBMNCs-treated compared to SSD-treated wound. In spite of the HLA-mismatch, no allergic reaction, rejection, and infection found on hUCBMNCs-treated wound suggested the safety of this therapy. Histology examination found the formation of dermal-epidermal junction and rete ridges equal to the normal skin on hUCBMNCs-treated wounds.

Conclusion: hUCBMNCs are effective and safe to promote re-epithelialization in deep partial thickness burns. (*Med J Indones. 2013;22:92-9*)

Keywords: Deep partial thickness burn, mononuclear cells, re-epithelialization, umbilical cord blood

Following exposure to thermal source, disintegration of skin and the tissue beneath leads to circulatory derangement and impaired perfusion to the local traumatized site, which in turn will decrease the capability to provide its normal functions, i.e. control

of evaporation, barrier protection, etc.¹ With this defect, the potential structure of skin territory that is responsible for wound healing is impaired and the sequence of the healing process is consequently prolonged. Along with this prolonged process of healing, unfavorable

scar formation in a later date is the major problem in burns. For such a reason, aggressive effort to obtain on time schedule of wound surface re-epithelialization is one policy in the management of deep partial and full thickness burns, as the structure of skin integuments is damaged and spontaneous re-epithelialization is almost impossible.²

The aggressive wound management in burns includes the concept to remove non-vital tissues such as eschar following resuscitation and after stable hemodynamic condition has been achieved. In standard conventional burn management, topical cream of silver sulfadiazine applied on the wound surface and waited for days to obtain information of wound progress. Afterwards, the clinician decide the method of wound closure, either spontaneous or surgically intervention.³ Mostly, the management of deep partial thickness burns in the hospital unit referred to conservative treatment. In this kind of treatment, a various modern dressings of biological and biosynthetic materials have been applied.⁴

The development of cell-based technology in burn management started as cultured epithelial auto graft (CEA) proposed as the better option to solve the problem in major burns as there is limitation of skin graft donor.^{5,6} Nevertheless, there were disadvantages found with its application in clinical setting;⁷ such conditions has provoked the researchers to find comprehensive and better skin regeneration as well as skin replacement. This was found paralleled to the discovery of stem cells. Following the huge numbers of researches in stem cells following its discovery, it was then found that umbilical cord blood have the potency of renewal or to regenerate certain types of cells, including keratinocytes; both *in vitro*⁸ and *in vivo*.⁹

The goal of this study is to find information of re-epithelialization of applied human umbilical cord blood mononuclear cells (hUCBMNCs) on the deep partial thickness burns, compared to silver sulfadiazine (SSD). The objective is to find the safety and efficacy of hUCBMNCs in treatment of deep partial thickness burns.

METHODS

Study design

This comparative study evaluates the treatment of deep partial thickness burns using hUCBMNCs (Stem Cells Institute, Jakarta, Indonesia) and SSD (Burnazin, Darya-Varya, Jakarta) in enrolled patients who were

admitted to the Burn Unit, Cipto Mangunkusumo Hospital in Jakarta from 2008 to 2009. The study has been approved by the Ethical Committee of Research in Faculty of Medicine, Universitas Indonesia (Ethical Approval no 307/PT2.FK/ETIK/2008).

Patient selection

The subjects were patients with deep partial thickness burn (flame and scald). Patient selection was based on the inclusion criteria, i.e. young adults (age of ≥ 17 years old) with burns less than $\leq 30\%$ of total body surface area. Patients with inhalation injury, chemical, and electric burns and with unstable hemodynamic condition were excluded as well as patients, who had any disease prior to trauma, secondary infection, or history of hypersensitivity to citrate or dimethyl sulfoxide (DMSO) and pregnant women. Two equal wound sizes in different comparable sites in each recruited patient were selected for treatment using hUCBMNCs and SSD.

Preparation of hUCBMNCs

Human umbilical cord blood (hUCB) was obtained by aspiration following delivery through mother's consent, and was processed within 48 hour after collection. From each collected hUCB, aliquots were set apart for bacterial and fungal screening. Human UCB was processed by differential centrifugation (Sepax[®], Biosafe, Eysins, Switzerland) in combination with hydroxyl ethyl starch (HemoHes, B.Braun, Melsungen, Germany) to obtain mononuclear cells. The hUCBMNCs were marked by CD34+ and counted using flow cytometry. Viability was tested by means of trypan blue exclusion method. The hUCBMNCs were kept in cryotubes in the presence of 10% DMSO, placed in controlled rate freezer to reach -80°C and then transferred to -196°C in vaporized liquid nitrogen cryotank. Prior to each clinical application, cryotubes were taken out from the cryotank and thawed in 37°C water bath for 2 minutes. Immediately after thawing the cell suspension was washed with phosphate buffered saline (PBS). Total hUCBMNCs of 2×10^7 with viability of more than 70% were prepared in 1 mL PBS and transported to the burn unit at low temperature ($2-8^{\circ}\text{C}$) for each single application.

HLA typing

DNA from donor and recipient was amplified using HLA typing kit (SSP UniTray kit, Invitrogen[™], Carlsbad, CA) and run for gel electrophoresis. Briefly, DNA was isolated from non-heparinized blood samples and diluted in Tris-EDTA buffer to have 75-125 ng/

μL DNA templates. Polymerase chain reaction (PCR) was carried out in a 96-well polycarbonate PCR tray containing 5 μL /well of optimized HLA allele-specific primer overlaid with paraffin oil. Soon after cycling was completed, the amplicons were loaded onto a 2% agarose gel for electrophoresis. The ethidium bromide-stained gel was photographed and the visible bands were interpreted using software (UniMatch[®] Plus, Invitrogen[™], Carlsbad, CA) to determine the HLA-A, -B, -DR, -DQ types.

Treatment

Two selected wounds from each patient were prepared. After surgically debrided, wound surface area was drawn with red colored permanent ink marker pen in a grid lined of 0.5 cm square sterile plastic transparent sheet. The wounds were covered with nonpetroleum-based tulle (Atrauman[®], Hartmann, Heidenheim, Germany). One mL solution containing hUCBMNCs was topically applied on the wound surface. Accordingly, SSD cream was applied to the other wound surface. The wound was then covered with sterile moist gauze to obtain a suitable wound environment for re-epithelialization. The dressing change as well as the procedure was re-applied for 5 times, every two consecutive days.

Clinical evaluation

Clinical parameters i.e. wound surface area; pain intensity during dressing change, sign of infection, and rejection were subjects to evaluation and recorded. Wound surface area was measured using electronic wound measurement device (Visitrak[®], Smith & Nephew, St. Laurent, Canada) on day 0, 7, and, 11 of application. Decreasing size of wound surface area represented re-epithelialization progress. Pain intensity was measured using Wong Baker's pain intensity scale, which is ranged from 0-5. Bacteriological swab (BBL[™] CultureSwab[™] Plus, Becton Dickinson and Co., Franklin Lakes, NJ) from each treated surface was collected and further microbial test was performed for the presence of aerobic and anaerobic bacteria. Increasing exudates and clinical signs of acute inflammation of surrounding wound was monitored as a parameter of rejection.

Histological examination

Skin biopsy from the hUCBMNCs- and SSD-treated wounds was carried out on the end of the treatment (day 11). The samples were fixed in 4% formaldehyde freshly prepared from paraformaldehyde and prepared for paraffin block. Slices of 4 mm thickness

were mounted on object glass and stained with hematoxylin-eosin.

Statistical analysis

Wound surface re-epithelialization of hUCBMNCs- and SSD-treated on day 7 and 11 were subjected to analysis. For statistical analysis, Wilcoxon Signed Rank test was used, since the data involved 2 groups, related, numerical type, and not normally distributed according to Saphiro-Wilk test. Computation was done using SPSS Statistics 17.0 software; p value of < 0.05 is considered statistically significant.

RESULTS

Twenty patients were enrolled in this study. Two patients were excluded from the trial for self-withdrawal. One patient died before the treatment was completed and another one was excluded from the analysis due to incomplete data. In the end of the study, sixteen cases were analyzed.

Re-epithelialization

As shown in Figure 1, hUCBMNCs treatment results in better progress of wound re-epithelialization (i.e. decreased wound surface area) on day 7 after application compared to SSD treatment. The difference is statistically significant (hUCBMNCs = $77.2\% \pm 28.8\%$, SSD = $56.8\% \pm 47.3\%$; $p = 0.041$). This was consistently observed also on day 11, i.e. at the end of treatment (hUCBMNCs = $89.7\% \pm 23.6\%$, SSD = $78.8\% \pm 28.0\%$; $p = 0.021$).

Issue of pain during dressing change

Pain was the issue in the first day of application (mode = 3, hurts even more). The number of patients feeling 'no hurt' (scale 0) and 'hurts little bit' (scale 1) were noted on day 7 and 11 to compare pain issues between hUCBMNCs- and SSD-treatment. There were more patients with pain relieve on hUCBMNCs-treated compared to SSD-treated wounds (Figure 2).

Rejection and signs of infection

The differences of healing process in wounds treated by hUCBMNCs and SSD were observed. Crust formation was noted in all SSD-treated, but not in hUCBMNCs-treated wounds (Figure 3, arrowed). There was no excessive inflammation clinically observed in hUCBMNCs-treated wounds. Neither immune reaction nor rejection was found in hUCBMNCs-treated wounds.

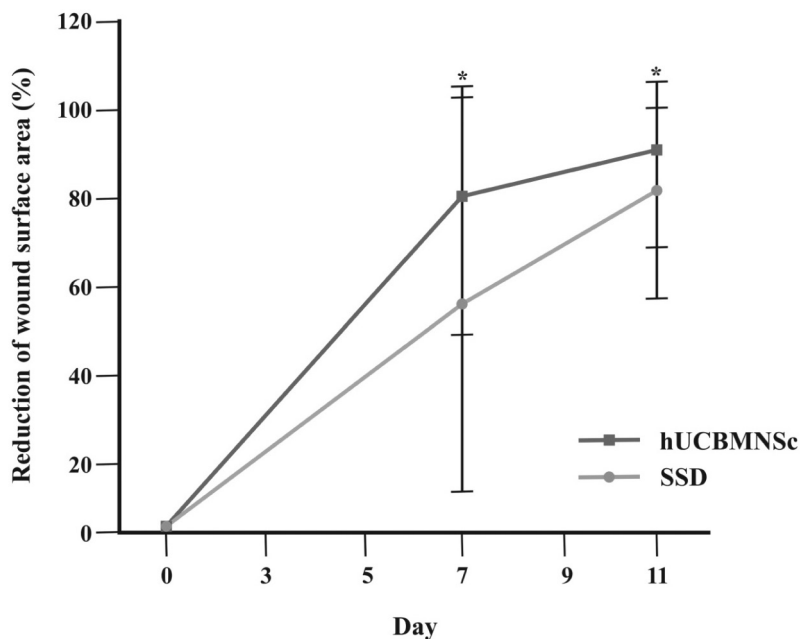


Figure 1. Wound surface area of hUCBMNCs- and SSD-treatment on days 7 and 11. Data represent mean values \pm SD (n = 16)

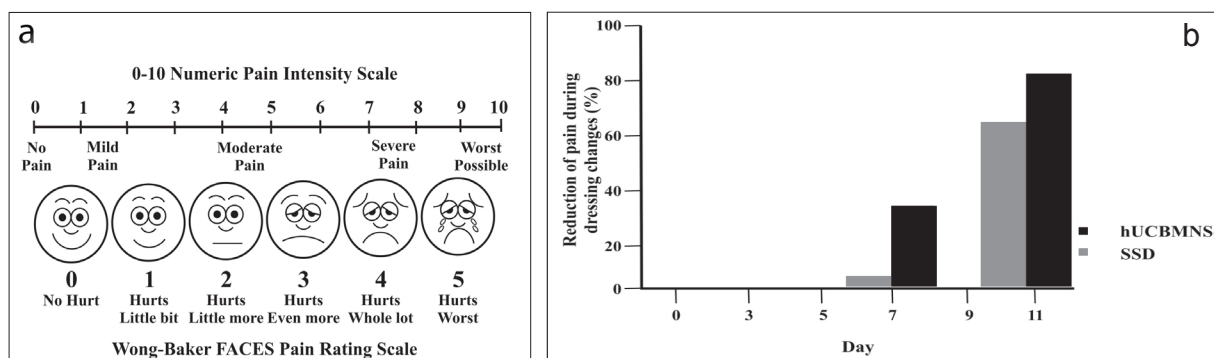


Figure 2. Wong Baker's pain intensity scale (a) and the number of patients (%) with reduced pain intensity (scale 0-10) on days 7 and 11 of treatment (b)

The HLA types in this study represent MHC class I (HLA-A and -B) and MHC class II (HLA-DR and -DQ). Highest matching degree found was 4 of 8 and the lowest matching degree was 1 of 8 (Table 1). However, no GvHD symptom was observed in the patient treated with hUCBMNCs from the donor with the lowest matching degree.

Figure 4 shows histological representation of hematoxylin-eosin-stained samples of hUCBMNCs- and SSD-treatment shows epidermal layers of recovered wounds with objective magnification of 40x and 100x. Dermal-epidermal junction is clearly reconstituted on day 11 in hUCBMNCs treatment and cellular rearrangement of recovered wounds in both of hUCBMNCs and SSD treatment. White bars

(upper panel): 100 mm, black bars (lower panel): 25 mm.

Histological examination

Histology examination on day 11 showed enhanced re-epithelialization, both in SSD- and hUCBMNCs-treated wounds. Human UCBMNCs-treated wounds showed clearly identifiable dermal-epidermal junction with the rete ridges protruding to dermis close to the appearance in normal skin (Figure 4A). SSD-treatment indicated unclear dermal-epidermal junction (Figure 4B). Focused on cellular rearrangement, both treatments indicated similar numbers: 8-13 epidermal layers in hUCBMNCs-treated (Figure 4C) and 8-10 layers in SSD-treated wounds (Figure 4D).

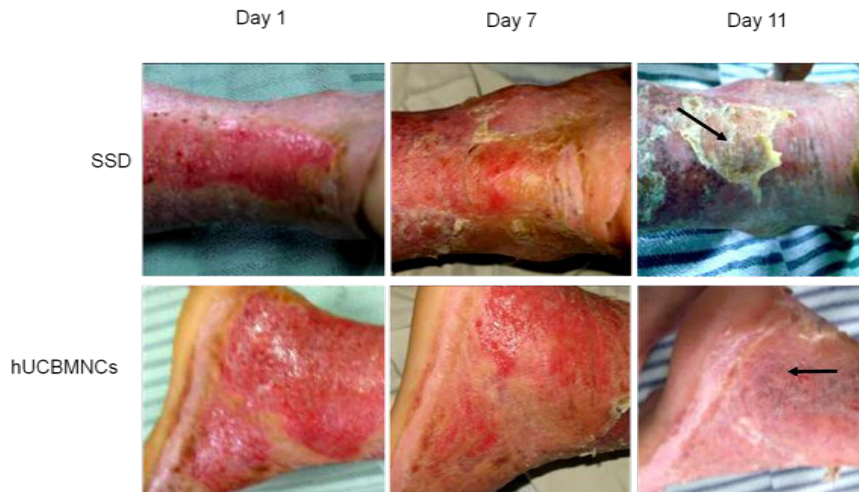


Figure 3. Re-epithelialization of SSD-treated and hUCBMNCs-treated wounds on day 0, 7, and 11. The arrows on day 11 demonstrated the differences of crust formation (in SSD-treatment) and no crust formation (in hUCBMNCs-treatment)

Table 1. Result of HLA typing

Donor – Patient	HLA types				No. of match allele
SCI 42	A*11,11	B*35,40	DRB1*12,12	DQB1*03, 03	3 of 8
Patient 1	A*11,11	B*27,51	DRB1*03,09	DQB1*02, 03	
SCI 42	A*11,11	B*35,40	DRB1*12,12	DQB1*03,03	1 of 8
Patient 2	A*24,33	B*15,40	DRB1*04,15	DQB1*04,06	
SCI 40	A*02,24	B*40,54	DRB1*04,04	DQB1*04,04	2 of 8
Patient 3	A*02,24	B*15,51	DRB1*01,15	DQB1*05,06	
SCI 39	A*26,33	B*08,44	DRB1*03,14	DQB1*02, 05	3 of 8
Patient 5	A*24,33	B*15,44	DRB1*15,16	DQB1*05, 05	
SCI 37	A*02,24	B*35,35	DRB1* 12 ,16	DQB1*03,03	4 of 8
Patient 7	A*02,24	B*35,40	DRB1* 12 ,15	DQB1*05,06	
SCI 33	A*02,24	B*18,18	DRB1*14, 15	DQB1*05,06	4 of 8
Patient 9	A*11,24	B*15,27	DRB1*12, 15	DQB1*05,06	
SCI 32	A*02,33	B*15,58	DRB1*12,15	DQB1*03,06	4 of 8
Patient 10	A*11,11	B*15,18	DRB1*12,15	DQB1*03,05	

DISCUSSION

In this study, hUCBMNCs application is compared to SSD, which is a widely used topical antibiotic for wound care in burn management. Silver sulfadiazine contains silver ions that bind to the microorganisms' nucleic acid releasing sulfadiazine, which then interferes with the microbial metabolic activity.¹⁰ SSD has an excellent broad-spectrum antibacterial coverage against *Pseudomonas aeruginosa* and other Gram-negative enteric bacteria, although some resistance

had been reported.^{11,12} However, systemic toxicity was found in daily topical application, once or twice, indicated by the development of leukopenia.¹³ Since SSD is only absorbed within the surface of epidermal layer, its effectiveness in severe injuries might be limited.¹⁴

Human UCBMNCs used in this study were isolated from crude umbilical cord blood and processed with minimum manipulation (without culture). The term 'mononuclear cells' was used instead of 'stem cells' to

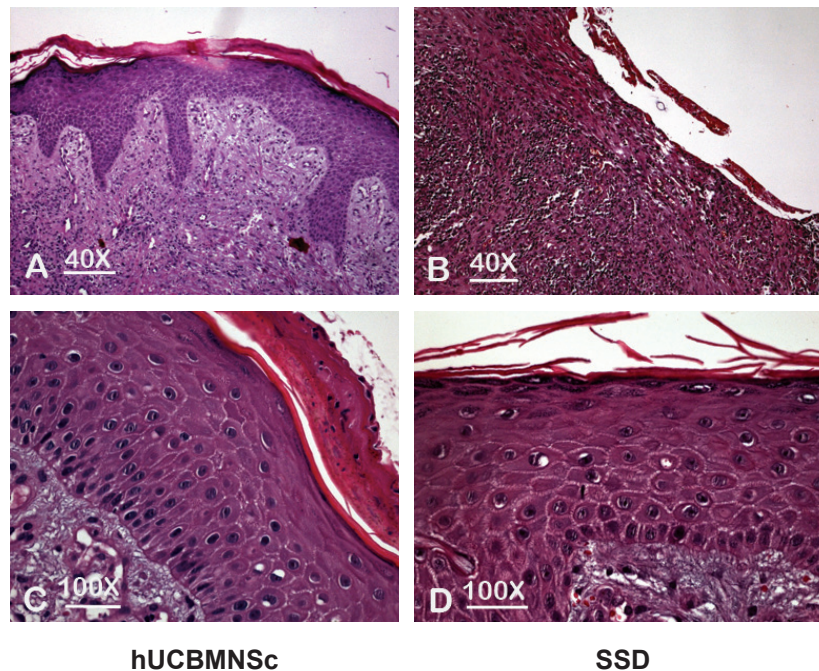


Figure 4. Histological representation of hematoxylin-eosin-stained samples of hUCBMNCs- and SSD-treatment shows epidermal layers of recovered wounds with objective magnification of 40x and 100x. Dermal-epidermal junction is clearly reconstituted on day 11 in hUCBMNCs treatment and cellular rearrangement of recovered wounds in both of hUCBMNCs and SSD treatment. White bars (upper panel): 100 μ m, black bars (lower panel): 25 μ m

avoid misperception, since stem cell characterization and sorting were not performed in this clinical study. However, many studies proved that mononuclear fraction of human umbilical cord blood contain at least two types of stem cells: i.e. hematopoietic and mesenchymal stem cells. Hematopoietic stem cells, characterized by CD34+ markers, were found approximately 1% in the mononuclear cells.¹⁵ Whereas, mesenchymal stem cells, characterized by CD34-, CD45-, CD44+, CD90+, and CD105+ markers, were found in much less amounts in the full-term umbilical cord blood.¹⁶

Regarding the period of wound re-epithelialization, this study showed fascinating result in application both of SSD and hUCBMNCs. Spontaneous re-epithelialization in deep partial thickness burns is normally completed up to 21 days. With conventional treatment of SSD, approximately 80% of wound re-epithelialization was achieved within 11 days. With hUCBMNCs therapy, the achievement of wound re-epithelialization reached approximately 90% of completion. The 10% difference was considered statistically significant.

Pain intensity was evaluated in each dressing change and application procedure. There was a great variation of pain intensity both intra- and inter-individually. It

had been shown that the pain intensity was not related to burn severity, but in the second week most patients of major burns had tendencies to express more pain than those with moderate burns.¹⁷ Based on that study, we compared the pain intensity induced in each application in the first week (day 7) and second week (day 11). We found that more patients felt decreased pain intensity in hUCBMNCs than in SSD treatment on days 7 and 11. Higher percentage on day 11 is consistent with the completeness of wound re-epithelialization. However, in the evaluation of the efficacy, the parameter of pain intensity might be less objective.

HLA typing was carried out to investigate donors-patients matching degree that may have effect on the outcome. It has been suggested that the success of unrelated hematopoietic stem cell transplantation is influenced by the degree of donor HLA compatibility.^{18,19} For these reasons, patients get the greatest benefit when they have HLA-matched donors and can tolerate the transplantation procedure.²⁰ However, this study found no post-transplant complication or graft-versus-host disease (GvHD) even in HLA-mismatch cases. This finding supports studies of unrelated cord blood transplantation indicating immune-tolerance of hUCBMNCs.²¹⁻²³

The absence of GvHD in this allogeneic hUCBMNCs application can be explained by the lack of immunological properties. When compared to adult peripheral blood, T-lymphocytes and dendritic cells in umbilical cord blood are relatively immature as shown by very low expressions of CD4, CD8, and CD3. Minimum expression of those markers yielded very small numbers of IL-2 and IFN- γ that play important roles in inflammatory reactions.^{24,25} The immaturity of T-lymphocytes was explained by little exposure to foreign antigens; as the individual developed, T-cells would differentiate into a memory phenotype as the antigenic exposure gradually increased.²⁶

In terms of quality of re-epithelialization, histology showed better results in hUCBMNCs- than in SSD-treated wounds. Epidermal rete ridges formation was clearly identified in hUCBMNCs on day 11 at the end of treatment, while in spontaneous wound healing this dermal-epidermal junction normally resembles 4 to 6 months following complete re-epithelialization. This long process can be explained by the fact that during skin remodeling, regenerated epithelia are prone to shearing forces, thus the regeneration process may be repeated many times. It seemed that SSD treatment was following the rule of such process and hence, no rete ridges formation was identified yet in the samples. The rete ridges pattern found after 11 days of hUCBMNCs treatment suggests that hUCBMNCs accelerate remodeling.

In conclusion, human UCBMNCs are safe and potential to induce faster and better wound healing than conventional treatment in deep partial thickness burns.

Acknowledgments

We acknowledge and appreciate to Miss Devi Anggraenie and Mr Christian Indra in assistance to hUCB collection, Miss Melina Setiawan in HLA typing and database, dr Budiana, SpPA(K) for histology analysis, and Nursing staff of dr Cipto Mangunkusumo Hospital Burn Unit for the contribution of the entire study. This work was supported by Kalbe Farma Pharmaceutical Company.

REFERENCES

- Benson A, Dickson WA, Boyce DE. Burns. *BMJ*. 2006;332(7542):649-52.
- Hanumadass ML, Ramakrishnan M, Ramakrishnan MK, Babu M. The art and science of burn wound management. Turnbridge Wells, Kent: Anshan; 2005.
- Benson A, Dickson WA, Boyce DE. Burns. *BMJ*. 2006;332(7542):649-52.
- Lineen E, Namias N. Biologic dressing in burns. *J Craniofac Surg*. 2008;19(4):923-8.
- Loss M, Wedler V, Künzi W, Meuli-Simmen C, Meyer VE. Artificial skin, split-thickness autograft and cultured autologous keratinocytes combined to treat a severe burn injury of 93% of TBSA. *Burns* 2000;26(7):644-52.
- Atiyeh BS, Costagliola M. Cultured epithelial autograph (CEA) in burn treatment: Three decades later. *Burns*. 2007;33(4):405-13.
- Caruso DM, Schuh WH, Al-Kasspoole MF, Chen MC, Schiller WR. Cultured composite autografts as coverage for an extensive body surface area burn: Case report and review of the technology. *Burns* 1999;25(8):771-9.
- Kamolz LP, Kolbus A, Wick N, et al. Cultured human epithelium: Human umbilical cord blood stem cells differentiate into keratinocytes under invitro conditions. *Burns* 2006;32(1):16-9.
- Dai Y, Li J, Li J, et al. Skin epithelial cells in mice from umbilical cord mesenchymal stem cells. *Burns* 2007;33(4):418-28.
- Lansdown, AB. Silver: Its antibacterial properties and mechanism of action. *J Wound Care*. 2002;11:125-30.
- Heggers JP, Hawkins H, Edgar P, Villarreal C, Herndon DN. Treatment of infections in burns. In: Herndon DN, editor. Total burn care. London: Saunders; 2002. p.120-69.
- Wright JB, Lam K, Hansen D, Burrell RE. Efficacy of topical silver against fungal burn wound pathogens. *Am J Infect Control*. 1999;27:344-50.
- Choban PS, Marshall WJ. Leukopenia secondary to silver sulfadiazine: Frequency, characteristics and clinical consequences. *Am Surg*. 1987;53:515-7.
- Herruzo-Cabrera R, Garcia-Torres V, Rey-Calero J, Vizcaino-Alcaide MJ. Evaluation of the penetration strength, bactericidal efficacy and spectrum of action of several antimicrobial creams against isolated microorganisms in a burn centre. *Burns* 1992;18:39-44.
- Chularojmontri L, Wattanapittayakul SK. Isolation and characterization of umbilical cord blood hematopoietic stem cells. *J Med Assoc Thai*. 2009;92(Suppl.3):S88-94.
- Yu M, Xiao Z, Shen L, Li L. Mid-trimester fetal blood-derived adherent cells share characteristics similar to mesenchymal stem cells but full-term umbilical cord blood does not. *Br J Haematol*. 2004;124(5):666-75.
- Jonsson CE, Holmsten A, Dahlström L, Jonsson K. Background pain in burn patients: Routine measurement and recording of pain intensity in a burn unit. *Burns* 1998; 24(5):448-54.
- Sasazuki T, Juji T, Morishima Y, et al. Effect of matching class I HLA alleles on clinical outcome after transplantation of hematopoietic stem cells from an unrelated donor. *N Engl J Med*. 1998;339:1177-85.
- Anasetti C, Amos D, Beatty PG, et al. Effect of HLA compatibility on engraftment of bone marrow transplants in patients with leukemia or lymphoma. *N Eng J Med*. 1989;320:197-204.
- Morishima Y, Sasazuki T, Inoko H, et al. The clinical significance of human leukocyte antigen (HLA) allele compatibility in patients receiving a marrow transplant from serologically HLA-A, HLA-B, and HLA-DR matched unrelated donors. *Blood* 2002;99:4200-6.
- Rocha V, Wagner Jr. JE, Sobocinski KA, et al. Graft-versus-host disease in children who have received a cord-blood or

- bone marrow transplant from an HLA identical sibling. *N Engl J Med.* 2000;342(25):1846-54.
22. Kurtzberg J, Laughlin M, Graham ML, et al. Placental blood as a source of hematopoietic stem cells for transplantation into unrelated recipients. *N Engl J Med.* 1996;335:157-66.
 23. Laughlin MJ, Baker J, Bambach B, et al. Hematopoietic engraftment and survival in adult recipients of umbilical-cord blood from unrelated donors. *N Engl J Med.* 2001;344:1815-22.
 24. Barker JN. 2007. Umbilical cord blood (UCB) transplantation: An alternative to the use of unrelated volunteer donors. *Hematol Am Soc Hematol Educ Progr.* 2007;1:55-61.
 25. Heng T, Dudakov J, Khong D, Chidgey A, Boyd R. Stem cells meet immunity. *J Mol Med.* 2009;87:1061-9.
 26. Gluckman E, Rocha V. Cord blood transplantation: State of the art. *Haematologica* 2009;94(4):451-4.