

Post-irradiation osteosarcoma : A case report

Errol U. Hutagalung*, Achmad Basuki*, R. Susworo^f

Abstrak

Terapi radiasi dapat mengakibatkan terjadi proses keganasan di kemudian hari. Dilaporkan satu kasus osteosarkoma sekunder pada klavikula akibat radiasi 16 tahun sebelumnya.

Abstract

Radiotherapy can induce a malignancy at a latter time. A case of secondary osteosarcoma in the clavicle caused by radiotherapy 16 years earlier is reported.

Keywords: Osteosarcoma, radiotherapy

The carcinogenic effect of radiation is a well-known fact. Radiotherapy is used in the management of cancer, and at a latter time may contribute to the development of a secondary malignancy which differ from the primary one.

The frequency of malignancy attributed to radiation is very low preceded by a long latent period, so that the incidence is usually published as case reports.¹ Here we present a case of osteosarcoma of the clavicle, secondary to radiotherapy administered for a malignancy in the nasopharyngeal area, 16 years before.

CASE REPORT

A 50-years-old woman was hospitalized for a lump on the left clavicular bone since 7 months. Previous history of trauma and infection were denied.

She became aware of the lump at the medial clavicle when it was thumb-sized, which continued to enlarge. Throughout this period she continued to lose weight. Sixteen years earlier she underwent radiotherapy

which amounted to 5500 cGy for a nasopharyngeal cancer.

Physical examination revealed a lump measuring 8 x 5 x 3 cm at the upper left hemithorax, which was bluish red in color and showed bleeding areas. It had a granular surface, hard in consistency, and fixed from the base.

X-ray and CT-scan of the thorax showed a lump on the left clavicular bone which has intruded into the thoracic cavity. It was diagnosed as a malignant tumor of the clavicle, and a biopsy was performed (PA No.:9406585), and diagnosed as fibroblastic osteosarcoma. Due to previous history of radiotherapy 16 years earlier, in which the middle portion of the left clavicle, where the lesion was located, was within the field of radiation, the patient was diagnosed as having secondary post-irradiation osteosarcoma.

DISCUSSION

Radiotherapy will bring certain complication to the bone such as osteonecrosis, growth disturbance, osteitis and pathological fracture. The most feared complication is the development of secondary malignant degeneration at a latter time.^{2,3} The most frequently encountered post-irradiation sarcomas to bone are secondary osteosarcoma and secondary fibrosarcoma,^{4,5} in children, the most frequent post irradiation sarcoma is secondary osteosarcoma.⁶

* Subdivision of Orthopaedics, Department of Surgery, University of Indonesia Faculty of Medicine and Cipto Mangunkusumo General Hospital, Jakarta, Indonesia
Department of Radiology, University of Indonesia Faculty of Medicine and Cipto Mangunkusumo General Hospital, Jakarta, Indonesia

Histologically, primary osteosarcoma are mostly osteoblastic type, whereas in post-irradiation osteosarcomas the fibroblastic type is more commonly observed.^{3,6}

Cahan and Arlen^{4,7} described the criteria of post-irradiation osteosarcoma as follows :

1. the irradiated primary tumor has no osteoblastic activity.
2. the secondary malignancy develop in the area within the field of radiation.
3. the presence of a relatively long latent period
4. the presence of osteosarcoma is confirmed by pathological examination

Wiklund⁸ reported that the incidence of post-irradiation sarcomas was more frequent in women who have had primary malignancies of the breast and genital organs, so that the sites frequently found with secondary malignancies in women were the shoulders and hip.³

The secondary sarcoma is attributed to genetic mutation as a consequence of irradiation.^{2,4}

The incidence of secondary osteosarcomas is extremely low, about 0.05 - 0.2% in patients who survived 5 years after irradiation, receiving between 4000 - 7000 cGy.² Frassica⁹ noted an incidence of 0.035 - 1% of all malignant cases that had been irradiated, whereas Hatfield¹⁰ reported an incidence of 0.2% in patients with breast cancer who survived 10 years after irradiation.

The presence of a latent period is a requisite for a case to be classified as post-irradiation secondary malignancy. The latent period reported in the literature varied between 4 - 52 years.^{1,5,9} The latent period will be shorter in the presence of a genetic predisposition such as retinoblastoma, and v.Recklinghausen's neurofibromatosis.^{8,11} The same condition applies to children who are in the growing period when cell proliferation is more active.¹⁰

Hatfield^{9,10} was of the opinion that post-irradiation sarcomas should be distinguished from the double primary phenomenon. This phenomenon explains the higher probability of the same patient to develop a

secondary malignant process which is different from the primary one, and will manifest after a shorter latent period compared to the latent period consequent to irradiation. The average latent period for developing post-irradiation secondary malignancies is about 12 years, whereas that of double primary is less than 5 years.¹⁰

The prognosis of post-irradiation osteosarcoma is poor⁹ which is attributed to the facts that :

1. it is usually recognized at an advanced stage
2. patients are of old age and afflicted with multiple medical problems
3. no effective adjuvant therapy is available.

In cases of secondary osteosarcoma reported by Dahlin,¹² none of the patients survived for more than 3 years.

The present case was diagnosed as post-irradiation osteosarcoma as it fulfilled the criteria suggested by Cahan and Arlen^{4,7} namely :

1. the primary tumor being irradiated was a nasopharyngeal carcinoma which did not have any osteoblastic activity.
2. the secondary osteosarcoma developed in the middle part of left clavicular bone, which was within the field of irradiation.
3. the latent period of 16 years was quite long, so it could not be considered as a double primary case.¹⁰
4. the malignancy found on the left clavicle was of the fibroblastic type, which was the histopathologic type frequently encountered in post-irradiation osteosarcoma.⁶

Other supporting findings were the location of the lesion which was unusual for primary osteosarcomas,¹² and absence of a genetic predisposition, so that irradiation appeared to be the single causative factor.⁸ In accordance with the literature the prognosis was poor because of the advanced stage in which the tumor was presented; the tumor had already invaded the thoracic cavity and was considered to be inoperable, in addition to the unavailability of effective chemotherapy.⁹ The patient succumbed within 6 months after the diagnosis of secondary osteosarcoma was established.

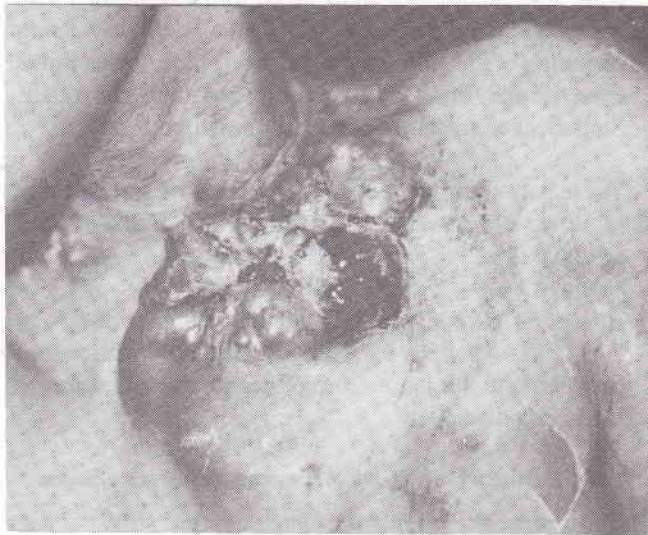


Figure 1. The clinical appearance and localization of the tumor is unusual for a primary osteosarcoma

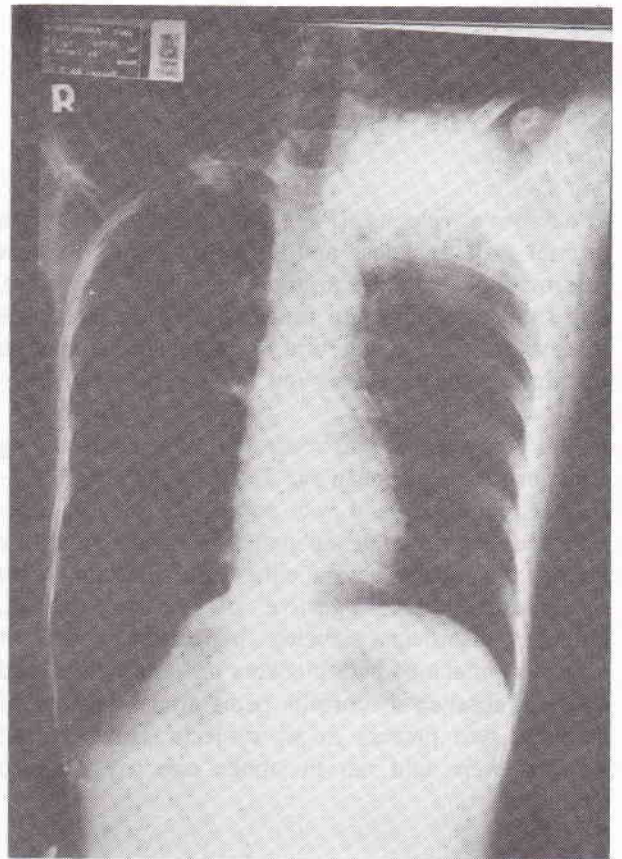


Figure 2. X-ray appearance of the case, show a mass in the left clavicle, which already infiltrated to left intra thoracic space

REFERENCES

1. Kim JH, Chu FC, Woodard HQ, Melamed MR, Huvos A, Cantin J. Radiation induced soft tissue and bone sarcoma. *Radiology* 1978; 129: 501 - 8.
2. Bechler JR, Robertson WW, Meadows At, Womer RB. Osteosarcoma as a second malignant neoplasm in children. *J Bone Joint Surg.* 1992; 74A: 1079 - 83.
3. Huvos AG, Woodard HQ, Cahan WG, Higinbotham NL, Stewart FW, Butter A, et al. Post-radiation osteogenic sarcoma of bone and soft tissue. A clinic pathologic study of 66 patients. *Cancer* 1985; 55: 1244 - 55.
4. Arlen M, Higinbotham NL, Huvos AG, Marcove RC, Miller T, Shah IC. Radiation induced sarcoma of bone. *Cancer* 1971; 28: 1087 -99.
5. Tillotson C, Rosenberg A, Gebhardt M, Rosenthal DI. Post radiation multicentric osteosarcoma. *Cancer* 1988; 62: 67 - 71.
6. Newton WA, Meadows AT, Shimada H, Bumin GR, Vawter GF. Bone sarcomas as second malignant neoplasms following chlidhood cancer. *Cancer* 1991; 67: 193 - 201.
7. Cahan WG, Woodard HQ, Higinbotham NL, Stewart FW, Coley BL. Sarcoma arising in irradiated bone. *Cancer* 1948; 1: 3 - 29.
8. Wiklund TA, Blomquist CP, Ratly J, Elomaa I, Rissanen P. Post-radiation sarcoma. Analysis of a nationwide cancer registry material. *Cancer* 1991; 68: 524 - 31.
9. Frassica FJ, Sim FH, Frassica DA, Wold LE. Survival and management considerations in post radiation osteosarcoma and Paget's osteosarcoma. *Clin Orthop* 1990; 270: 120-7.
10. Hatfield PM, Schulz MD. Post irradiation sarcoma including 5 cases after x-ray therapy of breast carcinoma. *Radiology* 1970; 96: 593 - 602.
11. Meadows AT, Strong LC, Li FD, D'Angio GJ, Schweisguth O, Freeman AI, et al. Bone sarcoma as a second malignant neoplasms in children : influence of radiation and genetic predisposition. *Cancer* 1980; 46: 2603 - 06.
12. Unni KK. *Dahlin's Bone Tumors. General Aspect and Data on 11,087 Cases.* 5th edition. New York; Lippincott - Raven, 1996: 164 - 5.