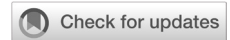

Surgical techniques to reduce oronasal fistula risk in wide cleft palate repair: a systematic review

Prasetyanugraheni Kreshanti,^{1,2} Patricia Marcellina Sadikin,¹ Margareth Ingrid Anggraeni,¹ Jasmine Athiyya Wibowo,² Kristaninta Bangun^{1,2}



pISSN: 0853-1773 • eISSN: 2252-8083
<https://doi.org/10.13181/mji.oa.236347>
Med J Indones. 2022;31:250–9

Received: July 06, 2022

Accepted: March 24, 2023

Authors' affiliations:

¹Department of Surgery, Faculty of Medicine, Universitas Indonesia, Cipto Mangunkusumo Hospital, Jakarta, Indonesia, ²Cleft and Craniofacial Center, Cipto Mangunkusumo Hospital, Jakarta, Indonesia

Corresponding author:

Prasetyanugraheni Kreshanti
 Division of Plastic Surgery, Department of Surgery, Faculty of Medicine, Universitas Indonesia, Cipto Mangunkusumo Hospital, Medical Staff Building 4th floor, Jalan Diponegoro No. 71, Central Jakarta 10430, DKI Jakarta, Indonesia
 Tel/Fax: +62-21-3929140
 E-mail: pras_md@yahoo.com

ABSTRACT

BACKGROUND Wide cleft palate is a common congenital anomaly, particularly in developing countries with limited access to plastic surgeons and specialized cleft centers. It can be severe and may contribute to the development of oronasal fistula, which can occur in up to 78% of cases. Despite numerous surgical techniques for wide cleft repair, the best method remains unclear. This study aimed to identify surgical techniques for wide cleft palate repair to minimize the occurrence of oronasal fistula.

METHODS Literature searching was conducted using multiple online databases including PubMed, Scopus, and Cochrane Library. The keywords used were “cleft palate”, “surgery”, “technique”, “palatoplasty”, and “wide”. Inclusion and exclusion criteria were applied to select relevant studies, and the quality was assessed.

RESULTS A total of 12 studies discussed surgical techniques to repair the primary wide cleft palate and their outcome on oronasal fistula formation. The surgical techniques included modified Furlow palatoplasty, two-flap palatoplasty, and modified Bardach’s two-flap palatoplasty. The incidence of oronasal fistula was 9.6% (n = 28/291) in one-stage Furlow palatoplasty and 12.0% (n = 24/200) in the modified one-stage two-flap palatoplasty.

CONCLUSIONS Two-flap palatoplasty and Furlow palatoplasty (and their modifications) were the safe surgical techniques for wide cleft repair with a low occurrence of oronasal fistula.

KEYWORDS cleft palate, fistula, surgery, technique

Cleft lip and palate are among the most common congenital craniofacial anomalies and impose a significant disease burden, particularly in low- to middle-income countries such as Indonesia where access to plastic surgeons and specialized cleft centers is limited.¹⁻⁴ The incidence of cleft lip and palate is approximately 1 per 750 live births, while isolated cleft palate affects 0.1 to 1.1 per 1,000 births.^{5,6} Various surgical techniques are available to repair the cleft palate, including the von Langenbeck palatoplasty, the Veau-Wardill-Kilner pushback palatoplasty, the Furlow

double opposing Z-plasty, and the Bardach’s two-flap palatoplasty.^{1,5,6} With advances in surgical techniques and modalities, complete closure of cleft palate with excellent maxillary growth and speech outcomes is now achievable.⁶⁻⁸

However, wide cleft palate repair remains a challenge for plastic surgeons.⁹ The lack of local tissues to cover the defect during closures creates tension that often results in fistula formation.^{4,8-10} Surgeons may modify their techniques by performing extensive dissection of the mucoperiosteal layer, which can lead

to secondary fibrosis, decreased soft palate mobility, and increased fistula formation.⁹⁻¹¹ In addition, medial mobilization of the mucoperiosteal flaps in wide palatal defects creates larger denuded bones, leading to disturbance of maxillary growth.^{10,11}

Despite the high prevalence of wide cleft palate, there is no consensus on its definition and method of measurement to evaluate cleft palate severity.⁶ Furthermore, the best surgical technique for wide cleft palate closure has yet to be established. This study aimed to investigate surgical techniques for repairing wide cleft palate and minimizing the occurrence of fistula.

METHODS

Search and selection processes

This systematic review was conducted based on the Preferred Reporting Items for Systematic Reviews and Meta-Analyses statement and was registered in PROSPERO (CRD42021248942). An online literature search was conducted in November 2022 using multiple online databases, including PubMed, Scopus, and Cochrane Library, using the keywords “cleft palate”, “surgery or technique or palatoplasty”, and “wide or large or severe”. These were limited to studies

published from January 1, 1995 to October 31, 2022, in English, and involving human subjects (Table 1).

Three reviewers (PK, PMS, and MIA) assessed the articles based on the inclusion and exclusion criteria. We reviewed the titles and abstracts of the retrieved articles and included only those that discussing surgical techniques for repairing primary wide cleft palate and their outcome on oronasal fistula formation. Then, the possible included studies were filtered for duplicates. Studies that involved cases other than the congenital cleft palate, used free tissue transfer to seal the palatal cleft, and did not define cleft width, surgical procedures used, and fistula as the outcome were excluded. Studies published in languages other than English, case reports, revision or secondary cases, and letters to editors were also excluded. Any disagreements between the reviewers were resolved through consensus (Figure 1).

Data extraction, data analysis, and quality assessment

All extracted data, including types of study, number of patients, Veau’s cleft classification, cleft palate width, method of measurement, palatoplasty technique, modifications used, and the occurrence of oronasal fistula from each article were recorded in a table.

Table 1. Search strategy

Database	Search strategy
Pubmed	("cleft palate"[MeSH Terms] AND (((("surgery"[Subheading] OR "surgery"[All Fields] OR "surgical procedures, operative"[MeSH Terms] OR ("surgical"[All Fields] AND "procedures"[All Fields] AND "operative"[All Fields]) OR "operative surgical procedures"[All Fields] OR "surgery"[All Fields] OR "general surgery"[MeSH Terms] OR ("general"[All Fields] AND "surgery"[All Fields]) OR "general surgery"[All Fields]) OR technique[All Fields]) OR palatoplasty[All Fields])) AND ((wide[All Fields] OR large[All Fields]) OR severe[All Fields]) AND "humans"[MeSH Terms] AND English[lang])
Scopus	(TITLE-ABS-KEY (cleft palate)) AND (TITLE-ABS-KEY (wide) OR TITLE-ABS-KEY (severe) OR TITLE-ABS-KEY (large)) AND (TITLE-ABS-KEY (surgery) OR TITLE-ABS-KEY (technique) OR TITLE-ABS-KEY (palatoplasty)) AND (LIMIT-TO (PUBYEAR, 2022) OR LIMIT-TO (PUBYEAR, 2021) OR LIMIT-TO (PUBYEAR, 2020) OR LIMIT-TO (PUBYEAR, 2019) OR LIMIT-TO (PUBYEAR, 2018) OR (LIMIT-TO (PUBYEAR, 2017) OR LIMIT-TO (PUBYEAR, 2016) OR LIMIT-TO (PUBYEAR, 2015) OR LIMIT-TO (PUBYEAR, 2014) OR LIMIT-TO (PUBYEAR, 2013) OR LIMIT-TO (PUBYEAR, 2012) OR LIMIT-TO (PUBYEAR, 2011) OR LIMIT-TO (PUBYEAR, 2010) OR LIMIT-TO (PUBYEAR, 2009) OR LIMIT-TO (PUBYEAR, 2008) OR LIMIT-TO (PUBYEAR, 2007) OR LIMIT-TO (PUBYEAR, 2006) OR LIMIT-TO (PUBYEAR, 2005) OR LIMIT-TO (PUBYEAR, 2004) OR LIMIT-TO (PUBYEAR, 2003) OR LIMIT-TO (PUBYEAR, 2002) OR LIMIT-TO (PUBYEAR, 2001) OR LIMIT-TO (PUBYEAR, 2000) OR LIMIT-TO (PUBYEAR, 1999) OR LIMIT-TO (PUBYEAR, 1998) OR LIMIT-TO (PUBYEAR, 1997) OR LIMIT-TO (PUBYEAR, 1996) OR LIMIT-TO (PUBYEAR, 1995)) AND (LIMIT-TO (DOCTYPE, "ar") OR LIMIT-TO (DOCTYPE, "re")) AND (LIMIT-TO (LANGUAGE, "English")) AND (LIMIT-TO (SRCTYPE, "j")) AND (LIMIT-TO (SUBJAREA, "MEDI"))
Cochrane Library	#1 "cleft palate":ti,ab,kw Publication Year from 1995 to 2022 (Word variations have been searched) #2 "technique" or "surgery" or "palatoplasty" Publication Year from 1995 to 2022 (Word variations have been searched) #3 "wide" or "large" or "severe" Publication Year from 1995 to 2022 (Word variations have been searched) #1 and #2 and #3

Cleft width was defined as the distance between the medial side of palatal shelves, measured in a specific location using a specific method of measurement. Palatoplasty techniques included well-known cleft palate repair techniques, such as the von Langenbeck palatoplasty, the Veau-Wardill-Kilner pushback palatoplasty, the Furlow double opposing Z-plasty, and the Bardach’s two-flap palatoplasty. Technique modification referred to any modification applied to the surgical procedure besides the standard (original) technique.

The quality of the included studies was assessed using the quality assessment tool for case series described by the National Heart, Lung, and Blood Institute of the Department of Health and Human Services, United States.¹²

RESULTS

The search initially yielded 3,340 articles (PubMed = 1,611, Scopus = 1,643, and Cochrane Library = 86). After abstract and title screening and duplicate article removal, only 45 full-text articles were then assessed for eligibility. Of these articles, 33 did not meet the

inclusion criteria, resulting in only 12 being included (Figure 1).

Eleven articles^{4,6-8,10,13-18} discussed one-stage palatoplasty, and one article¹⁹ addressed two-stage palatoplasty. The included articles consisted of two prospective cohort studies,^{10,19} one retrospective cohort study,⁴ and nine retrospective studies (case series).^{6-8,13-18} The prospective cohort study by Sakran et al¹⁰ compared groups of patients treated with modified palatoplasty with Furlow Z-plasty, von Langenbeck repair, and two-flap palatoplasty. A prospective cohort study by Nadjmi et al¹⁹ compared between patients treated with classic Furlow palatoplasty and modified Furlow palatoplasty. All patients in both groups were combined in the analysis as they had wide cleft palate and used Furlow techniques. Gupta et al⁴ conducted a retrospective cohort study comparing between narrow cleft and wide cleft groups; hence, we only included the wide cleft group for the analysis. Overall, all the studies were considered case series.

There were 695 patients with wide cleft palate treated with either one- or two-stage palatoplasty. Most patients aged 5.8 months to 15 years, with the

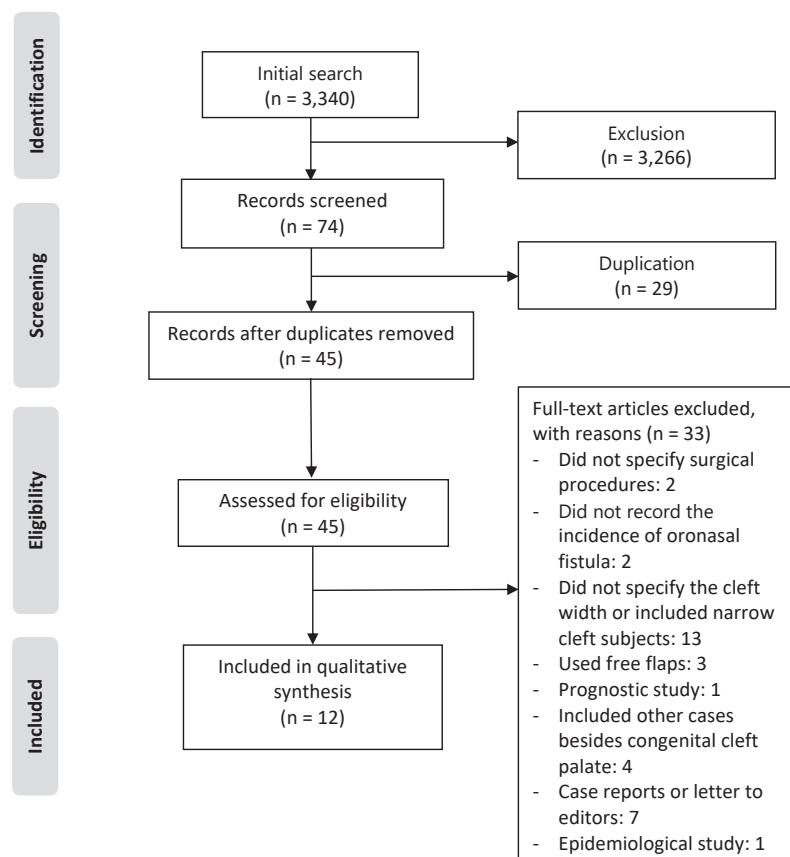


Figure 1. Search flow diagram

Table 2. Summary of included studies, techniques used, their modifications, and oronasal fistula rate

First author, year	Study type	Sex	Age	Length of study	Veau classification	Cleft width	Methods of measurement	Stage of repair/technique used	Modifications	Oronasal fistula rate, n/N (%)
Sakran, ¹⁰ 2021	Prospective cohort	64 males and 78 females	Mean (SD) age: 2 years 1.5 (0.6) years	2 years	II-III	>8 mm	Measured at the greatest width of the cleft (most often located at the junction of the hard and soft palates)	<ol style="list-style-type: none"> Modified palatoplasty with Furlow Z-plasty von Langenbeck procedure Two-flap palatoplasty 	Anterior stabilization of nasal layer by suture and adaptation of the relaxing incision from von Langenbeck technique in Furlow Z-plasty	<ol style="list-style-type: none"> 6/60 (10) 5/51 (9.8) 6/31 (19.4)
Lin, ¹⁶ 2015	Retrospective (case series)	Not stated	Mean age: 10.6 months	10 years	I-IV	≥10 mm	Measured at the greatest width along the cleft (most often located at the junction of the hard and soft palates)	One-stage/two-flap pushback palatoplasty (modified two-flap palatoplasty)	Incision until gingiva using vomer flaps, releasing the levator veli palatini muscle and retrodisplacing it for palate lengthening, reconstructing the muscular sling with intravelar veloplasty, velum lengthening with pushback, and leaving the anterior cleft open for future closure during alveolar bone graft	18/83 (21.6)
Nadjimi, ¹⁹ 2013	Prospective cohort - Control: Furlow - Study: modified Furlow	11 males and 29 females	Mean (SD) age: 10.8 (2.1) months	5 years	II-IV	≥9 mm	Measured at the junction between the hard and soft palates	<ol style="list-style-type: none"> 10 patients (control group): Furlow palatoplasty 30 patients (study group): unilateral buccal myomucosal flap + modified Furlow palatoplasty 	The levator muscle was reunited with minimal overlap, a buccal myomucosal flap was used, and a two-stage procedure was employed to narrow the cleft width in the hard palate during the second operation.	0/40 (0)

Table continued on next page

Table 2. (continued)

First author, year	Study type	Sex	Age	Length of study	Veau classification	Cleft width	Methods of measurement	Stage of repair/ technique used	Modifications	Oronasal fistula rate, n/N (%)
Aboul-Wafa, ¹⁴ 2012	Retrospective (case series)	16 males and 20 females	Mean age: 15.5 (9–60) months	6 years	II–IV	1. Wide cleft palate: the distance between the medial edges of the hard palate >1.5 cm 2. Extremely wide cleft palate: a palatal defect >60% of the width of the entire palate or in which the width of both palatal shelves was less than the width of the palatal defect	Not specified	One-stage/ islandized mucoperiosteal flap (modified two-flap palatoplasty)	Island flap was created by dissecting two mucoperiosteal flaps for about 1 cm from the neurovascular bundles located at the palatin foramen and behind the bundles exit.	0/36 (0)
Gupta, ⁴ 2011	Retrospective cohort - Group A: narrow clefts - Group B: wide and unrepairable clefts	Not stated	Mean age: 5 years (group A) and 9.5 years (group B)	3 years	II–IV	1. Wide: cleft width at PNS \geq MPW 2. MPW = the mean of RPW and LPW 3. Unrepairable: PNS \geq RPW + LPW	Measured at the split PNS	One-stage/ modified Furlow palatoplasty	Either one or both mucoperiosteal flaps were islanded on the greater palatine pedicle, lateral relaxing incision was marked at the teeth's pericoronal area or lingual alveolar gingivomucoperiosteum, and buccal flaps were used for oral and nasal layers to lengthen the velum.	2/34 (5.9)

Table continued on next page

Table 2. (continued)

First author, year	Study type	Sex	Age	Length of study	Veau classification	Cleft width	Methods of measurement	Stage of repair/technique used	Modifications	Oronasal fistula rate, n/N (%)
Abbas, ¹³ 2011	Retrospective (case series)	26 males and 22 females	Mean age: 14.5 months	3 years	II	≥10 mm	Measured at the junction between the hard and soft palates	One-stage/rotation-transposition of the two mucoperiosteal flaps (modified von Langenbeck palatoplasty)	The shorter mucoperiosteal flap was rotated backward (90–180°) to fill the midline gap at the junction between the hard and soft palates. The other flap was transposed medially to fill the anterior gap of the cleft.	1/48 (2.1)
Shi, ¹⁸ 2009	Retrospective (case series)	21 males and 16 females	Mean age: 3.5 years	7 years	II	The ratio of cleft width to palate width was at least 1:3.	Not specified	One-stage/modified two-flap technique	A triangular flap from the oral mucosa was created in front of the cleft and connected to the medial end of the relaxing incision using a W-shaped incision. The triangular flap was then turned over and sutured to the nasal mucosa to close the wide anterior defect, while the normal sling of levator veli palatini was restored.	0/37 (0)
Helling, ⁸ 2006	Retrospective (case series)	Not stated	Mean age: 11.75 months	2 years	I–IV	≥15 mm	Not specified	One-stage/Furlow palatoplasty and decellularized dermal graft	Placement of decellularized dermal graft at the hard and soft palate junction, before oral mucosa layer closure.	1/6 (16.6)

Table continued on next page

Table 2. (continued)

First author, year	Study type	Sex	Age	Length of study	Veau classification	Cleft width	Methods of measurement	Stage of repair/technique used	Modifications	Oronasal fistula rate, n/N (%)
Bakthavachalam, ⁶ 2006	Retrospective (case series)	Not stated	Mean age: 13.5 months	8 years	Not specified	Extremely wide hard palate: the width of the palatal defect was greater than 60% of the width of the entire palate or where the width of both palatal shelves was less than the width of palatal defect.	Not specified	One-stage/the double transposition flap (modified two-flap palatoplasty)	The mucoperiosteal flaps were transposed in a transverse fashion. The incision lines crossed the hard palate transversely rather than longitudinally.	0/6 (0)
Clark, ⁷ 2003	Retrospective (case series)	Not stated	Range age: 12–18 months	1 year	II–IV	≥15 mm	Measured at the posterior edge of the hard palate, at its junction with the soft palate	One-stage/two-flap palatoplasty + intravelar veloplasty + decellularized dermal graft	Addition of decellularized dermal graft and intravelar veloplasty	0/7 (0)
Mann, ¹⁷ 2017	Retrospective (case series)	Not stated	Mean age: 7.76 months	28 years	I–IV	1. Wide (>10 mm) 2. Medium (5–10 mm) 3. Narrow (<5 mm)	Not specified	One-stage/double opposing Z-plasty (standard Furlow) with or without buccal flap	Using buccal flaps	20/191 (10.4)
Khan, ¹⁵ 2018	Prospective cohort	Not stated	Mean age: 9.7 months	10 years	Not specified	Mean (range) age: 14.4 (9–23) mm	Measured at the maxillary tuberosity	One-stage/sphenoid flap with oral layer mucoperiosteal flaps (modified von Langenbeck palatoplasty)	Using sphenoid flap	17/66 (25.8)

LPW=left palatal shelf width; MPW=mean palate width; PNS=posterior nasal spine; RPW=right palatal shelf width; SD=standard deviation

Table 3. Incidence of oronasal fistula in the modified Bardach's two-flap palatoplasty and modified one-stage Furlow palatoplasty groups

Modified Bardach's two-flap		Modified one-stage Furlow	
First author, year	Fistula rate, n/N (%)	First author, year	Fistula rate, n/N (%)
Sakran, ¹⁰ 2021	6/31	Sakran, ¹⁰ 2021	6/60
Lin, ¹⁶ 2015	18/34	Gupta, ⁴ 2011	2/34
Aboul-Wafa, ¹⁴ 2012	0/36	Helling, ⁸ 2006	1/6
Shi, ¹⁸ 2009	0/37	Mann, ¹⁷ 2017	20/191
Bakthavachalam, ⁶ 2006	0/6		
Clark, ⁷ 2003	0/7		
Total	24/200 (12.0)		28/291 (9.6)

mean age varied between 9.7 months to 3.5 years.^{6-8,13-18} Only one study evaluated older adults aged 8 months to 37 years and 2 months.⁴ Further descriptions of the included studies can be seen in Table 2.

The incidence of oronasal fistula ranged from 0% to 25.8% in all respective studies. It was more common in patients with modified two-flap palatoplasty (12.0%) than modified one-stage Furlow palatoplasty (9.6%).^{6,7,10,14,18,19} Studies using two-stage palatoplasty were not included in the calculation of oronasal fistula incidence as the outcomes were incomparable to one-stage palatoplasty (Table 3).

All studies had clear objectives, interventions, outcome measures, adequate length of follow-up, and well-described results. However, most studies had no statistical analysis, and half had an unclear location for cleft width measurement (unclear method of measurement). The quality assessment result of the included studies is available in the Supplementary Table 1.

DISCUSSION

The goals of cleft palate closure are to achieve complete closure of nasal and oral mucosa (absence of oronasal fistula), good speech outcome, minimization of hearing loss and middle ear complications, and normal maxillary growth.^{5,10,19,20} However, this can be difficult due to a lack of local tissues to close the wide gap, which can cause tension during closure and result in fistula formation that interferes with normal speech and maxillary growth.^{4,8-10,21} Repairing a wide cleft palate is challenging, and several modifications have been made to existing surgical techniques to address this issue.

The modified one-stage Furlow technique has been found to have a lower fistula rate than the

Bardach's two-flap technique, but no statistical analysis has been done due to the varying baseline characteristics of the subjects and surgical techniques used. The heterogeneity of the studies on this topic highlights the need for further high-quality and long-term studies.

The Bardach's two-flap palatoplasty, described in 1967, uses the existing palatal tissues to close the cleft¹⁷ but may not be easily applied in a wide cleft. To overcome tension, modifications involving extensive relaxing incisions are often required for this technique. However, this can result in a scar burden on the mucoperiosteal layer of the hard palate, which may impair midfacial growth in the long term.¹⁷ Additionally, extensive dissection of the mucoperiosteal layer is necessary, leading to secondary fibrosis, decreased soft palate mobility, and increased fistula formation.^{9,19,22} Several modifications of Bardach's two-flap technique have been developed to address midline tension of the wide cleft palate.^{6,13,14,16}

Modifications to the standard mucoperiosteal flap are required to address the high tension at the hard-soft palate juncture, which has limited mobility.^{7,15} This area can benefit from the use of decellularized dermal grafts as scaffolds for revascularization and reepithelialization of the mucosa, reducing the risk of fistula formation.^{7,8} Another challenging area is the anterior portion of an incomplete wide inverted-U-shaped cleft palate, where a triangular oral mucoperiosteal flap as a hinged flap can provide additional tissue to the nasal mucosa.¹⁸ However, these techniques may result in velopharyngeal insufficiency since there is no adequate palatal length.¹⁷

In 1986, Furlow presented a new technique using double opposing Z-plasty that could effectively lengthen

the palate and create a muscle sling for better speech outcomes. However, this technique can be challenging for a wide cleft palate because the additional length achieved by the Z-plasty may reduce the width. Despite this limitation, the modified Furlow technique is still widely used for wide cleft palate because of its superior speech outcomes.¹⁹

The Furlow technique could not close the nasal layer of the junction between the hard and soft palates, where the nasal mucosal layer is rotated to the posterior part of the hard palate on the contralateral side.^{12,16} To address this, buccal flaps are used to close the nasal layer at the posterior part of the hard palate. A contralateral buccal flap is also elevated and inserted as the oral layer in the midline of the wide hard palatal cleft, resulting in a tension-free closure without needing a lateral relaxing incision and leaving no raw surfaces on the lateral part of the hard palate.¹⁷

In a study by Nadjmi et al,¹⁹ a modified Furlow technique was used in two-stage palatoplasty. In this procedure, the soft palate is closed first, followed by the closure of the hard palate. The cleft width at the junction of the hard and soft palates, which is the most common location for oronasal fistula, was significantly reduced after the closure of the soft palate closure, from 11.45 mm (at the time of soft palate closure) to 3.915 mm (at the time of hard palate closure) with $p < 0.001$. This procedure enables a tension-free and straightforward closure of the hard palate without requiring extensive mobilization of palatal flaps, resulting in no fistula formation. Two-stage palatoplasty may be the best option for a wide cleft palate as it promotes velum lengthening without compromising maxillary growth.

A wide cleft is a significant risk factor for palatal fistula development.²³ To promote consistent clinical evaluation and research, an objective definition and method of measurement should be established. In this review, a cleft width of 15 mm was identified as the cut-off for a wide cleft.^{6,7,13} Rossell-Perry et al²⁴ utilized the palatal index to estimate cleft palate severity by measuring the ratio between the cleft width and the combined widths of the two palatal segments at the level of the posterior border of the hard palate. Cleft palate severity was classified as mild (palatal index values between 0–0.2), moderate (0.2–0.4), or severe (>0.4). This index was a good predictor of fistula development. Moreover, Berkowitz et al²⁵ used the relationship between cleft defect size and palatal

segment size to estimate the ideal timing for surgery to maximize palatal growth. They recommended to perform surgery when the ratio of the palatal cleft size to the total palate surface area of the palate medial to the alveolar ridges is $\leq 10\%$.²⁵ The ratio of the cleft width to the right and left palatal shelf widths at the junction of the hard and soft palates is a better indicator of the cleft palate severity.^{9,24} This junction is the most appropriate location to measure the cleft width as it has the widest gap along the cleft and is where the fistula most commonly occurs.^{6,15}

The limitation of this review was the low level of evidence (level IV) of each study, which did not directly compare different palatoplasty techniques to repair the palatal cleft. Thus, a fair evaluation of the outcomes could not be made. The heterogeneity of cleft palate types and definitions, methods of measurement of wide cleft palate, age at repair, and various techniques and modifications also hindered statistical comparison between techniques through meta-analysis across studies. In addition, the relatively small sample sizes might not be representative of the analysis. Although all studies had various surgical techniques with low rates of fistula, a comparison among these techniques could not be made. High-quality studies with larger sample sizes and higher levels of evidence, preferably randomized controlled trials, are needed.

In conclusion, Furlow palatoplasty and Bardach's two-flap palatoplasty were the most used one-stage palatoplasty techniques. However, two-stage palatoplasty can effectively decrease the hard palate cleft width before closure, resulting in a lower rate of palatal fistula. To make future studies comparable, it is recommended that a single definition of wide cleft palate and a standardized method of measurement be established.

Conflict of Interest

The authors affirm no conflict of interest in this study.

Acknowledgment

None.

Funding Sources

None.

REFERENCES

1. Shkoukani MA, Lawrence LA, Liebertz DJ, Svider PF. Cleft palate: a clinical review. *Birth Defects Res C Embryo Today*. 2014;102(4):333–42.
2. Williams WN, Seagle MB, Pegoraro-Krook MI, Souza TV, Garla

- L, Silva ML, et al. Prospective clinical trial comparing outcome measures between Furlow and von Langenbeck palatoplasties for UCLP. *Ann Plast Surg.* 2011;66(2):154–63.
3. Massenbourg BB, Hopper RA, Crowe CS, Morrison SD, Alonso N, Calis M, et al. Global burden of orofacial clefts and the world surgical workforce. *Plast Reconstr Surg.* 2021;148(4):568e–80e.
 4. Gupta R, Kumar S, Murarka AK, Mowar A. Some modifications of the Furlow palatoplasty in wide clefts—a preliminary report. *Cleft Palate Craniofac J.* 2011;48(1):9–19.
 5. Chepla KJ, Gosain AK. Evidence-based medicine: cleft palate. *Plast Reconstr Surg.* 2013;132(6):1644–8.
 6. Bakthavachalam S, Ducic Y. The double transposition flap for closure of the extremely wide hard palate cleft. *Arch Facial Plast Surg.* 2006;8(2):123–7.
 7. Clark JM, Saffold SH, Israel JM. Decellularized dermal grafting in cleft palate repair. *Arch Facial Plast Surg.* 2003;5(1):40–4; discussion 45.
 8. Helling ER, Dev VR, Garza J, Barone C, Nelluri P, Wang PT. Low fistula rate in palatal clefts closed with the Furlow technique using decellularized dermis. *Plast Reconstr Surg.* 2006;117(7):2361–5.
 9. Aldekhayel SA, Sinno H, Gilardino MS. Acellular dermal matrix in cleft palate repair: an evidence-based review. *Plast Reconstr Surg.* 2012;130(1):177–82.
 10. Sakran KA, Liu R, Yu T, Al-Rokhami RK, He D. A comparative study of three palatoplasty techniques in wide cleft palates. *Int J Oral Maxillofac Surg.* 2021;50(2):191–7.
 11. Denadai R, Zanco GL, Raposo-Amaral CA, Buzzo CL, Raposo-Amaral CE. Outcomes of surgical management of palatal fistulae in patients with repaired cleft palate. *J Craniofac Surg.* 2020;31(1):e45–50.
 12. National Heart, Lung, and Blood Institute (NHLBI). Quality assessment tool for case series studies, National Heart, Lung, and Blood Institute; 2021 [cited 2021 Jul 20]. Available from: http://www.nhlbi.nih.gov/health-pro/guidelines/in-develop/cardiovascular-risk-reduction/tools/case_series.
 13. Abbas AH. Repair of cleft palate by rotation–transposition of the two mucoperiosteal flaps: can this reduce the incidence of postoperative fistula? *Eur J Plast Surg.* 2011;34:279–83.
 14. Aboul-Wafa AM. Islandized mucoperiosteal flaps: a versatile technique for closure of a wide palatal cleft. *Can J Plast Surg.* 2012;20(3):173–7.
 15. Khan K, Hardwicke J, Seselgyte R, Morris P, Thorburn G, Kangesu L, et al. Use of the sphenoid flap in repair of the wide cleft palate. *Cleft Palate Craniofac J.* 2018;55(3):437–41.
 16. Lin KY, Black JS, Wang JS, Kerpelman J, Ho TV, Borowitz K. An outcome study of a 2-flap pushback palatoplasty used in the treatment of wide cleft palates. *J Craniofac Surg.* 2015;26(3):620–4.
 17. Mann RJ, Martin MD, Eichhorn MG, Neaman KC, Sierzant CG, Polley JW, et al. The double opposing z-plasty plus or minus buccal flap approach for repair of cleft palate: a review of 505 consecutive cases. *Plast Reconstr Surg.* 2017;139(3):735e–44e.
 18. Shi B, He X, Zheng Q, Wan Y, Li S, Xu Q, et al. Modified 2-flap technique in the correction of the wide “∩”-shaped incomplete cleft palate. *J Oral Maxillofac Surg.* 2009;67(10):2302–6.
 19. Nadjmi N, Van Erum R, De Bodt M, Bronkhorst EM. Two-stage palatoplasty using a modified Furlow procedure. *Int J Oral Maxillofac Surg.* 2013;42(5):551–8.
 20. Herford AS, Tandon R, Pivetti L, Cicciù M. Closure of large palatal defect using a tongue flap. *J Craniofac Surg.* 2013;24(3):875–7.
 21. Salyer KE, Sng KW, Sperry EE. Two-flap palatoplasty: 20-year experience and evolution of surgical technique. *Plast Reconstr Surg.* 2006;118(1):193–204.
 22. Parwaz MA, Sharma RK, Parashar A, Nanda V, Biswas G, Makkar S. Width of cleft palate and postoperative palatal fistula—do they correlate? *J Plast Reconstr Aesthet Surg.* 2009;62(12):1559–63.
 23. Losken HW, van Aalst JA, Teotia SS, Dean SB, Hultman S, Uhrich KS. Achieving low cleft palate fistula rates: surgical results and techniques. *Cleft Palate Craniofac J.* 2011;48(3):312–20.
 24. Rossell-Perry P, Caceres Nano E, Gavino-Gutierrez AM. Association between palatal index and cleft palate repair outcomes in patients with complete unilateral cleft lip and palate. *JAMA Facial Plast Surg.* 2014;16(3):206–10.
 25. Berkowitz S, Duncan R, Evans C, Friede H, Kuijpers-Jagtman AM, Prah Anderson B, et al. Timing of cleft palate closure should be based on the ratio of the area of the cleft to that of the palatal segments and not on age alone. *Plast Reconstr Surg.* 2005;115(6):1483–99.