

## Case Report

# Clinical presentation of myocarditis in pediatric: the role of cardiac magnetic resonance in diagnosis

Sisca Natalia, Octavia Lilyasari, Sony H. Wicaksono, Manoefris Kasim

Department of Cardiology and Vascular Medicine, Faculty of Medicine, Universitas Indonesia/National Cardiovascular Center Harapan Kita, Jakarta, Indonesia

### Abstrak

Miokarditis merupakan suatu penyakit inflamasi miokard dengan presentasi klinis dan onset yang bervariasi. Kesulitan dalam diagnosis seringkali menyebabkan pasien yang datang dalam kondisi akut tidak terdiagnosis sebagai miokarditis, lalu mendapatkan penanganan yang tidak tepat. Hal ini akan membahayakan karena menyebabkan cedera miokard lebih parah, bahkan dapat menyebabkan kematian mendadak. Di lain sisi, pasien dapat pula datang setelah lanjut, dalam kondisi kardiomiopati dilatasi (DCM) atau kardiomiopati aritmogenik (ARVD). Oleh karena itu diagnosis miokarditis ini menjadi hal yang sangat penting. Kasus ini menunjukkan bahwa cardiac magnetic resonance (CMR) merupakan alat diagnostik non-invasif yang penting dalam mendiagnosis miokarditis dengan keakuratan yang tinggi pada seorang anak laki-laki dengan keluhan nyeri dada. Pemeriksaan CMR ini menunjukkan morfologi jantung yang normal, fungsi ejeksi ventrikel kanan dan kiri yang normal, gambaran edema miokard dan jaringan fibrosis yang mengkonfirmasi diagnosis miokarditis sesuai dengan kriteria konsensus Lake Louise. CMR merupakan alat diagnostik non-invasif yang penting dalam mendiagnosis miokarditis dengan keakuratan yang tinggi.

### Abstract

Myocarditis is an inflammatory disease of myocardium with varied onset and clinical presentation which lead to diagnosis difficulties. These difficulties often cause incoming patients with acute condition are not diagnosed as acute myocarditis that subsequently may lead to improper therapy. This circumstance will probably cause more severe myocardial injury and even sudden death. On another circumstance, patients may also come late in conditions of dilated cardiomyopathy (DCM) or arrhythmogenic cardiomyopathy (ARVD) due to complexities of myocarditis early detection. Therefore, myocarditis diagnosis is extremely important. This case shows how CMR is important and highly accurate in diagnosing myocarditis through a case whereby a boy had complaints of chest pain and his CMR examination showed normal cardiac morphology with normal function of right and left ventricular, but with myocardial edema and tissue fibrosis, which confirmed the diagnosis of myocarditis according to the Lake Louise Consensus criteria. CMR is an important and high accuracy non-invasive diagnostic tool in myocarditis diagnosis.

**Keywords:** cardiac magnetic resonance, myocarditis, myocardial oedema

pISSN: 0853-1773 • eISSN: 2252-8083 • <http://dx.doi.org/10.13181/mji.v23i3.654> • Med J Indones. 2014;23:174-81  
Correspondence author: Sisca Natalia, [siscanatalias@yahoo.com](mailto:siscanatalias@yahoo.com)

Myocarditis is an inflammation of the myocardium caused by nonspecific response to various triggers such as viral or bacterial infections, cardiotoxic agents, infarction, or mechanical injury. Most of these etiologic factors may already be evident from the patient's history.<sup>1</sup> However, diagnosing this disease appears to be difficult due to heterogeneity of presentations ranging from asymptomatic to severely symptomatic. These symptoms include clinical heart failure and ventricular dilatation, fulminant heart failure and severe left ventricular dysfunction, with

or without cardiac dilatation, and a recent flulike syndrome accompanied by fever, arthralgias, and malaise.<sup>2</sup>

There are various ways to confirm those diagnoses such as clinical examination, pathological examination, or by using diagnostic criteria which are presented in the forthcoming parts. Furthermore, this paper elaborates and focuses on cardiac magnetic resonance (CMR) examination and its importance in the diagnosis of myocarditis.

### Case illustration

A 10 year-old boy, came to the National Cardiac Centre Harapan Kita (NCCHK) Hospital and had already had complaints of repeated chest pain since one day before admission. The pain was severe and located in the middle of chest which caused difficulty in breathing. He initially went to another hospital, pursued electrocardiogram (ECG) test and eventually was diagnosed with heart attack. Later on, he was given 2 tablets salicylic acid and 2 tablets of clopidogrel, and referred to the NCCHK Hospital. The patient also complained of fever, without any cough, cold, or diarrhea. Additionally, he had maternal history of normal childbirth and growth as well. At the emergency room of NCCHK, the physical examination was within normal limits, no abnormality was found.

ECG showed following characteristics: sinus rhythm (SR), QRS rate 101x/m, 30°QRS axis, normal P wave, PR interval of 0.08", QRS duration of 0.04", ST segment elevation V3-V9, II, III, aVF, R/S in

V1 < 1, R/S in V6 > 1. Some additional laboratory results were normal, while AST (79 U/L), ALT (26 U/L), CKMB (134 u/L), and hsTrop T (1029 ng/L) were increasing. Furthermore, chest X-rays showed normal heart and lungs. Echocardiographic examination showed normal cardiac morphology, with normal left ventricle global contractility (EF 65%), and normal RV contractility (TAPSE 2.3 cm) as well. There was no atrial septal defect (ASD), no ventricular septal defect (VSD) and no persistent ductus arteriosus (PDA). MSCT examination showed normal coronary artery, no stenosis and no coronary anomaly.

According to CMR, the morphology were: situs solitus, atrioventricular (AV) concordance, ventriculoarterial (VA) concordance, all pulmonary veins (PV) to left atrial (LA), no ASD, no VSD, no PDA, all valves are normal, normal left aortic arch, normal coronary artery; ventricle volume, function and flow measurement: left ventricle ESV/EDV/EF: 19.4/71.7/72.9%, right ventricle ESV/EDV/EF : 33.7/65.8/48.7%, stroke volume aorta 67 mL, pulmonal artery 65.1 mL; T2WSTIR:

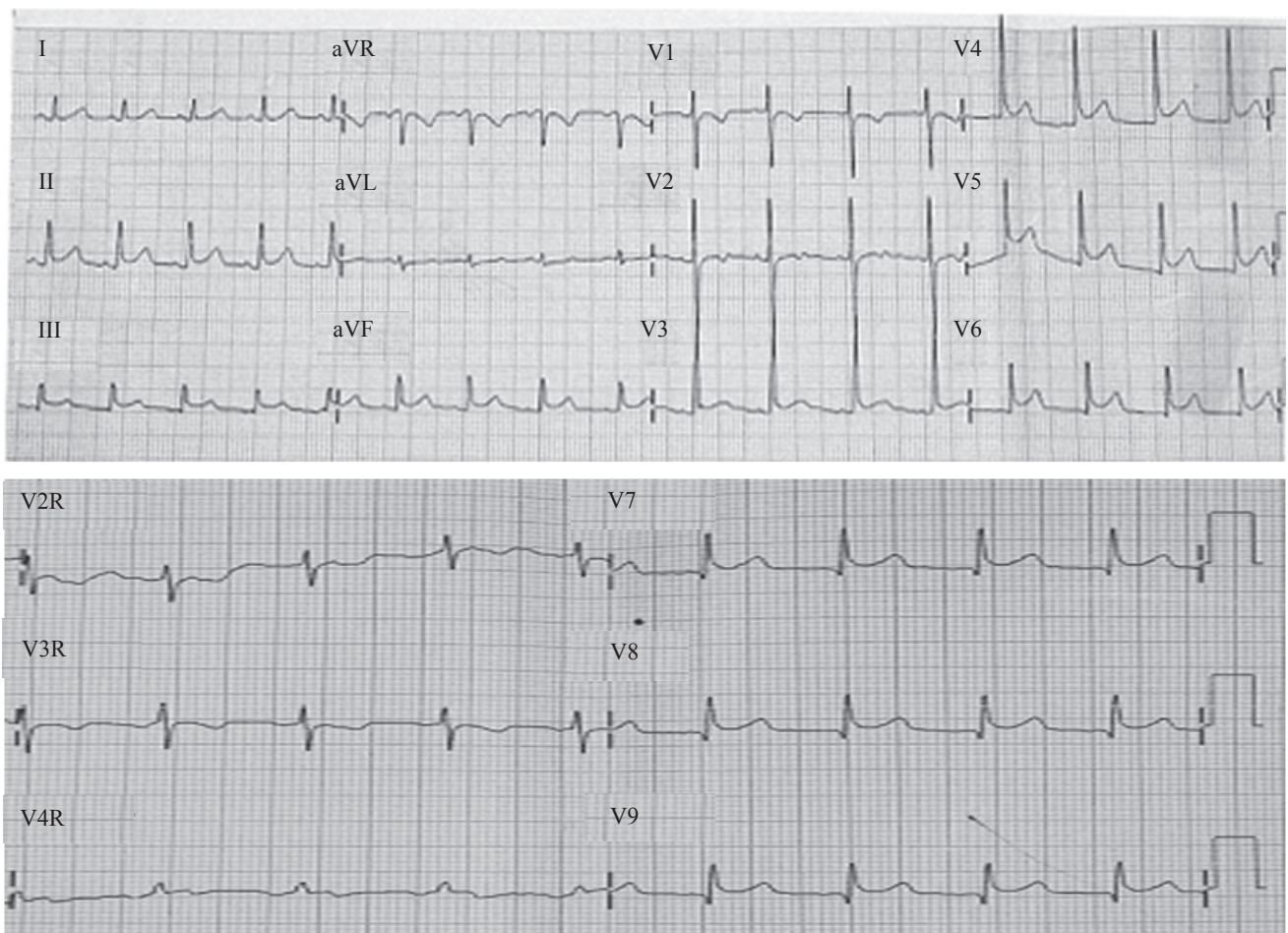
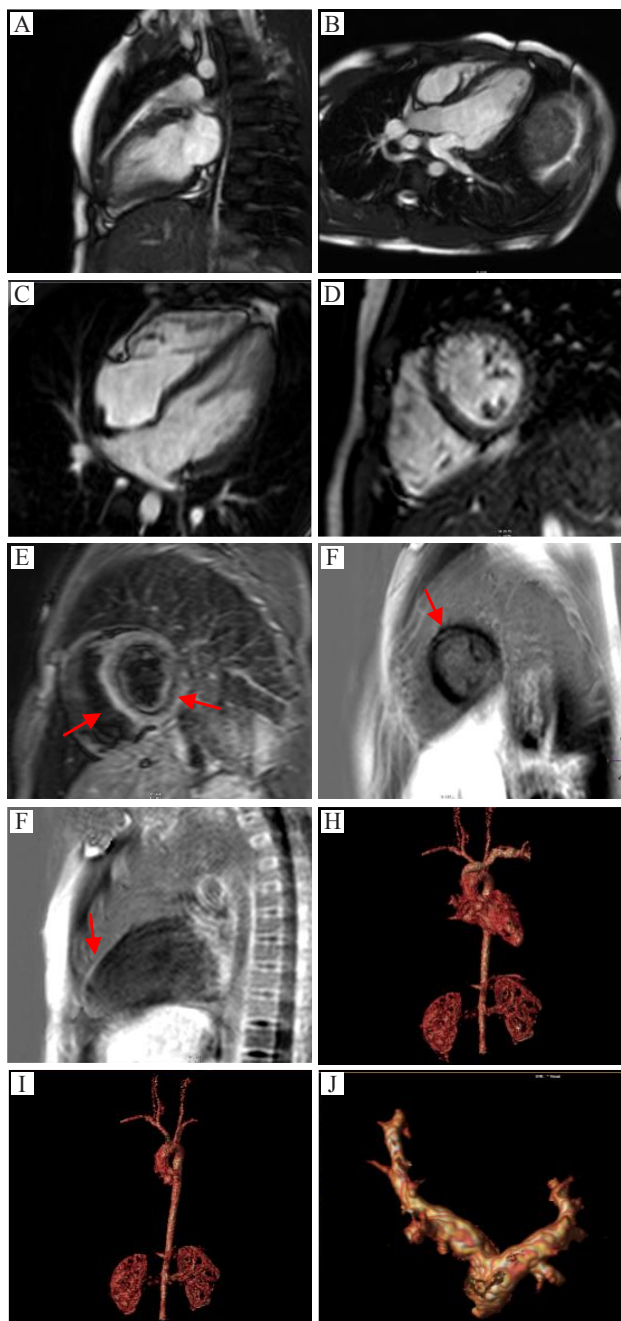


Figure 1. ECG at emergency room NCCHK hospital

myocardial edema at septal and inferolateral wall; late enhancement: fibrotic tissue at mid wall in septal and inferolateral, basal anterior wall; MRA: the thoracic aorta is normal, without aneurysm, coarctation or dissection. The pulmonary artery is normal in caliber. There are four pulmonary veins that enter the left atrium. LVOT: left ventricle outflow tract (Figure 2).



**Figure 2.** (A, B, C, D) normal cardiac morphology from different window. Situs solitus with concordance atrio-ventricle and ventriculo-arterial. No shunt ASD, VSD nor PDA. All valves are normal; (E) myocardial edema at septal and inferolateral wall; (F, G) fibrotic tissue at mid wall in septal and inferolateral, basal anterior wall; (H) normal coronary artery with left aortic arch; (I) normal thoracic aorta, without aneurysm, coarctation or dissection; (J) normal caliber of pulmonary artery

On the second day of treatment, CMR was performed, that showed normal cardiac morphology, with tissue edema and fibrosis in the mid area of the myocardial wall, as sign of myocarditis.

## DISCUSSION

### Myocarditis

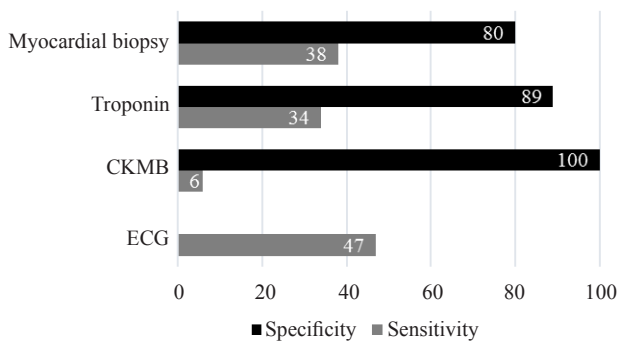
Myocarditis is clinically and pathologically defined as myocardial inflammation, which is an important cause of myocardial diseases such as dilated cardiomyopathy and arrhythmogenic right ventricular cardiomyopathy. Until recently, the classification, diagnosis and therapy of myocarditis were still debatable.<sup>3</sup> Incidence of myocarditis in young adults with sudden death reached 12%. Non-fatal incidence is likely higher than actually diagnosed due to difficulty of establishing the diagnosis in standard clinical settings.<sup>4</sup>

There are 3 phases in the development of enteroviral myocarditis in experimental animals.<sup>5</sup> Virus entry into myocytes mediated by a specific receptor coxsackie virus group B and a common transmembrane receptor (coxsackie virus and adenovirus receptor [CAR]) on some adenovirus genome for viral internalization into myocytes.<sup>6</sup> Coxsackie virus using deflecting decayaccelerating factor (DAF) and adenoviruses special integrins ( $\alpha\beta3$  and  $\alpha\beta5$ ) as co-receptors. If CAR is absent in the cardiac myocytes, virus infection and inflammation will not occur.<sup>7</sup> Acute injury to heart muscle cells occurs after viral entry, which is subsequently induced by virus replication.<sup>8</sup>

Acute phase of myocarditis occurred for just a few days, followed by a subacute phase characterized by an immune reaction. This phase can occur several weeks to several months, characterized by activation of virus-specific T lymphocytes, which can attack the organs of the patient because of the similarity of molecules. Activation of cytokines (tumor necrosis factor - alpha [TNF- $\alpha$ ], interleukin [IL] -1 and -6), viral protein of the heart can aggravate heart damage and result in impaired contractility function.<sup>8</sup>

### Several diagnostic modalities: challenges in the diagnosis of myocarditis

One major challenge in diagnosing myocarditis is requirement for various data derived from anamnesis, physical examination, and non-invasive examination which potentially have different



**Figure 3.** Proportional efficacy of some examinations for myocarditis with various range of sensitivity and specificity. The specificity of ECG itself is unknown, according to this report. Modified from Liu PP<sup>9</sup>

sensitivity and specificity. As shown by Liu PP, et al<sup>9</sup> there are none perfect examinations with high both sensitivity and specificity that really good enough to diagnose myocarditis, but one each other is needed in establishing a correct diagnosis.

### History and physical examination

Patient presentation may be virtually normal, with non-specific symptoms, or with clinical acute signs of myocardial infarction or heart failure. Physical examination is often without any abnormalities.<sup>10</sup> Certain literature stated that major cardiac symptoms in the acute phase were chest pain (71%), and 61% of myocarditis patients reported a history of cardiac infection before symptoms appear, such as respiratory tract infections, gastroenteritis, skin infections.<sup>11</sup> In the case reported here, the patient complained about repeated chest pain and no abnormality was found in physical examination.

### Electrocardiogram

ECG findings of myocarditis may include ST segment changes, T-wave, Q-waves, atrioventricular block and bundle branch block. Additionally, arrhythmias such as ventricular tachycardia and ventricular fibrillation may also occur. ECG in myocarditis has a low diagnostic value. ST segment elevation or T inversion is the most sensitive criterion in 50% of patients. Morgera, et al examined the clinical and prognostic value of the ECG performed consecutively in 45 histologically proven myocarditis cases (29 men and 16 women). In patients with onset of less than one month, ECG at the time of admission was AV block and repolarization abnormalities, whereas the pattern obtained from fulminant myocarditis was

pseudoinfarction (Q-wave coupled with ST-segment elevation). Left atrial enlargement, atrial fibrillation, right ventricular enlargement and blocks were found in patients with chronic symptoms.<sup>12</sup> In this case, the ECG abnormalities at the time of admission were ST-segment elevation in leads V3-V9, II, III, aVF. In children, ST-segment elevation more than 0.2 mV in more than one lead found in some cases of myocarditis and pericarditis.<sup>13,14</sup> According to Gazit, et al<sup>15</sup> ST-segment changes, diagnostic of transmural myocardial infarction in adults may be seen in pediatric patients without coronary artery occlusion.

### Biomarkers

Serum biomarkers of myocardial injury such as CK, CKMB, and troponin can increase depending on the severity and time of testing during the course of disease.<sup>16</sup> In this case, the cardiac enzymes were increased (CKMB 134u/L, hs Troponin T 1029ng) due to injury.

### Echocardiography

Cardiac wall motion abnormalities will often be found in chronic cases, both regionally and globally. Ventricular dysfunction is not specific to inflammation and its sensitivity is low as well. Biventricular dysfunction in myocarditis has been reported to be a major predictor of death and transplantation.<sup>17</sup> In this case there is no ventricular dysfunction.

### Biopsy

The Dallas criteria 1987 for myocarditis is the finding of infiltrating lymphocytes induced by myocyte injury in the absence of ischemia. Endomyocardial biopsy (EMB) is the gold standard examination to diagnose myocarditis, which viral genomes identified.<sup>18</sup> This criterion is very specific but only has a sensitivity of 10-22%, the lack of precision being caused by sampling errors.<sup>19</sup> Severe complications due to EMB (perforation, tamponade) occurred in 0.1 -0.5% and the overall complication occurred for about 6%.<sup>20</sup> The biopsy was not performed to this patient due to those considerations.

### CMR on myocarditis

The advance in medicine has helped us to understand the progression from acute to chronic myocarditis and even to dilated cardiomyopathy accompanied by life threatening symptoms.<sup>9</sup> The

diverse onset and clinical presentations would mean that some patients will come after serum markers and electrocardiographic changes of acute injury have already subsided. Furthermore, the clinical presentations of acute and chronic myocarditis frequently overlap. The differentiation between acute and chronic myocarditis affects the clinical management of the patients, such as physical exercise within the acute phase of myocarditis is known to have harmful effects on the severity of myocardial injury and may even lead to sudden cardiac death.<sup>11</sup>

Therefore diagnosis of myocarditis is very important. This can be done by non-invasive diagnostic tool with high accuracy with cine CMR, early and late contrast enhancement CMR, and T2WSTIR.<sup>9</sup> Gagrialdi, et al<sup>20</sup> showed the use of CMR as a non-invasive diagnostic tool in acute myocarditis of 11 children. Compared to biopsy, T2-weighted spin echo CMR had 100% specificity and 100% sensitivity.<sup>20</sup> This small study was followed by a second report by the same researchers in 75 pediatric patients with acute symptomatic heart failure. From biopsy, they identified 51 patients with acute myocarditis and 24 patients with idiopathic dilated cardiomyopathy. By using biopsy as the diagnostic standard, T2 weighted CMR showed 100% sensitivity and 90% specificity. Then all of these patients were followed for 2 years and CMR was performed every 6 months. The sensitivity and specificity remained high during the evolution when the disease continues.<sup>21</sup> Combination of several techniques will be beneficial, especially in cases that are not clear. Indeed, CMR is currently the most accurate diagnostic method both, in guiding biopsy or in seeing the development of disease.<sup>1</sup>

### Indication

CMR examination is indicated in patients with signs and symptoms that lead to myocarditis, significant evidence of myocardial injury and suspicion of viral etiology. Potential CMR examination performed in patients with chest pain, increased troponin and

normal coronary arteries. Another indication is in patients with myocarditis due to the ECG findings that lead to signs of myocarditis.<sup>22</sup> In this case CMR examination was indicated in the presence of chest pain, ECG abnormalities, increased of troponin, and age of 10 years as well.

### Procedure

CMR techniques used to assess myocarditis are SSFP (steady-state free precession) to assess left ventricular function and volume, T2 weighted (T2W) to assess myocardial edema as well. The use of T2W imaging (a sensitive pulse sequence) is to see an increase in myocardial water both regionally and globally, which is the substantial finding as an inflammatory response in myocarditis. Additionally, early global relative enhancement (GRE) or dynamic first-pass perfusion myocardial imaging during entry of 0.05-0.1 mmol/kg of gadolinium chelate injection shows the increased of capillary leakage, and late T1 weighted after gadolinium injection (late gadolinium enhancement) reflects irreversible injury.<sup>11,23</sup>

### CMR findings

CMR findings in myocarditis may vary depending on time elapsed from onset of symptoms to time when CMR is done. Focal form of acute myocarditis was found in the first 5 days and will develop into more spacious. CMR can detect ongoing inflammation, the extent, severity, and can distinguish an acute or chronic myocarditis. In the first days of the disease, myocardial edema will be found in about 30% of cases and is seen as hypersignal on T2 weighted. Edema predominantly in the inferolateral wall with or without thickening of the walls of the heart, as it is also found in autopsy.<sup>13</sup> Pericardial effusion presents in approximately 20% of cases and is usually moderate. Cine CMR may demonstrate wall motion abnormalities of the heart that frequently diffuse global hypokinetic. In severe cases (fulminant) a decreased ejection fraction can be found without LV dilatation.

**Table 1.** Proportion of some studies on the accuracy of CMR in detecting acute myocarditis

	Friederich	Laissy	Mahrholdt	Abdel-Aty
Sensitifity (%)	84	100	88	76
Specificity (%)	100	100	91	95

Friedrich et al studied 19 patients and 18 controls, followed by Laissy et al examined 20 people and 7 controls. Mahrholdt et al examined 32 patients with 11 controls, and most recently by Abdel-Aty et al examined 25 patients with 23 patients as controls. Generally sensitivity was 86% with specificity of 95%. Modified from Liu PP<sup>9</sup>

Friederich, et al<sup>24</sup> stated acute myocarditis characterized by focal contrast enhancement on day 2, will spread on the 7<sup>th</sup> day become diffuse and then settle down to 2-4 weeks. On the 84<sup>th</sup> day, the contrast signal will subside as the group control. Roditi, et al<sup>25</sup> examined 12 patients with suspected acute myocarditis. They found focal enhancement of myocardial in 10 out of 12 patients, with regional wall motion abnormalities in hypokinetic, akinetic, or dyskinetic forms. Accumulation of gadolinium in these affected areas is due to membrane rupture, causing an increase in extracellular gap, inflammatory edema, permeability of blood vessels that lead to an increase in volume distribution, and lower distribution of gadolinium clearance as well.<sup>9,13</sup>

Myocarditis usually has a nodular or diffuse patchy distribution that does not follow the segmental vascular distribution. Patchy contrast enhancement on epicardial and lateral walls was found in 88% cases of myocarditis. Enhancement patterns in myocarditis generally do not involve subendocardium except in eosinophilic myocarditis. Furthermore, the type of virus and the pattern of myocardial damage suggests a relationship. Contrast enhancement in the lateral wall was found in the majority of myocarditis caused by parvovirus B19 (PVB19), whereas in the midwall septal interventricular midwall it was usually caused by human herpes virus 6 (HHV6).<sup>26</sup> Thus the contrast enhancement is not only able to distinguish myocarditis from infarction, but also can distinguish variations in viral cause. In this patient, whose ejection fraction were normal both on the right and left ventricles, myocardial edemas were found in the septal and inferolateral wall on T2 Weighted, and tissue fibrosis was found in the anterior and inferolateral wall of the mid and basal septum at LGE as well. The exposed walls were epicardial area and patchy form.

### **CMR criteria for myocarditis (“The Lake Louise criteria”)**

There are criteria for the diagnosis of myocarditis by The Lake Louise consensus criteria.<sup>10</sup> In this case, the diagnosis of myocarditis is established based on the findings of myocardial edema and tissue fibrosis on CMR examination, in addition to the results of normal coronary arteries on MSCT.

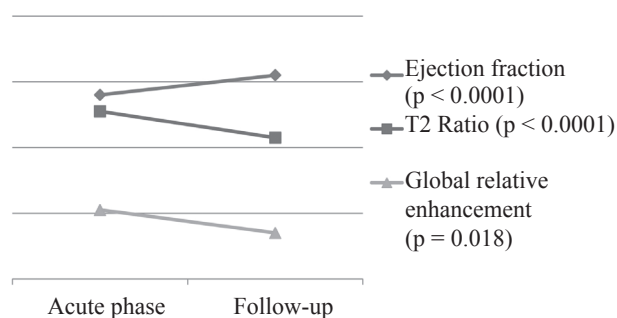
### **Myocarditis versus myocardial infarction**

Acute myocarditis is often diagnosed as myocardial infarction, especially in patients who present with

chest pain and ST segment elevation on the ECG. If patients have low risk profile or have a history of influenza, fever and cough, coronary angiography is an option to prevent the thrombolytics in cases of myocarditis. CMR was an important tools to confirm the diagnosis of myocarditis in the case of no stenosis on coronary angiography/CT angio examination.<sup>13</sup> There are several studies that distinguish ischemic cardiomyopathy from non-ischemic. McCrohon, et al revealed LGE in 90 patients with heart failure and LV systolic dysfunction. All patients with ischemic cardiomyopathy have subendocardial or transmural enhancement. In contrast, the non-ischemic cardiomyopathy group had 3 different patterns which is no enhancement (59%), patchy or longitudinal striae enhancement at midwall consistent with fibrosis (28%), and the remained can not be distinguished.<sup>27</sup> While Hunold, et al stated non-ischemic patients showed no involvement of subendocardial layer, GLE found only localized or epicardial or midmyocardial wall.<sup>28</sup> Myocardial infarction in these patients excluded by the findings of CMR picture, and the normal characteristic on coronary MSCT.

### **Follow-up**

Several case reports have demonstrated the benefits of CMR in the evaluation of therapy in patients with myocarditis. LGE will decrease significantly in the acute phase toward healing phase. If T2W and GRE are done together, the results will 100% negative predictive value to differentiate acute myocarditis with convalescent myocarditis. Uchida et al reported that the changes of T2W is rare in the chronic conditions.<sup>29</sup> Improvement on T2W and GRE are associated with clinical improvement and parameters of left ventricular function as shown in figure 4. Thus, has been also reported by Gutberlet et al that CMR can be used to evaluate disease progression or regression in response to therapy.<sup>30</sup> Supportive therapy is the first treatment of choice in patients with myocarditis. Heart failure caused by myocarditis must be given standard therapies such as diuretics to lower ventricular filling pressure, ACE-i to lower vascular resistance, and beta-blockers after clinically stable. Arrhythmias should be monitored and treated. Patients who received imunoglobulin improved ejection fraction in 17 units. Another therapy is prednisone.<sup>31</sup> Steroid therapy decreased tissue inflammation.<sup>32</sup> CMR can also non-invasively monitor tissue damage that can lead to make a decision, such as reinstatement



**Figure 4.** Accordance of improvement of global left ventricular function and CMR parameters of acute myocardial injury in myocarditis. The lines showed changes of left ventricular ejection fraction, T2 ratio, and GRE in myocarditis evaluation. Improvement in ejection fraction is obviously in parallel with concurrent normalization of T2 and GRE. Modified from Zagrosek A et al.<sup>11</sup>

of normal physical activity if the parameters of acute injury have not been found anymore. Recent guidelines recommend restriction of activities in patients with acute myocarditis.<sup>11</sup> Some researches were conducted to follow myocarditis patients up to 3 months. The prognosis will be good if contractile function improve in sequence with significantly decreased of delayed enhanced of myocardial tissue damage.<sup>11,23</sup> This patient came with complaints of chest pain, no symptoms of heart failure, a good pump function, and without arrhythmia as well. Furthermore, the patient was given anti-inflammatory drug (steroids). Throughout treatment the patient's condition was good, without chest pain, then patient discharged. CMR to conduct a re-evaluation was planned after 1 month therapy. CMR results after 1 month of therapy showed no myocardial edema, with less fibrotic tissue. These results will lead to good prognosis as shown in Figure 4.

In conclusion, CMR is a non-invasive diagnostic tool, which is essential for diagnosing myocarditis in pediatric patients who came with clinical presentation of chest pain. CMR revealed tissue edema on T2W and fibrosis on LGE, which confirmed the diagnosis of myocarditis.

## REFERENCES

- Skouri HN, Dec GW, Friedrich MG, Cooper LT. Noninvasive imaging in myocarditis. *J Am Coll Cardiol.* 2006;48(10):2085-93.
- Feldman AM, McNamara D. Myocarditis. *N Engl J Med.* 2000;343(19):1388-98.
- Magnani JW, Dec GW. Myocarditis: current trends in diagnosis and treatment. *Circulation* 2006;113(6):876-90.
- Fabre A, Sheppard MN. Sudden adult death syndrome and other non-ischaemic causes of sudden cardiac death. *Heart.* 2006;92(3):316-20.
- Kawai C. From myocarditis to cardiomyopathy: mechanisms of inflammation and cell death: learning from the past for the future. *Circulation.* 1999;99(8):1091-100.
- Freimuth P, Philipson L, Carson SD. The coxsackievirus and adenovirus receptor. *Curr Top Microbiol Immunol.* 2008;323:67-87.
- Shi Y, Chen C, Lisewski U, Wrackmeyer U, Radke M, Westermann D, et al. Cardiac deletion of the Coxsackievirus-adenovirus receptor abolishes Coxsackievirus B3 infection and prevents myocarditis in vivo. *J Am Coll Cardiol.* 2009;53(14):1219-26.
- Liu PP, Mason JW. Advances in the understanding of myocarditis. *Circulation.* 2001;104(9):1076-82.
- Liu PP, Yan AT. Cardiovascular magnetic resonance for the diagnosis of acute myocarditis prospects for detecting myocardial inflammation. *J Am Coll Cardiol.* 2005;45(11):1823-5.
- Friedrich MG, Sechtem U, Schulz-Menger J, Holmvang G, Alakija P, Cooper LT, et al. Cardiovascular magnetic resonance in myocarditis: A JACC White Paper. *J Am Coll Cardiol.* 2009;53(17):1475-87.
- Zagrosek A, Abdel-Aty H, Boyé P, Wassmuth R, Messroghli D, Utz W, et al. Cardiac magnetic resonance monitors reversible and irreversible myocardial injury in myocarditis. *JACC Cardiovasc Imaging.* 2009;2(2):131-8.
- Morgera T, Di Lenarda A, Dreas L, Pinamonti B, Humar F, Bussani R, et al. Electrocardiography of myocarditis revisited: clinical and prognostic significance of electrocardiographic changes. *Am Heart J.* 1992;124(2):455-67.
- Towbin JA, Bricker JT, Garson A Jr. Electrocardiographic criteria for diagnosis of acute myocardial infarction in childhood. *Am J Cardiol.* 1992;69(19):1545-8.
- Spodick DH. Electrocardiogram in acute pericarditis. Distributions of morphologic and axial changes by stages. *Am J Cardiol.* 1974;33(4):470-4.
- Gazit AZ, Avari JN, Balzer DT, Rhee EK. Electrocardiographic diagnosis of myocardial ischemia in children: is a diagnostic electrocardiogram always diagnostic? *Pediatrics.* 2007;120(2):440-4.
- Lauer B, Niederau C, Kühl U, Schannwell M, Pauschinger M, Strauer BE, et al. Cardiac troponin T in patients with clinically suspected myocarditis. *J Am Coll Cardiol.* 1997;30(5):1354-9.
- Caforio AL, Calabrese F, Angelini A, Tona F, Vinci A, Bottaro S, et al. A prospective study of biopsy-proven myocarditis: prognostic relevance of clinical and aetiopathogenetic features at diagnosis. *Eur Heart J.* 2007;28(11):1326-33.
- Cooper LT, Baughman KL, Feldman AM, Frustaci A, Jessup M, Kuhl U, Levine GN, Narula J, Starling RC, Towbin J, Virmani R; American Heart Association; American College of Cardiology; European Society of Cardiology; Heart Failure Society of America; Heart Failure Association of the European Society of Cardiology. The role of endomyocardial biopsy in the management of cardiovascular disease: a scientific statement from the American Heart Association, the American College of Cardiology, and the European Society of Cardiology. Endorsed by the Heart Failure Society of America and the Heart Failure Association of the European Society of Cardiology. *J Am Coll Cardiol.* 2007;50(19):1914-31.

19. Shanes JG, Ghali J, Billingham ME, Ferrans VJ, Fenoglio JJ, Edwards WD, et al. Interobserver variability in the pathologic interpretation of endomyocardial biopsy results. *Circulation*. 1987;75(2):401-5.
20. Gagliardi MG, Bevilacqua M, DiRenzi P, Picardo S, Passariello R, Marcelletti C. Usefulness of magnetic resonance imaging for diagnosis of acute myocarditis in infants and children, and comparison with endomyocardial biopsy. *Am J Cardiol*. 1991;68(10):1089-91.
21. Gagliardi MG, Polletta B, Di Renzi P. MRI for the diagnosis and follow-up of myocarditis. *Circulation*. 1999;99(3):458-9.
22. Assomull RG, Lyne JC, Keenan N, Gulati A, Bunce NH, Davies SW, et al. The role of cardiovascular magnetic resonance in patients presenting with chest pain, raised troponin, and unobstructed coronary arteries. *Eur Heart J*. 2007;28(10):1242-9.
23. Laissy JP, Garot J. Non-invasive imaging of myocardial infarction and myocarditis by cardiac magnetic resonance and multi-slice computed tomography. *European Cardiology Review*. 2006;2(2):40-4.
24. Friedrich MG, Strohm O, Schulz-Menger J, Marciniak H, Luft FC, Dietz R. Contrast media-enhanced magnetic resonance imaging visualizes myocardial changes in the course of viral myocarditis. *Circulation*. 1998;97(18):1802-9.
25. Roditi GH, Hartnell GG, Cohen MC. MRI changes in myocarditis - evaluation with spin echo, cine MR angiography and contrast enhanced spin echo imaging. *Clin Radiol*. 2000;55(10):752-8.
26. Olimulder MA, van Es J, Galjee MA. The importance of cardiac MRI as a diagnostic tool in viral myocarditis-induced cardiomyopathy. *Neth Heart J*. 2009;17(12):481-6.
27. McCrohon JA1, Moon JC, Prasad SK, McKenna WJ, Lorenz CH, Coats AJ, et al. Differentiation of heart failure related to dilated cardiomyopathy and coronary artery disease using gadolinium-enhanced cardiovascular magnetic resonance. *Circulation*. 2003;108(1):54-9.
28. Hunold P, Schlosser T, Vogt FM, Eggebrecht H, Schmermund A, Bruder O, et al. Myocardial late enhancement in contrast-enhanced cardiac MRI: Distinction between infarction scar and non-infarction-related disease. *AJR Am J Roentgenol*. 2005;184(5):1420-6.
29. Uchida Y, Nakamura F, Hirose J, Oshima T, Morita T, Morizuki S, et al. Cardioscopic spectrum of the left ventricular endocardial surface and its relation to histologic changes in idiopathic myocarditis. *Am Heart J*. 1996;131(1):107-14.
30. Gutberlet M, Spors B, Thoma T, Bertram H, Denecke T, Felix R, et al. Suspected chronic myocarditis at cardiac MR: diagnostic accuracy and association with immunohistologically detected inflammation and viral persistence. *Radiology*. 2008;246(2):401-9.
31. Dennert R, Crijns HJ, Heymans S. Acute viral myocarditis. *Eur Heart J*. 2008;29(17):2073-82.
32. Vignaux O, Dhote R, Duboc D, Blanche P, Dusser D, Weber S, et al. Clinical significance of myocardial magnetic resonance abnormalities in patients with sarcoidosis: a 1-year follow-up study. *Chest*. 2002;122(6):1895-901.