

Left Atrial Myxoma with Mitral Regurgitation

Amiliana M. Soesanto, Hamed Oemar, Omar Fauzi

Abstrak

Tumor primer jantung amat jarang terjadi. Dari semua tumor jantung, tumor miksoma merupakan jenis yang paling banyak dijumpai. Diagnosis cukup sulit ditegakkan mengingat gejala dan tanda klinis dari miksoma ini tidak spesifik, bahkan dapat menyerupai penampakan klinis penyakit jantung lain yang lebih umum dijumpai. Pada kasus yang jarang, klinis miksoma atrium kiri dapat disertai keadaan insufisiensi mitral seperti yang dilaporkan pada laporan ini. Kecurigaan terhadap adanya miksoma merupakan faktor penting agar diagnosis miksoma tidak terlupakan. Saat ini pemeriksaan ekokardiografi mempunyai kontribusi yang besar karena kemampuannya memberikan keakuratan diagnosis miksoma atrium kiri. Dilaporkan seorang wanita 43 tahun dengan keluhan sesak napas dan batuk-batuk yang berlangsung sejak setahun yang lalu. Dari ekokardiografi dua dimensi tampak pembesaran atrium kiri dengan massa yang bergerak dan menempel melalui tangkai yang pendek ke septum interatrium. Setelah operasi ditemukan tumor yang besar memenuhi sebagian besar ruang atrium kiri. Pemeriksaan histopatologi menyimpulkan bahwa penampakannya sesuai dengan miksoma.

Abstract

Primary tumors of the heart are very rare; among these, myxomas of the left atrium (LA) are the most common one. The clinical diagnosis is difficult since myxoma causes non-specific signs and symptoms, and its clinical manifestations often mimic other common cardiac diseases. Rarely, LA myxoma coincides with or even manifests as mitral regurgitation. Nevertheless, a high index of suspicion remains the most important element in diagnosing myxoma. The advantage in echocardiography modality has contributed an easy, simple, and accurate diagnosis of LA myxoma. A 43-year-old woman complained of breathlessness and cough lasting for one year. Echocardiography showed a large LA consisting of a mobile mass with short pedicle attached to the interatrial septum. The mass moved throughout a cardiac cycle. On operation, a large tumor occupying most part of the left atrial cavity was found. The tumor was completely removed and the pathological examination concluded the tumor as a myxoma.

Keywords : Myxoma, Mitral Regurgitation, Echocardiography.

INTRODUCTION

Left atrial myxomas are uncommon and present with non-specific clinical cardiac symptoms and signs. Therefore, a correct diagnosis is essential to reduce the mortality and morbidity from serious complications.¹ In most cases, this condition has been incorrectly diagnosed as other common cardiac diseases. However, nowadays, with the advances of noninvasive technique like ultrasonography, an accurate, cost effective, and safe diagnostic procedure has been provided.²

The clinical and hemodynamic features of left atrial myxoma usually mimic those of mitral stenosis,³ but it has been reported that a few cases also coincide with mitral regurgitation.⁴ This paper illustrates the features

of left atrial myxoma with mitral regurgitation manifestation, which was detected by cardiac Doppler and echocardiography.

CASE REPORT

A 43-year-old woman was admitted to the Emergency Unit of the National Cardiac Center 'Harapan Kita' on January 31, 1997, with the complaints of breathlessness and cough. For one year she had been suffering from exercise intolerance which developed gradually and progressively until one month prior to hospitalization. There were also dyspnea on effort, orthopnea, and unproductive cough which was more intense in upright position. Additional complaints were nausea, vomiting, general fatigue, anorexia, and intermittent low grade fever. She lost her weight about 13 kg within one year. History of fainting, convulsion, or neurological disorders was denied. She also denied any history of rheumatic fever.

Department of Cardiology, Faculty of Medicine, University of Indonesia/National Cardiac Center Harapan Kita, Jakarta, Indonesia

Physical examination on admission revealed an alert, pale, and thin woman. Circumoral cyanosis was observed. The blood pressure was 130/80 mmHg, pulse rate was 100 beats/minute, regular, respiratory rate was 30 /minute, regular. There was no fever. There was elevation of jugular venous pressure. The point of maximal impulse was located just 2 cm lateral to the left midclavicular line at the fourth intercostal space. A heaving on left sternal border at the 4th intercostal space was observed. On auscultation, the first heart sound was accentuated at the apex, but neither gallop, opening snap, nor tumor plop sound was audible. There were a grade 3/6 apical holosystolic murmur which radiated to the left mid-axillary line and a grade 2/6 apical mid-diastolic murmur. These murmurs varied with the change of position, the systolic murmur was more accentuated in an upright than in supine position. Fine rales were heard on the lower part of the lungs. The liver was enlarged 3 cm below right costal margin. The spleen and kidneys were not palpable, and there was no pretibial edema or neurological abnormality.

Laboratory examination showed increased erythrocyte sedimentation rate, positive C-reactive protein, raised ASTO, and a slight increase of globulin. Other laboratory findings were within normal limits. The electrocardiogram showed sinus rhythm, 100 beat/minute, right QRS axis deviation with left atrial enlargement (Figure 1). The chest X-ray revealed cardiomegaly with CTR 65%, left atrial enlargement, and significant pulmonary venous congestion (Figure 2).

The two dimensional echocardiography showed left atrial (LA) enlargement, which consisted of a large echo mass inside the atrial chamber. The mass was attached to the interatrial septum, with a short pedicle and was mobile throughout the cardiac cycle (Figure 3). It moved toward mitral annulus during diastole and moved back to the left atrium during systole. Color Doppler revealed a moderate mitral regurgitation and a moderate tricuspid regurgitation. It was diagnosed as a solid and large myxoma in the LA cavity with grade III mitral regurgitation.

Surgery was urgently performed by median sternotomy, right atriotomy, and inter-atrial septostomy to approach the tumor under cardiopulmonary by-pass. A marked enlargement of the left atrium with a large tumor occupying the LA chamber was observed during surgery. The tumor had a short pedicle which was attached to the interatrial septum adjacent to the limbus fossa ovalis. Attempt was made to completely remove the tumor, but unfortunately it was not 'in

toto'. The mitral and the tricuspid valves were not repaired, because it was considered that there were no significant regurgitation of both valves after tumor removal.

The tumor weighed 73.8 grams and measured about 8 x 6 x 4 cm. It had a rather smooth surface, yellowish white in color, with firmly elastic consistency (Figure 4). Microscopically it was observed that the tumor cells were round, polygonal and clustered, which were surrounded by myxoid and hyaline materials. Scattered foci of calcification were noted. This histological appearance was consistent with the diagnosis of myxoma (Figure 5).

Three days after the surgery, echocardiography was revealed a residual mild mitral regurgitation and a mild tricuspid regurgitation, with normal left ventricular contractility. The size of the LA cavity was reduced to almost normal. Five days after surgery, the patient was discharged without any complaint.

DISCUSSION

The incidence of primary tumor of the heart is about 0.0017%-0.028%;⁵ with 30%-50% of those are myxomas. The mean age of patients with sporadic myxoma is 56 years, and 70% are females.⁵ Approximately 86% of myxomas occur in the left atrium, and over 90% are solitary,⁵ and usually attached to the interatrial septum near the fossa ovalis.⁶

The clinical manifestations of left atrial myxoma are the results of obstructive or / and embolization factors. They also cause constitutional symptoms⁷⁻⁹ such as anemia, fever, and loss of weight. Increased erythrocyte sedimentation rate, high gamma-globulinemia,^{2,8-10} and increased level of C-reactive protein have been reported.^{4,11} Some of these constitutional symptoms were observed in our patient.

Emboli can arise from tumor fragmentation or detachment of the entire tumor, or from thrombi.¹¹ Obstruction caused by cardiac myxoma is progressive and intermittent;⁸ this intermittent obstruction causes syncope or sudden death in less than 25% of patients with left atrial myxoma.⁸ Fortunately our patient has no embolic manifestation. Nevertheless, this condition is considered as urgency; surgical removal is indicated whenever a diagnosis of left atrial myxoma is made.¹¹

Although the majority of symptoms of left atrial myxoma are nonspecific, it is common for the

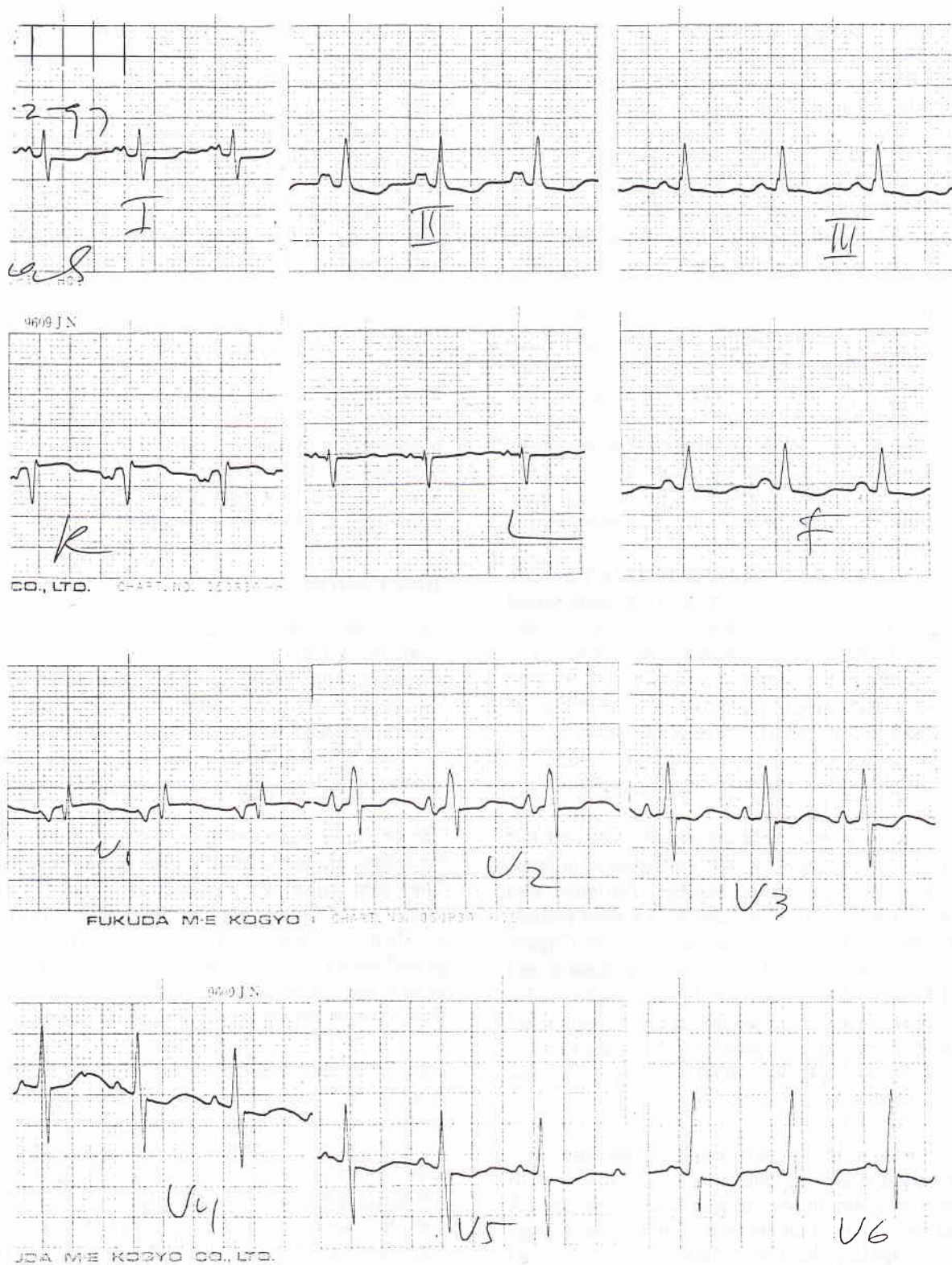


Figure 1. The electrocardiogram showed sinus rhythm, right axis deviation, and left atrial enlargement.

Figure 2. The Chest X-ray revealed cardiomegaly, a prominent of left atrial segment, and sign of venous congestion.

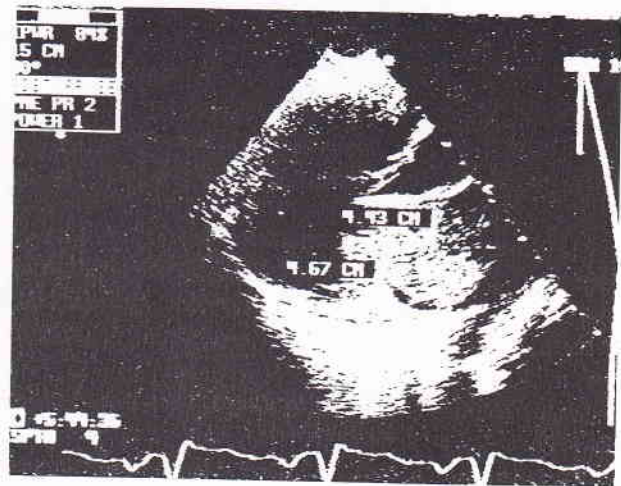
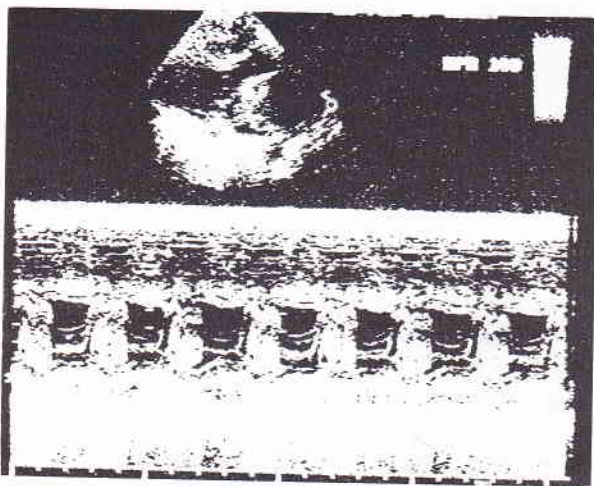
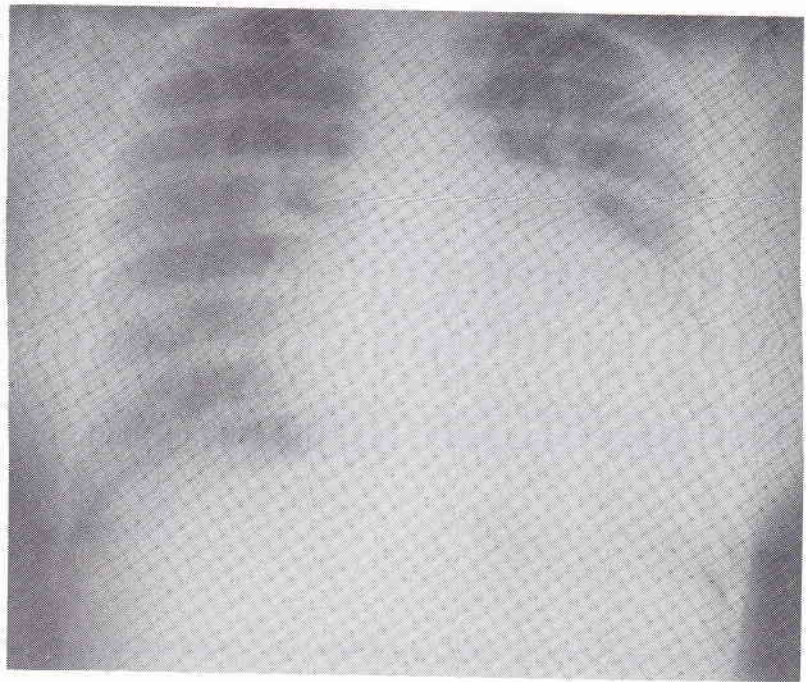


Figure 3. M mode echocardiogram demonstrated an echo dense mass just behind the anterior leaflet of mitral valve (right). On parasternal long axis view of two-D echocardiography a huge echo dense mass occupying almost most part of LA was observed. The mass prolapsed into the atrioventricular annulus during diastole (left).

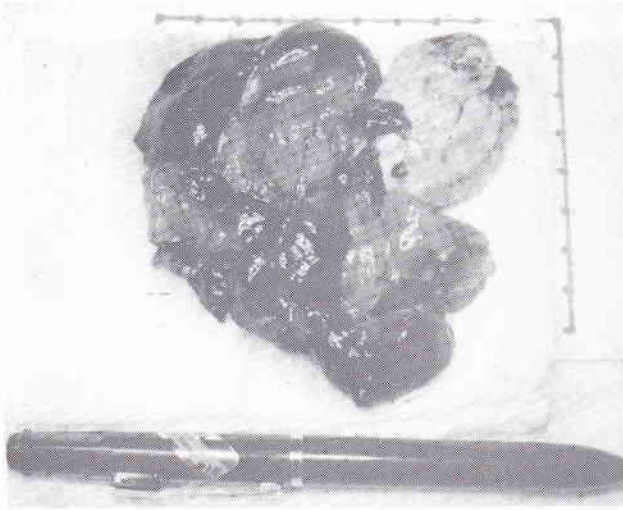


Figure 4. Gross specimen of the large tumor excised from the left atrium (left), and during the tumor removal (right)

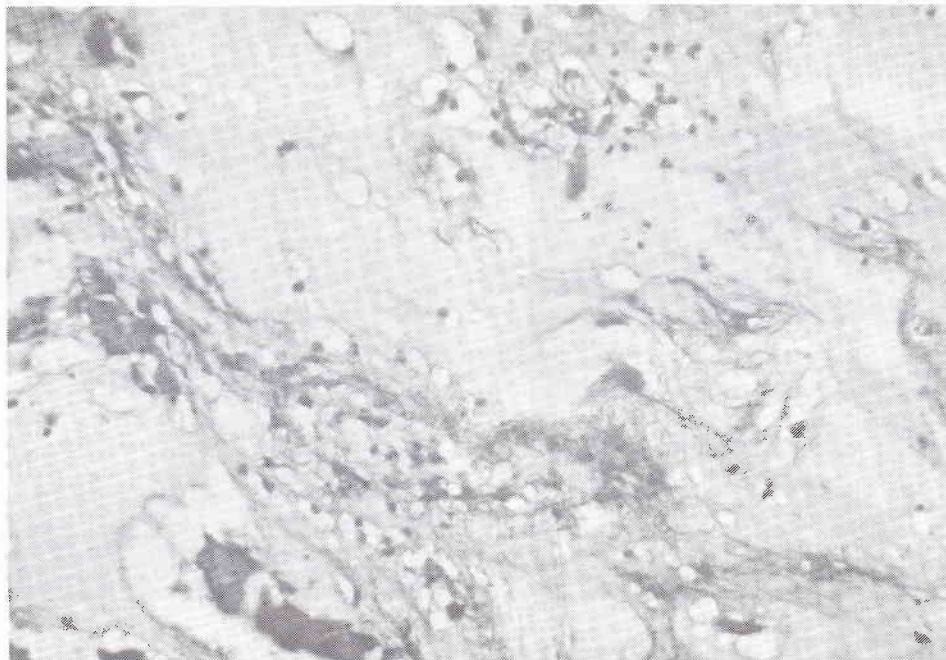


Figure 5. Photomicrograph shows the typical pattern of myxoma (hematoxylin and eosin staining).

symptom to be sudden, intermittent, and related to body position.^{8,10} In our case almost all signs and symptoms mentioned above occurred. Based on those findings and the absence of history of rheumatic fever the diagnosis of LA myxoma should have been considered.

The accentuated first heart sound heard in this patient might be due to the late onset of mitral valve closure resulting from tumor prolapse through the mitral valve orifice, as reported by Greshlick et al.¹² Mobile and pedunculated left atrial myxoma may prolapse into the mitral valve orifice, resulting in obstruction to atrioventricular blood flow and mitral regurgitation. A possible explanation for the occurrence of mitral regurgitation is the uncoaptation state of the mitral leaflets caused by the large solid tumor stretching the mitral annulus.⁴ Accentuation of the systolic murmur in an upright position, as found in our patient, might be due to the downward shift of the tumor which caused more dilatation to the mitral annulus and augmentation of the regurgitant flow.⁴ This was proved during the operation that after tumor removal, there was no significant mitral regurgitation. In this case, it appears that congestive heart failure might have been caused not only by mitral obstruction but also by mitral regurgitation.

Presently two dimensional echocardiography is considered to be the most appropriate screening and diagnostic imaging modality for most cardiac tumors, particularly myxomas.¹¹ With this technique, mitral stenosis can be excluded, and tumor prolapse through the atrioventricular valve may be demonstrated. Tumor prolapse in our case can be accurately demonstrated by echocardiography; the tumor was located behind the anterior mitral leaflet and it moved into the left ventricle during diastole.¹³

Acknowledgments

The authors wish to thank Dr. M. Yusak for giving us permission to illustrate his patient, and Dr. I. Made Nassar for helping us to illustrate the histopathological features.

REFERENCE

1. Nasser WK, Davis RH, Dill JC, Tavel ME, Helman CH, Feigenbaum H, Fisch C. Atrial myxoma and pathologic features in 9 cases. *Am Heart J* 1972; 83:694-703.
2. Sutton MJ, Marcier LA, Giuliani ER, Lie JT. Atrial myxoma, a review of clinical experience in 40 patients. *Mayo Clin Proc* 1980;55:371-6.
3. Bulkley BH, Hutchins GM : Atrial myxomas, a fifty year review. *Am Heart J* 1979; 97:639- 43.
4. Oemar H, Masaoka T, Kanazawa I, Yuasa A, Eno S, Tsuchioka Y, et al. A case of giant left atrial myxoma combined with mitral regurgitation. *Hiroshima J Med Sci* 1982; 31:165-73 .
5. Colucci WS, Braunwald E. Primary tumors of the heart. In: Braunwald E, ed. *Heart disease*. Philadelphia: Saunders,1992; 1451-62.
6. Kabban SS, Cooley DA. Atrial myxoma, surgical consideration. *J Thorac Cardiovasc Surg* 1973 ; 65:731-6.
7. Goodwin JF. Diagnosis of left atrial myxoma. *Lancet* 1963; 1:464-7.
8. Greenwood WF. Profiles of atrial myxoma. *Am J Cardiol* 1968; 21:367-75.
9. Goodwin JF. The spectrum of cardiac tumors . *Am J Cardiol* 1968; 21:307-13.
10. Harvey W. Clinical aspects of cardiac tumors . *Am J Cardiol* 1968; 21:328- 43.
11. Kirklin JW, Barratt-Boyes BG. Cardiac tumors. In: Kirklin JW, Barratt-Boyes BG, eds. *Cardiac surgery*. New York : Churchill Livingstone, 1993; 1636-42.
12. Greshlick AH, Leech G, Mills PG, Leatham A. The loud first heart sound in left atrial myxoma. *Br Heart J* 1984; 52:403.
13. Bass NM, Sharratt GP. Left atrial myxoma diagnosed by echocardiography, with observation on tumor movement. *Br Heart J* 1973; 35:1332-6.