

## Exploring the Aetiology of Increased Endometrial Bleeding in Norplant Users : the Role of Local Factors ?

Biran Affandi,\* Wachyu Hadisaputra,\* Peter A.W. Rogers†

### Abstrak

Telah dilakukan studi klinik untuk mengetahui penyebab perdarahan endometrium abnormal pada akseptor Norplant, dengan perhatian khusus pada faktor lokal endometrium. Tidak tampak hubungan yang jelas antara gambaran histologi endometrium dengan pola perdarahan. Kemungkinan besar perdarahan yang timbul disebabkan oleh sel-sel yang sensitif terhadap hormon steroid pada endometrium yang mengalami regresi menembus miometrium sehingga berpengaruh pada fungsi dan integritas vaskuler di miometrium. Disimpulkan dari studi klinis ini bahwa terdapat peningkatan densitas mikro vaskuler dalam endometrium akseptor Norplant dibandingkan dengan endometrium kontrol. Selain itu, level FVIIIa endotel endometrium pada akseptor Norplant menunjukkan peningkatan dibandingkan dengan endometrium kontrol saat menstruasi, dan penyebarannya tidak merata.

### Abstract

The clinical study of endometrium has been conducted to investigate the aetiology of increased endometrial bleeding in Norplant user with the emphasis on the role of local factors. There was no obvious correlation between endometrial histology and bleeding pattern. It is certainly possible that the bleeding occurred due to the steroid-sensitive cells from the regressing endometrium coming through the myometrium to influence its vascular function and integrity. In conclusion, this study provides evidence for increased microvascular density in endometrium from Norplant acceptors compared to normal menstrual cycle endometrium. In addition, endometrial endothelial levels of FVIIIa in Norplant users are elevated above those seen in the control at the time of menstruation and unequally distributed within the endometrial microvasculature.

**Keywords :** CD 34 antibody, FVIIIa, hysteroscopy.

Norplant is the only implantable contraceptive system available in the market. One set of Norplant implants consists of six capsules made of the elastomer, polydimethylsiloxane, filled with 36 mg levonorgestrel each. After insertion of the Norplant implants, levonorgestrel is slowly released through the polydimethylsiloxane tubing, at a rate of 85 micrograms per day at first. Within about one and a half year the concentration of the progestin in the plasma stabilises at an average level of 30 mcg per day giving a plasma concentration of 0.30 nanograms per milliliter. This corresponds to the level reached 12 hours after the intake of a levonorgestrel containing "minipill". The plasma level of hormone sufficient to prevent conception, is reached within 24 hours and is

maintained for five years. The plasma level drops rapidly after implants removal and return to normal level of fertility follows.<sup>1,2,3</sup> Levonorgestrel is a progestin widely used in combined oral contraceptives and in the so called "minipills". When administered alone, at a dose of 0.30 mcg/day, levonorgestrel protects against pregnancy through at least two mechanisms :

- Ovulation inhibition, which occurs in a substantial proportion of cycles
- Thickening of the cervical mucus, inhibiting sperm penetration into the uterus.
- Other mechanism that may contribute include effects on the endometrium reducing the likelihood of implantation and depressed progesterone support during the luteal phase.

\* Department of Obstetrics and Gynecology, Faculty of Medicine, University of Indonesia, Dr. Cipto Mangunkusumo Hospital, Jakarta, Indonesia

† Department of Obstetrics and Gynecology, Faculty of Medicine, Monash University, Melbourne, Australia

Until March 1994, out of 33,550,674 eligible couples in Indonesia, 22,547,849 were using some kind of contraceptive method, and 1,461,200 (6,5%) were using Norplant (Table 1).

Table 1. Contraceptive use in Indonesia (March 1994)

Method	Users	%
Pill	8,072,500	35.8
Injectable	6,283,728	27.8
IUD	5,135,681	22.8
Implantable	1,461,200	6.5
Sterilization	1,211,045	5.4
Others	383,695	1.7
<b>Total</b>	<b>22,547,849</b>	<b>100.0</b>

As with other progestin only contraceptives, the main side effects of Norplant is the bleeding problems. Although the majority of bleeding problems experienced by Norplant users tend to be light and do not seriously affect the physical health of the users, they do cause anxiety and discomfort to the users. Irregular menstrual bleeding is the most common side effect.

About 60% of Norplant users notice changes in their menstrual patterns in the first year after insertion. Most common are an increase in the number of days of bleeding and/or spotting per cycle and a decrease in the length of the menstrual cycle.

An extensive WHO study has demonstrated that, irrespective of socio-cultural background, most women wish to have a regular and unchanged pattern of vaginal bleeding while using a contraceptive. This study has also demonstrated that women's perceptions of their menstrual bleeding patterns vary considerably with socio-cultural background.<sup>4</sup>

In one study, 26% of the women terminated contraceptive method use for menstrual problems during the first year and an additional 6% during the second year, whereas there were no terminations for menstrual problems during the third year of use. The bleeding pattern in many users of Norplant is characterized by frequent, irregular and/or prolonged bleeding, particularly during the first 12 months of use.

The impact that these bleeding problems can have on user acceptance rates has provided and increased impetus for research into the local mechanisms underlying contraceptive-hormone-induced endometrial bleeding.

Therefore, since 1990 University of Indonesia, Jakarta, in collaboration with Monash University, Melbourne, Australia have been conducting this study.

The objective of this study is to quantify differences between natural menstrual cycle and Norplant acceptors with increased and normal bleeding patterns in: histopathology and immunohistochemistry.

## METHOD

### Subject recruitment and collection of endometrial biopsies

Subjects were recruited to the trial on the basis of fully informed consent from women presenting to the Raden Saleh Clinic in Jakarta for Norplant insertion. Institutional and World Health Organization ethical approval were obtained for these studies. Following Norplant insertion, subjects were asked to record "bleeding", "spotting", or "no bleeding" on a daily menstrual record card. Subjects were requested to return to the clinic for an endometrial biopsy once they had collected a minimum of 90 days of menstrual record data and no later than 12 months after Norplant insertion. Six peripheral blood samples were taken at two-to three-day intervals in the two weeks prior to endometrial biopsy, for estradiol (E2), progesterone (P4), LNG, and sex hormone binding globulin (SHBG) evaluation. Directed endometrial biopsies were collected using a microhysteroscope, and where possible, tissue was collected from bleeding and nonbleeding sites. Biopsies were placed immediately in 10% buffered formalin at 4°C for 4-6 hr, before being rinsed and stored in buffer at 4°C prior to shipment to Monash University in Australia.

### Analysis of menstrual record card data

Menstrual record card data were analyzed using the current World Health Organization terminology and definitions. These are as follows :

- Bleeding. Any bloody vaginal discharge that is sufficient to require protection.
- Spotting. Any bloody vaginal discharge that is not sufficient to require protection.
- Bleeding/spotting episode. One or more consecutive days during which blood loss (bleeding or spotting) has been entered on the calendar record, each episode being bounded by two or more bleeding/spotting-free days. A single bleeding/spotting-free day within a bleeding/spotting episode is counted as part of the episode surrounding it.
- Bleeding/spotting-free interval. Two or more consecutive days during which blood loss (bleeding or spotting) has not been entered on the calendar

record, each interval being bounded by bleeding/spotting days.

- Reference period. The period of time (length of diary) measured in number of days on which analysis is to be based, in this study 90 days.

#### **Bleeding patterns during the 90-day reference period**

- Prolonged bleeding. One or more bleeding/spotting episode lasting 10 days or more.
- Frequent bleeding. More than four bleeding/spotting episodes within the reference period.
- Infrequent bleeding. Less than two bleeding/spotting episodes within the reference period.
- Irregular bleeding. Range of lengths of bleeding/spotting-free intervals greater than 17 days during the reference period.
- Amenorrhea. No bleeding/spotting days during the reference period.
- Normal pattern. Two to four bleeding/spotting episodes per reference period. No bleeding/spotting episode lasting 10 days or more. Range of lengths of bleeding/spotting-free intervals of 17 days or less.

#### **Biopsy processing, histopathology and immunohistochemistry**

Endometrial tissue was processed by routine paraffin embedding, and 5-unsections were cut for either immunohistochemistry or routine hematoxylin and eosin staining for histopathological evaluation by an experienced gynecological pathologist. Two primary antibodies were used in this study: a rabbit polyclonal antihuman factor VIII associated protein (FVIII<sub>Ra</sub>),<sup>5</sup> and a monoclonal anti-CD34. Primary antibody binding was visualized using a streptavidin-biotin horse radish peroxidase immunohistological staining kit. Prior to the primary antibody incubation, endogenous peroxidase activity in the endometrial tissue was blocked by treating with 3% H<sub>2</sub>O<sub>2</sub> (BDH Chemicals, Australia) for 10 min. at room temperature. The primary antibodies, FVIII<sub>Ra</sub> was incubated for 45 min at 37<sup>o</sup> C at a 1:400 dilution, and CD34 for 45 min at 37<sup>o</sup> C at a 1:25 dilution. Ten percent fetal calf serum was added to both primary antibodies to prevent non-specific binding. Sections were mounted in Hydromount (National Diagnostics) without counterstaining to avoid interference during color image analysis. For negative controls, the primary antibody was either

replaced by normal serum used at the same dilution or the diluent alone was used (10% FCS in phosphate buffered saline). In each staining run, a control section of known immunohistochemical staining intensity was included as a positive control and to ensure consistency between runs.

Immunohistochemical staining for FVIII<sub>Ra</sub> was scored subjectively on a semiquantitative scale of 0 to 4 (0=no staining, 1=weak staining, 2=moderate staining, 3=strong staining, 4=intense staining), as well as quantitatively using a chromatic colour image analysis system (Leading Edge, Adelaide, South Australia). This methodology has been described elsewhere.<sup>6</sup> Microvascular profiles recognized by CD34 staining were also counted using the chromatic colour image analysis system and microvascular density was calculated for each biopsy.

## **RESULTS**

### **Histopathology and bleeding record analysis**

To date, histopathology reports have been generated for 66 Norplant biopsies and 65 menstrual record cards have been analyzed. As assessed by histopathology, 7 biopsies were inadequate for diagnosis, 20 were myometrium or myometrium and basal layer only, 9 were atrophic endometrium, 11 showed iatrogenic progestogenic effects, 4 were proliferative, 4 were secretory, 10 showed evidence of shedding, and 1 had atypical glandular development. By menstrual record card analysis, 6 subjects had normal bleeding patterns, 15 were amenorrheic, 4 were infrequent, 28 irregular, 30 prolonged, and 6 frequent bleeders (65 subjects gave 89 bleeding pattern classifications since in many cases one record card fit into two or more bleeding categories).

### **FVIII<sub>Ra</sub> and CD34 immunohistochemical staining results**

CD34 antibody produced positive staining for the endothelial lining of all blood vessels in all biopsies collected for this study. Figure 1 shows relative microvascular density for groups of control endometrial biopsies collected at different stages of the normal menstrual cycle. Figure 2 shows Norplant endometrium microvascular density correlated against endometrial histopathology, and Figure 3 shows Norplant endometrium microvascular density correlated against endometrial bleeding patterns.

Control endometrial microvascular (FVIIIa) staining intensity results during the normal menstrual cycle have been published elsewhere. An earlier study showed that FVIIIa staining intensity was significantly reduced in late secretory and menstrual biopsies.<sup>6</sup> Figure 4 shows Norplant endometrium FVIIIa staining intensity correlated against endometrial histopathology, and Figure 5 shows Norplant endometrium FVIIIa staining intensity correlated against endometrial bleeding pattern.

## DISCUSSION

The results from this on going histological and immunohistochemical study confirm a number of existing observations about progesterone-influenced endometrium and provide some new insights into local relation of its microvasculature. Based on over 60 Norplant acceptors in this study, it seemed that there was no correlation between endometrial histology and bleeding patterns during the preceding 90 days. It is also of interest to note that 27 out of 66 attempted endometrial biopsies were either myometrium only or inadequate for diagnosis, and that a further 9 were classified as atrophic. Thus, in 54% of Norplant acceptors the endometrial lining could be classified as being very "regressed". Despite this, the majority of these 54% were classified as either prolonged, frequent, or irregular bleeders. In view of this finding, it may be worth including the endometrial-myometrial vascular plexus and the superficial aspect of the myometrium as potential candidates for sources of progesterone "endometrial bleeding". It is certainly possible that steroid-sensitive cells from the regressing endometrium come close enough to the myometrium to influence its vascular function and integrity.

The CD34 antibody immunohistochemistry described in this study produced a completely new and relatively unexpected finding. As shown in Figure 2 and 3, there was no obvious correlation between capillary density and either histopathology or bleeding pattern in Norplant users. Equally, there was no obvious difference in endometrial vascular density across the different stages of the menstrual cycle in a control group of subjects (Fig.1). The major difference came when Norplant endometrium was compared to control endometrium. The results show that when all groups are combined, Norplant endometrium has 162% of the vascular density of control endometrium. The finding that endometrial vascular density increases during regression has been reported previously for the rat following ovariectomy.<sup>7</sup> These results suggest that the

local mechanisms involved in the involution of the nonvascular endometrial compartments are different from those controlling the vasculature. Whether the increased vascularity seen in Norplant endometrium is related to its increased susceptibility to bleeding problems requires further investigation.

CD34 antigen immunohistochemistry of Norplant endometrial microvasculature also provided the opportunity to look for previously reported subepithelial dilated venules.<sup>8</sup> Although a number of vessels that could be described as dilated subepithelial venules were identified in Norplant endometrium, it was not at all clear from an initial examination of Norplant and control menstrual cycle tissues whether or not any difference existed between the two in this respect. Unfortunately this issue may not be easy to resolve since the endometrial vasculature collapses at the time of biopsy, making objective measurements of vessel diameters impossible.

The FVIIIa immunohistochemistry provides two interesting new findings, despite the fact that there is no obvious correlation between FVIIIa staining intensity and either histopathology or bleeding patterns (Figs. 4 and 5). The first important observation is that FVIIIa staining intensity in all groups of Norplant endometrium, including that classified as shedding, is considerably higher than the staining seen during the late secretory and menstrual stages of the control endometrium.<sup>6</sup> From this we may conclude that the "programmed" drop in FVIIIa levels that normally occurs at the time of menstruation is not happening in Norplant exposed endometrium, even when it is described as shedding or menstrual by histopathology. This suggests that the local processes controlling endometrial endothelial cell function in Norplant patients are altered from those in women without an equivalent progesterone influence. The second important point to arise from the FVIIIa results is the observation that the positive staining was unequally distributed and a substantial percentage of the endometrial microvessels do not contain any FVIIIa. This heterogeneity in endometrial microvascular staining for FVIIIa is not related to any particular segment of the vascular tree, with arterioles, capillaries, and venules all showing both positive and negative staining. This variability in microvascular staining response for FVIIIa was not seen with CD34 antigen staining. This evidence for endothelial cell heterogeneity in the endometrial microvasculature is something that requires future investigations.

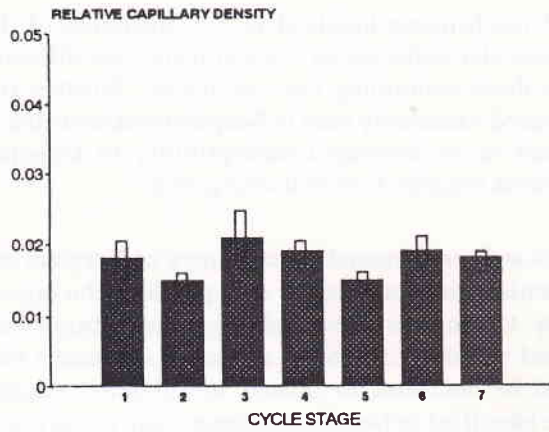


Figure 1. Relative microvascular density of normal endometrial biopsies at different stages

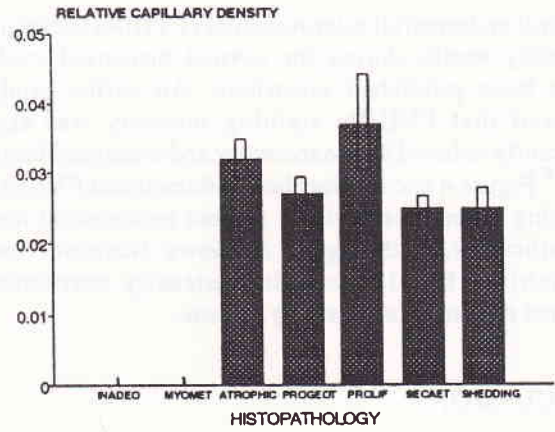


Figure 2. Norplant endometrium microvascular density correlated against endometrial histopathology

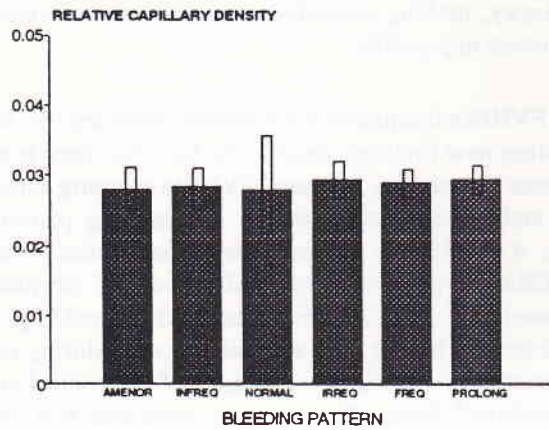


Figure 3. Norplant endometrium microvascular density correlated against endometrial bleeding patterns

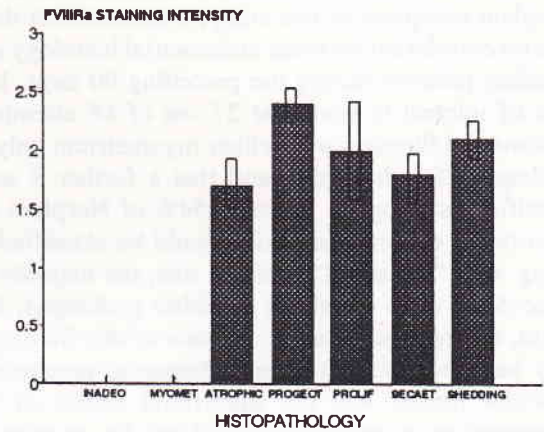


Figure 4. Norplant endometrium FVIIIa staining intensity correlated against endometrial histopathology

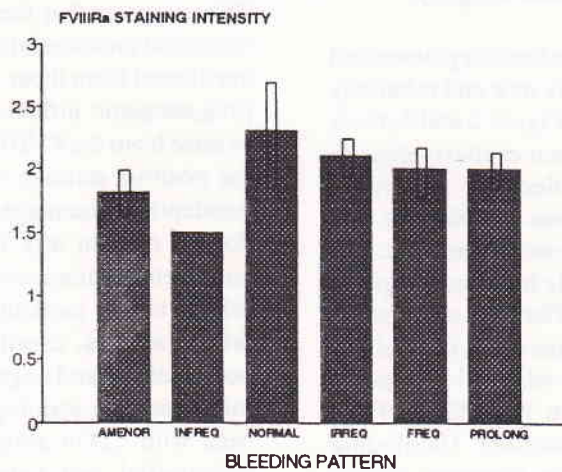


Figure 5. Norplant endometrium FVIIIa staining intensity correlated against endometrial bleeding pattern

## CONCLUSION

This study provides for the first time the evidence of a relative increase in microvascular density in the endometrium of Norplant acceptors compared to control menstrual cycle endometrium. In addition, endometrial endothelial levels of FVIIIa in Norplant users are both elevated above those seen in the control menstrual cycle at the time of menstruation and unequally distributed within the endometrial microvasculature.

## ACKNOWLEDGEMENTS

This work was supported by the World Health Organization project grant no. 90901 through the WHO Special Programme of Research, Development and Research Training in Human Reproduction. Thank are due to Dr. Julianto Witjaksono, Dr. Beatrice Susil for histopathological assessment of endometrial sections, Dra. Rusminah for patient coordination, and Dra Ida Iriani, Mrs Yudiati, and Linda Beaton for expert technical assistance.

## REFERENCES

1. Affandi B, Santoso SSI, Djajadilaga. Five year-experience with Norplant. *Contraception* 1987; 36:417-28.
2. Affandi B, Cekan SZ, Boonkasemsanti W. The interaction between sex hormone binding globulin and levonorgestrel released from Norplant, an implantable contraceptive. *Contraception* 1987; 35:135-45.
3. Affandi B. Clinical, pharmacological and epidemiological studies on a levonorgestrel implant contraceptive [dissertation]. Jakarta: University of Indonesia, 1987.
4. Odlind V, Fraser IS. Contraception and menstrual bleeding disturbances: A clinical overview. In: d'Arcangues C, Fraser IS, Newton JR, Odlind V, editors. *Contraception and mechanisms of endometrial bleeding*. Cambridge: Cambridge University Press, 1990:5-32.
5. Wagner DD. Cell biology of von Willbrand factor. *Ann Rev Cell Biol* 1990; 6:217-46.
6. Rogers PAW, Au CL, Affandi B. Endometrial microvascular density during the normal menstrual cycle and following exposure to long-term levonorgestrel. *Human Reproduction* 1993; 8:1396-404.
7. Rogers PAW, Maopherson AM. In-vivo microscopy of the rat endometrial subepithelial capillary plexus during the oestrus cycle and after ovariectomy. *J Reprod Fertil* 1990; 90:137-45.
8. Hourihan HM, Sheppard BL, Bonnar J. The morphological response of blood vessels of the endometrium to low dose oral norethisterone and levonorgestrel. *J Obstet Gynecol* 1991; 11:47-54.