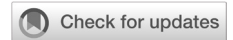

Safety of augmentation cystoplasty in patients with bladder abnormalities undergoing renal transplantation: a systematic review

Bobby Sutojo, Gampo Alam Irdam



pISSN: 0853-1773 • eISSN: 2252-8083
<https://doi.org/10.13181/mji.oa.204358>
Med J Indones. 2021;30:198–206

Received: November 22, 2019

Accepted: September 02, 2020

Authors' affiliations:

Department of Urology, Faculty of
Medicine, Universitas Indonesia, Cipto
Mangunkusumo Hospital, Jakarta,
Indonesia

Corresponding author:

Gampo Alam Irdam
Department of Urology, Faculty of
Medicine, Universitas Indonesia,
Cipto Mangunkusumo Hospital, Jalan
Diponegoro No. 71, Kenari, Senen,
Central Jakarta 10430, DKI Jakarta,
Indonesia

Tel/Fax: +62-21-3923632

E-mail: gampoai@gmail.com

ABSTRACT

BACKGROUND Augmentation cystoplasty (AC) has been recently proposed to improve a bladder condition before or after a renal transplantation for an optimal allograft function. Until now, AC in adults with end-stage renal disease (ESRD) is uncommon and rarely practiced. This study aimed to investigate the safety of AC in patients with bladder abnormalities who required renal transplantation.

METHODS Studies of patients with ESRD and abnormal bladder who underwent AC were searched in ProQuest, PubMed, EBSCO, and Cochrane Library online databases. Only studies published in English from January 1985 to May 2020 were included. The keywords used were renal transplantation, bladder dysfunction, cystoplasty, and their synonyms. Data were extracted by two independent authors who selected, screened, and assessed the articles' eligibility and quality. The outcomes were graft survival rate and complications of AC.

RESULTS A total of 19 articles were included. AC improved an intravesical pressure, a bladder capacity, and a compliance in patients with ESRD and bladder abnormalities, allowing patients to undergo the renal transplantation. Even though AC in patients with renal transplantation resulted in a significantly higher urinary tract infection rate than patients who underwent renal transplantation only, performing AC after renal transplantation was considered safe.

CONCLUSIONS AC was considered safe for patients with bladder abnormalities who underwent renal transplantation.

KEYWORDS cystoplasty, efficacy, renal transplantation, safety

The normal bladder function is important for patients with an end-stage renal disease (ESRD) who had a renal transplantation. Any bladder abnormalities (e.g., a high intravesical pressure, a low bladder capacity, and a reduced bladder compliance) may impair the transplanted kidney functions similar to the impairment seen in the native kidney. Although anticholinergic drugs and a clean intermittent catheterization (CIC) may improve a bladder function

before a transplantation, bladder abnormalities can still affect the optimal allograft function in renal transplantation.^{1,2}

Recent evidence had confirmed a successful renal transplantation in patients with an augmentation cystoplasty (AC). AC was performed before or after a transplantation to ensure better an allograft function and reduce the risk of complications. However, the safety of AC in patients with ESRD is still under debate,

especially on renal graft.¹This systematic review aimed to analyze the safety of AC on graft survival and complications in patients with bladder abnormalities who underwent a renal transplantation.

METHODS

Literature search

This systematic review was reported according to the Preferred Reporting Items for Systematic Reviews and Meta-Analyses guidelines. Studies were restricted to patients with bladder abnormalities who required renal transplantation and underwent AC. The main outcomes were the comparison of graft survival rate and urinary tract infection (UTI) complications between patients with and without AC. A literature search was conducted using ProQuest, PubMed, EBSCO, and Cochrane Library online databases for articles published from January 1985 to May 2020. The keywords were renal transplantation, bladder dysfunction, cystoplasty, and their synonyms, as shown in Table 1. Only articles published in English were retrieved for this systematic review.

Article selection

Two independent authors (GAI and BS) screened the titles and abstracts. Inclusion criteria were randomized control trials, case-control studies, and

Table 1. Keywords for literature search in online databases

Databases	Keywords
ProQuest	("renal" OR "kidney") AND ("transplant" OR "transplantation") AND bladder AND ("abnormality" OR "abnormalities" OR "dysfunction") AND ("cystoplasty" OR "bladder augmentation" OR "augmented bladder")
PubMed	(((((("renal" OR "kidney"))) AND ("transplant" OR "transplantation"))) AND bladder) AND ("abnormality" OR "abnormalities" OR "dysfunction")) AND ("cystoplasty" OR "bladder augmentation" OR "augmented bladder")
EBSCO	(renal or kidney) AND (transplant or transplantation) AND bladder AND (abnormality or abnormalities or dysfunction) AND (cystoplasty or bladder augmentation or augmented bladder)
Cochrane	"renal" or "kidney" in All Text AND "transplantation" or "transplant" in All Text AND bladder in All Text AND "cystoplasty" or "bladder augmentation" or "augmented bladder" in All Text

case reports that described the outcomes of graft survival and complications in patients with bladder abnormalities who underwent AC before or after renal transplantation. Exclusion criteria were non-full-text, proceedings, or conference articles; articles with data duplication; and articles focused on variable types of bladder reconstruction (not specific to AC) and undetailed data of AC. The full-texts of the remaining articles were then screened.

Data extraction

The study's design, level of quality, type of cystoplasty, subjects with related treatment groups, graft survival rate, rejection to transplantation, and complications of all available articles were documented. The data were presented in tables. The main results were graft survival rate and complications of AC, which represented the efficacy and safety of AC on renal transplantation in patients with bladder abnormalities who developed ESRD.

Assessment of methodological quality

The methodological quality (risk of bias) were evaluated using the elements of Cochrane adopted from the Grading of Recommendation, Assessment, Development, and Evaluation (GRADE).³ The domains implemented in this systematic review were randomization and allocation (selection bias), blinding (performance and detection bias), loss to follow-up, keeping to the intention-to-treat principle (attrition bias), and selective reporting (reporting bias).

RESULTS

Evidence of synthesis

Of 458 articles, only 444 articles published in English were included for further analysis. Subsequently, 50 remaining articles were screened for full-text availability. Thirty-one articles were excluded due to full-text unavailability and the irrelevant outcomes and indicator to our study. Thus, only 19 articles were included (Figure 1).

Quality of studies

Table 2 and Figure 2 summarized the quality of studies in accordance with the GRADE based on Cochrane.³ Due to a poor study design and a small number of participants, all studies were in level III dan IV quality of evidence. Retrospective data and

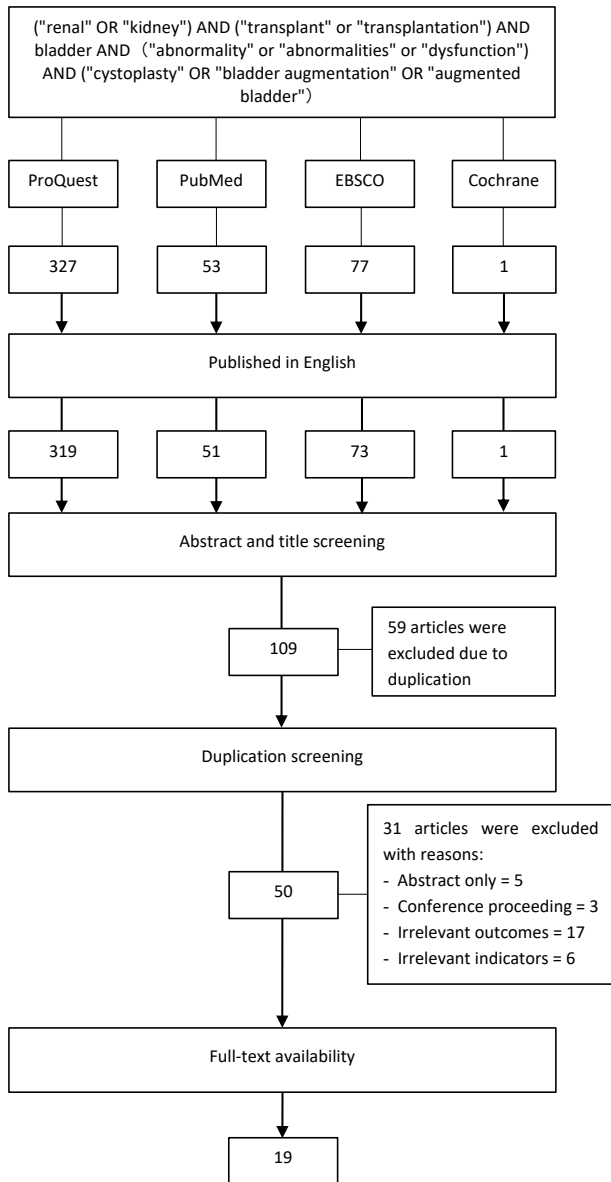


Figure 1. Article selection process

case-control studies included were the weakness of this study.^{1,2,4-20}

AC type and interval studies

All incorporated studies were selected to determine the safety and efficacy of AC before and after renal transplantation. AC was conducted in 218 subjects, with the majority (180 subjects, 82.6%) performed before a renal transplantation. Most ACs were derived from the entero-segments, such as the ileal, ileocecal, gastric, colon, and sigmoid segments. Only 21 (13.46%) AC were derived from the ureter.^{1,2,4-20} The interval between AC and renal transplantation in this systematic review varied, starting at 2 months.^{7,8,13,14} The AC’s timing and type are shown in Table 2.

Characteristics of the studies

Most studies were conducted in a pediatric male population. AC was mainly performed on the posterior urethral valve (84 subjects), followed by neurogenic bladder abnormalities (50 subjects), and a vesicoureteral reflux (VUR) (20 subjects). Inclusion and exclusion criteria, including the number of subjects, are shown in Table 2.

Graft characteristics of studies

The graft survival rates were comparable between patients with and without AC in both long- and short-term periods. There was no significant difference in a graft survival rate related to AC’s timing before or after a renal transplantation. The graft survival rate and transplant rejection of each study are shown in Table 2.

Complications of AC

The UTI rate was significantly higher in patients with a renal transplantation who underwent AC than in their counterparts. Other complications, including an ureteral stenosis, a bladder rupture, an urolithiasis, a malignancy, and a metabolic disorder, might occur while performing AC (Table 2).

DISCUSSION

Patients with bladder abnormalities who had developed ESRD and underwent AC may have an improved intravesical pressure, bladder capacity and compliance.^{6,15,16} Most studies showed a comparable graft survival rate between patients with and without AC in both short- and long-term periods. However, Basiri et al⁴ showed a significantly higher graft survival rate in patients without AC than with AC. These findings suggest that neither AC nor the timing of cystoplasty had a significant effect on the transplantation outcome. The lower graft survival rate in AC patients is due to the high acute rejection rate, which might not be related to the AC procedure.

Further discussion on the timing of AC should be conducted for a graft survival. Yamazaki et al¹⁴ recommended performing AC 2 months before renal transplantation, while Nahas et al¹³ recommended at 8–12 weeks before a renal transplantation or an immunosuppression treatment. Performing AC earlier also prevented the possible complications, such as infection risk, and delayed wound healing due to immunosuppressive effects after renal

Table 2. Study characteristics

First author, year	Study design	Cystoplasty type	Inclusion and exclusion criteria	Subjects (n)	Graft survival rate (AC/no AC)	Rejection (AC/no AC)	Complications		
							UTI (AC/no AC)	Others	
Basiri, ⁴ 2008	Case-control	Gastrocystoplasty, ileocystoplasty, colcystoplasty	Children <18 years with a renal failure due to a high-pressure neurogenic bladder	89	1 st year: 85–90%/88% 3 rd year: 69–72%/80% 5 th year: 46–60%/76% 7 th year: 40–43%/70%	Acute rejection: 40%/33% Chronic rejection: 50%/29%	AC: Anastomotic leak: 2.2% Vesicoureteric junction stenosis: 2.2% Delayed pouch rupture: 4.5%	27%/2%	
Pereira, ⁵ 2013	Case-control	Ileocystoplasty, ileocecocystoplasty, sigmoidcystoplasty, ureterocystoplasty	Children <18 years who received a renal transplant in 1985–2012	44	1 st year: 100%/100% 5 th year: 100%/90.5% 10 th year: 88.9%/84.8%	N/A	AC: VUR: 15.9% No AC: VUR: 11.4% Ureteral stenosis: 4.5%	31.8%/18.2%	
Rigamonti, ¹² 2005	Retrospective cohort	Gastrocystoplasty, ileocystoplasty, colocecalcystoplasty, sigmoidcystoplasty, ureterocystoplasty	Subject with AC who received a renal transplant in September 1987–January 2005	16	1 st year: 94.1%/100% 5 th year: 80.7%/83.3% 10 th year: 80.7%/55.5% 15 th year: 80.7%/55.5%	Acute rejection: N/A Chronic rejection: 12.5%/12.5%	AC: Severe chronic hematuria-dysuria syndrome: 6.25% Urinary fistula caused by ureteral stenosis: 6.25% Ureteral obstruction: 6.25% Vesicolithiasis: 12.5% Upper urinary tract lithiasis: 12.5%	12.5%/12.5%	
Taghizadeh, ⁹ 2007	Retrospective cohort	N/A	Subject who had AC and received a renal transplant in August 1990–March 2005	16	1 st year: 93.8%/- 2 nd year: 88.9%/- 10 th year: 66.7%/-	Acute rejection: 12.5%/- Chronic rejection: N/A	AC: Metabolic alkalosis: 6.25% Ureteral stricture: 18.75%	6.25%/18.75%	
Traxel, ¹ 2011	Retrospective cohort	Gastrocystoplasty, colcystoplasty	Subject who received a renal transplant in 1989–2007	34	1 st year: 100%/94% 3 rd year: 86%/94% 5 th year: 85%/82% 10 th year: 78%/67%	Acute rejection: -5.9% Chronic rejection: 11.8%/-		14.7%/14.7%	N/A
Thomalla, ¹⁶ 1989	Case series	Ileocystoplasty, ileocecocystoplasty, sigmoidcystoplasty	Subject who had AC and received a renal transplant in 1974–October 1987	8	80%/-	Acute rejection: 12.5%/- Chronic rejection: 25%/-	AC: Wound infection: 12.5% Cystostomy leakage: 12.5% Renal artery stenosis: 12.5%	100%/-	
Zaragoza, ⁶ 1993	Case series	Ileocystoplasty, ileocecocystoplasty, sigmoidcystoplasty	Subject who had AC and received a renal transplant in January 1983–June 1992	11	85%/-	Acute rejection: 9.1%/- Chronic rejection: 9.1%/-	AC: Metabolic acidosis: 9.1%	27.3%/-	

Table continued on next page

Table 2. (continued)

First author, year	Study design	Cystoplasty type	Inclusion and exclusion criteria	Subjects (n)	Graft survival rate (AC/no AC)	Rejection (AC/no AC)	Complications	
							UTI (AC/no AC)	Others
Fontaine, ² 1998	Case series	Gastrocystoplasty, ileocystoplasty, sigmoidcystoplasty	Subject who had AC and received a renal transplant in 1972–1996	14	5 th year: 84%/- 10 th year: 73%/-	Acute rejection: N/A Chronic rejection: 28.6%/-	28.6%/-	AC: Metabolic acidosis: 14.3% Nephrolithiasis: 14.3% Hematuria-dysuria syndrome: 7.14%
Yamazaki, ¹⁴ 1998	Case series	Ileocystoplasty, ureterocystoplasty	Subject who had AC and received a renal transplant in 1971–1996	4	100%/-	Acute rejection: 25%/- Chronic rejection: N/A	75%/-	N/A
Power, ¹⁰ 2000	Case series	Ileocystoplasty, ureterocystoplasty	Subject who had AC and received a renal transplant in December 1991–February 1999	10	90%/-	Acute rejection: N/A Chronic rejection: 10%/-	40%/-	N/A
Martín, ¹⁷ 2001	Case series	Ileoceco-cystoplasty	Subject who had AC and received a renal transplant in 1981–1999	7	100%/-	N/A	57.1%/-	AC: VUR: 14.3% Nephrolithiasis: 14.3% Metabolic acidosis: 14.3% Venous thrombosis: 14.3% Urinary fistula: 14.3%
Nahas, ¹³ 2002	Case series	Ileocystoplasty, ileoceco-cystoplasty, sigmoidcystoplasty	Subject who had AC and received a renal transplant in 1987–April 2001	24	1 st year: 96%/- 2 nd year: 92%/- 5 th year: 78%/-	N/A	56%/-	AC: Malignancy: 4% Ureteral stenosis 8% Lymphocele: 4%
Aki, ¹⁵ 2006	Case series	Gastrocystoplasty, ileocystoplasty	Subject who had AC before receiving a renal transplant in 2006	3	N/A	N/A	66.7%/-	N/A
Dinçkan, ¹¹ 2007	Case series	Ileocystoplasty	Subject who had AC and received a renal transplant simultaneously	3	100%/-	Acute rejection: 0%/- Chronic rejection: 0%/-	100%/-	N/A
Blanco, ⁷ 2009	Case series	Ileocystoplasty, sigmoidcystoplasty	Subject who had AC before receiving a renal transplant in 1976–2008	6	50%/-	Acute rejection: 0%/- Chronic rejection: 0%/-	100%/-	N/A

Table continued on next page

Table 2. (continued)

First author, year	Study design	Cystoplasty type	Inclusion and exclusion criteria	Subjects (n)	Graft survival rate (AC/no AC)	Rejection (AC/ no AC)	Complications	
							UTI (AC/no AC)	Others
Garat, ⁸ 2009	Case series	Ileocystoplasty, colocystoplasty	Subject who had AC before receiving a renal transplant in 1993–2003	6	83%/-	Acute rejection: 16.7%/- Chronic rejection: 16.7%/-	N/A	AC: Ureterocutaneous fistula: 16.7% Vesicolithiasis: 16.7% Pyonephrosis: 16.7% Metabolic acidosis: 33.3%
Tan, ¹⁸ 2018	Case series	Gastrocystoplasty, enterocystoplasty	Subject who had AC and received a renal transplant in 2001–2005	7	100%/-	Acute rejection: 14.2%/- Chronic rejection: N/A	42.8%/-	N/A
Selli, ¹⁹ 1997	Case report	Ileocystoplasty	Subject who had AC and received a renal transplant	1	100%/-	Acute rejection: 0%/- Chronic rejection: 0%/-	N/A	AC: Scant ejaculation: 100%
Farouk, ²⁰ 2007	Case report	Ileocystoplasty	Subject who had AC and received a renal transplant	1	100%	Acute rejection: 0%/- Chronic rejection: 0%/-	100%/-	AC: Urinary incontinence: 100%

AC=augmentation cystoplasty; N/A=not applicable; UTI=urinary tract infection; VUR=vesicoureteral reflux

transplantation.¹⁶ However, Yamazaki et al¹⁴ showed no complications in patients who received immunosuppressive therapy and underwent AC 7 years after transplantation. Performing AC after a transplantation may avoid the rare complication of pyocystis due to a dry cystoplasty or underfilled bladder. In addition, Basiri et al⁴ recommended performing AC at 3–6 months after a renal transplantation. Although performing AC to improve a bladder function before a transplantation is suggested, other studies reported different results. Capozza et al²¹ reported five patients with an oliguria who received a renal transplantation without AC and found an adequate bladder emptying without catheterization. Thus, they recommended to re-evaluate the need for AC after a renal transplantation because it might be unnecessary. Therefore, further evaluation of the patient's diuresis status including a careful anamnesis, a physical examination, and other additional modalities is needed to elucidate this issue.

AC in patients with a renal transplantation resulted in a significantly higher UTI rate. Pereira et al⁵ and Basiri et al⁴ found significantly higher UTI rates in the AC group than the non-AC group. No significant difference was found for the UTI cases in subjects who received transplantation after or before AC.^{4,5} Although CIC was effective for bladder emptying post-transplantation, this method could increase the UTI risks.^{2,22} Patients with an urinary reflux post-transplantation are also at high risk for UTI, which is also increased by an immunosuppressive therapy. UTIs may cause catastrophic complications, including an urosepsis, a graft loss, and a death.^{6,23} In this systematic review, some UTI cases required a hospitalization and an intravenous antibiotics treatment either with or without an increase in serum creatinine levels. The serum creatinine levels decreased to normal after the UTIs were resolved. Surgical repair may be needed in patients who develop recurrent UTIs due to underlying abnormalities, such as VURs or fistulas.^{13,15,24} Taghizadeh et al⁹ showed two graft failures due to recurrent UTIs. Thus, a regular follow-up for the risk of UTI after renal transplantation should be considered in patients who had AC.

The occurrence of ureteral stenosis must be assessed after a renal transplantation as it may affect a graft survival. Three studies described an ureteral stenosis in five subjects: two in the non-AC group and three in the AC group.^{5,12,13} The ureteral stenosis

occurred at the implant site. This complication can be corrected with an ureteral reimplantation or a percutaneous dilatation. The ureteral stenosis did not affect the graft function if managed correctly and immediately.^{5,25} The ureteral stenosis might frequently occur when the ureteral graft was not implanted in the native bladder.⁵ A delayed management could lead to a graft failure, hydronephrosis, chronic pyelonephritis, VUR, fistula, and post-obstructive renal annulment.²⁶ Both AC and renal transplantation may cause an ureteral stenosis.^{22,27} More studies are required to conclude the possibility of an increased risk for stenosis development caused by AC in renal transplantation.

Some studies have also reported other life-threatening complications, including an ureteral stenosis, rupture, a reflux, a metabolic disorder, and a malignancy. Patients who underwent renal transplantation with AC were at higher risk for surgical re-intervention caused by AC complications.²⁸ Basiri et al⁴ reported a delayed bladder rupture in two subjects who underwent AC after renal transplantation, which is an unusual complication of renal transplantation.^{29,30} In this systematic review, AC was hypothesized to cause a bladder rupture, compared to the transplant procedure. The bladder rupture is a life-threatening urological complication of AC, with a mortality rate of up to 25%. The median interval from AC is 35 months. The most common rupture site is the junction between the bowel and bladder wall. A local ischemia may occur in this area, which causes a subsequent necrosis. Other contributing factors are the bowel segment used, a high bladder pressure, an overdistention, adhesions to the pelvic or abdominal wall, a chronic transmural bladder-bowel wall infection, a bladder neck closure, and a trauma due to a catheterization. Bladder rupture needs laparotomy for exploration and rupture correction.^{29,30}

Urolithiasis is a common AC complication, with an incidence of 40%. The proposed mechanism of stone formation is an excessive mucous production of the gastrointestinal segment. Gastrocystoplasty has a low incidence of urinary lithiasis because of the lower amounts of mucus and lower pH, compared with the intestinal segment.^{29,30} Kispal et al³¹ showed a higher stone formation in colcystoplasty than in gastrocystoplasty and ileocystoplasty. The colon segment has a high capability to retain mucus and remarkable bacterial colonization, which contributes

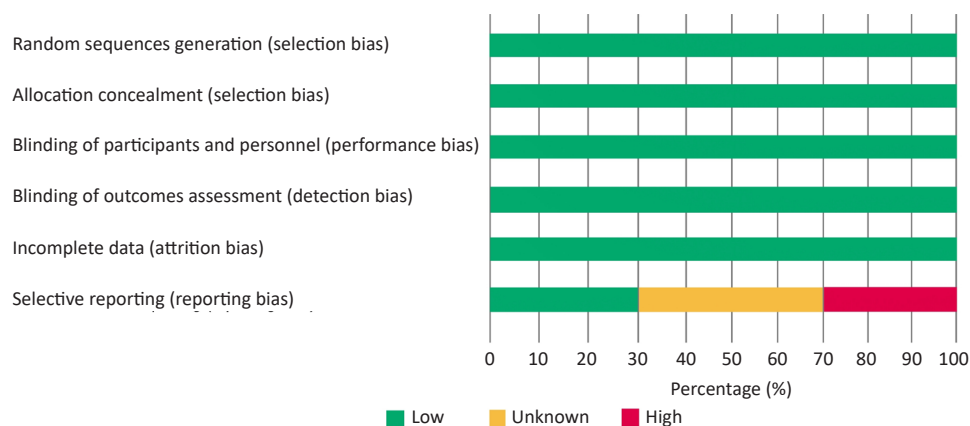


Figure 2. Risk of bias assessment

to a stone formation.³¹ Four studies reported eight urolithiasis complications, with one case was not related to AC. Four urolithiasis complications were found in the upper urinary tract, while three were found in the bladder.^{2,8,12,17} Martín et al¹⁷ reported a small incidence of urolithiasis that resolved spontaneously. Other studies managed urolithiasis with extracorporeal shock wave, pyelotomy, and percutaneous nephrolithotomy. Fontaine et al² reported struvite-type urolithiasis,^{8,13,17} which was related to the infection condition.

AC has also been identified to cause a bladder malignancy post-transplantation, which developed 3–15 years after underwent AC.¹⁸ One study reported a death case due to adenocarcinoma at the vesicointestinal anatomic site.¹³ A malignancy in AC is related to an immunosuppressive therapy, a tobacco exposure, and other carcinogenic factors.³²

AC may result in metabolic disorders. Gastrocystoplasty improves an electrolyte imbalance, thereby reducing a metabolic acidosis and the need for dialysis. Hyperchloremia is the most common electrolyte imbalance in patients requiring AC, particularly in those who undergo an enterocystoplasty. Nevertheless, a gastrocystoplasty may be harmful to patients with anuria, as acid accumulation may lead to cystitis, urethritis, ulceration, and perforation.¹⁹ Three studies reported the occurrence of hematuria-dysuria syndrome due to gastrocystoplasty, and one study showed a successful management via periodic bladder irrigation and histamine receptor blockade.^{2,12} A hydrogen-potassium adenosine triphosphatase blockade can also be used as an alternative.³³

Enterocystoplasty is also correlated with an abnormal calcium balance, a demineralization of bone, and a growth retardation in children.³³ Therefore,

a gastrointestinal segment may not produce the best outcome for cystoplasty. Conversely, an ureterocystoplasty may yield a better outcome than a cystoplasty. Mahdavi Zafarghandi et al³⁴ showed no significant difference in the occurrence of UTI and the graft and patient survival rates between ureterocystoplasty and the normal bladder. Ureterocystoplasty should be the preferred operation over enterocystoplasty and gastrocystoplasty, unless the ureter is unavailable, nondilated, or manipulated previously.³⁵ However, enterocystoplasty and gastrocystoplasty have become the alternatives due to the difficulty in finding a dilated ureter in many patients.

The limitation of this study is the lack of data to strengthen the overall risks and benefits of AC due to a low-quality evidence. High-quality and larger studies are required to determine whether AC is needed. Moreover, most studies used secondary data from the medical records of subjects who met the criteria within a defined period, which were not feasible for randomized selection, concealment, and blinding. The follow-up duration provided a sufficient evaluation time for the long-term effects of the treatment.

In conclusion, AC is a safe method in renal transplantation for renal graft survival. However, in both short- and long-term periods, patients who had AC with a relatively high rate of UTI should be evaluated regularly.

Conflict of Interest

The authors affirm no conflict of interest in this study.

Acknowledgment

The author would like to thank the staff of the Department of Urology, Cipto Mangunkusumo Hospital for the supervision and training given to the authors.

Funding Sources

This study was supported and funded by International Publication Research Grant Universitas Indonesia. Grant number: NKB-2168/UN2.RST/HKP.05.00/2020.

REFERENCES

- Traxel E, DeFoor W, Minevich E, Reddy P, Alam S, Reeves D, et al. Low incidence of urinary tract infections following renal transplantation in children with bladder augmentation. *J Urol.* 2011;186(2):667–71.
- Fontaine E, Gagnadoux MF, Niaudet P, Broyer M, Beurton D. Renal transplantation in children with augmentation cystoplasty: long-term results. *J Urol.* 1998;159(6):2110–3.
- Higgins JP, Green S, editors. *Cochrane handbook for systematic reviews of interventions.* Chichester: John Wiley & Sons; 2008.
- Basiri A, Otookesh H, Hosseini R, Simforoosh N, Moghaddam H. Kidney transplantation before or after augmentation cystoplasty in children with high-pressure neurogenic bladder. *BJU Int.* 2009;103(1):86–8.
- Pereira PL, Rodríguez RO, Cambor CF, Urrutia MJ, Romera RL, Espinosa L, et al. Renal transplant outcome in children with an augmented bladder. *Front Pediatr.* 2013;1:42.
- Zaragoza MR, Ritchey ML, Bloom DA, McGuire EJ. Enterocystoplasty in renal transplantation candidates: urodynamic evaluation and outcome. *J Urol.* 1993;150(5 Part 1):1463–6.
- Blanco M, Medina J, Pamplona M, Miranda N, Gonzalez E, Aguirre JF, et al. Outcome of renal transplantation in adult patients with augmented bladders. *Transplant Proc.* 2009;41(6):2382–4.
- Garat JM, Caffaratti J, Angerri O, Bujons A, Villavicencio H. Kidney transplants in patients with bladder augmentation: correlation and evolution. *Int Urol Nephrol.* 2009;41:1–5.
- Taghizadeh AK, Desai D, Ledermann SE, Shroff R, Marks SD, Koffman G, et al. Renal transplantation or bladder augmentation first? A comparison of complications and outcomes in children. *BJU Int.* 2007;100(6):1365–70.
- Power RE, O'Malley KJ, Khan MS, Murphy DM, Hickey DP. Renal transplantation in patients with an augmentation cystoplasty. *BJU Int.* 2007 Jun 25;86(1):28–31.
- Dinckan A, Turkyilmaz S, Tekin A, Erdogru T, Kocak H, Mesci A, et al. Simultaneous augmentation ileo-cystoplasty in renal transplantation. *Urology.* 2007;70(6):1211–4.
- Rigamonti W, Capizzi A, Zacchello G, Capizzi V, Zanon GF, Montini G, et al. Kidney transplantation into bladder augmentation or urinary diversion: long-term results. *Transplantation.* 2005;80(10):1435–40.
- Nahas WC, Mazzucchi E, Arap MA, Antonopoulos IM, Neto ED, Ianhez LE, et al. Augmentation cystoplasty in renal transplantation: a good and safe option—experience with 25 cases. *Urology.* 2002;60(5):770–4.
- Yamazaki Y, Tanabe K, Ota T, Ito K, Toma H. Renal transplantation into augmented bladders. *Int J Urol.* 1998;5(5):423–7.
- Aki FT, Besbas N, Ozcan O, Bakkaloglu A, Erkan I, Bakkaloglu M, et al. Renal transplantation in children with augmentation enterocystoplasty. *Transplant Proc.* 2006;38(2):554–5.
- Thomalla JV, Mitchell ME, Leapman SB, Filo RS. Renal transplantation into the reconstructed bladder. *J Urol.* 1989;141(2):265–8.
- Martín MG, Castro SN, Castelo LA, Abal VC, Rodríguez JS, Novo JD. Enterocystoplasty and renal transplantation. *J Urol.* 2001;165(2):393–6.
- Tan LR, Tiong HY. Ureteric implantation into the bowel portion of augmented bladders during kidney transplantation: a review of urological complications and outcomes. *ANZ J Surg.* 2019;89(7–8):930–4.
- Selli C, Doggweikr R, Carmellini M, Boggi U, Mosca F. Renal transplantation following Reduction of ileocecostoplasty performed 9 years earlier for undiversion. *Urol Int.* 1997;59(3):182–5.
- Farouk K, Bano U, Gondal M. Renal transplant in a patient with augmentation cystoplasty. *J Ayub Med Coll Abbottabad.* 2007;19(3):85–8.
- Capozza N, Torino G, Collura G, Battaglia S, Guzzo I, Caione P, et al. Renal transplantation in patients with “valve bladder”: is bladder augmentation necessary? *Transplant Proc.* 2010;42(4):1069–73.
- Barnett M, Bruskewitz R, Glass N, Sollinger H, Uehling D, Belzer FO. Long-term clean intermittent self-catheterization in renal transplant recipients. *J Urol.* 1985;134(4):654–7.
- Benfield MR, McDonald R, Sullivan EK, Stablein DM, Tejani A. The 1997 annual renal transplantation in children report of the North American Pediatric Renal Transplant Cooperative Study (NAPRTCS). *Pediatr Transplant.* 1999;3(2):152–67.
- Nahas WC, Lucon M, Mazzucchi E, Antonopoulos IM, Piovesan AC, Neto ED, et al. Clinical and urodynamic evaluation after uretero cystoplasty and kidney transplantation. *J Urol.* 2004;171(4):1428–31.
- Lojanapiwat B, Mital D, Fallon L, Koolpe H, Raja R, Badosa F, et al. Management of ureteral stenosis after renal transplantation. *J Am Coll Surg.* 1994;179(1):21–4.
- Romero Pérez P, Mira Llinares A. [Renal and ureteral complications of urethral stenosis]. *Actas Urol Esp.* 1995;19(6):432–40. Spanish.
- Daher P, Zeidan S, Riachy E, Iskandarani F. Bladder augmentation and/or continent urinary diversion: 10-year experience. *Eur J Pediatr Surg.* 2007;17(2):119–23.
- Slagt IK, IJzermans JN, Alamyar M, Verhagen PC, Weimar W, Roodnat JJ, et al. Long-term outcome of kidney transplantation in patients with a urinary conduit: a case-control study. *Int Urol Nephrol.* 2013;45(2):405–411
- Husmann DA. Long-term complications following bladder augmentations in patients with spina bifida: bladder calculi, perforation of the augmented bladder and upper tract deterioration. *Transl Androl Urol.* 2016;5(1):3–11.
- Harding C, Veeratterapillay R, Thorpe A. Augmentation cystoplasty: contemporary indications, techniques and complications. *Indian J Urol.* 2013;29(4):322.
- Kispal Z, Balogh D, Erdei O, Kehl D, Juhasz Z, Vastyán AM, et al. Complications after bladder augmentation or substitution in children: a prospective study of 86 patients. *BJU Int.* 2011;108(2):282–9.
- Husmann DA, Rathbun SR. Long-term follow up of enteric bladder augmentations: the risk for malignancy. *J Pediatr Urol.* 2008;4(5):381–5.
- Sheldon CA, Gonzalez R, Burns MW, Gilbert A, Buson H, Mitchell ME. Renal transplantation into the dysfunctional bladder: the role of adjunctive bladder reconstruction. *J Urol.* 1994;152(3):972–5.
- Mahdavi Zafarghandi R, Zeraati A, Tavakoli M, Kalani Moghaddam F, Mahdavi Zafarghandi M. Comparison of enterocystoplasty and ureterocystoplasty before kidney transplantation. *Int J Organ Transplant Med.* 2010;1(4):177–82.
- Nahas WC, Mazzucchi E, Antonopoulos I, Denes FT, David-Neto E, Ianhez LE, et al. End-stage renal disease and bladder dysfunction: algorithm for renal transplantation. *Transplant Proc.* 2001;33(6):2984–5.